

REVIEW[®] of OPTOMETRY

June 15, 2024 • reviewofoptometry.com

Leadership in clinical care

BONUS FEATURE
Myopia Management:
Putting Theory
Into Practice
PAGE 36

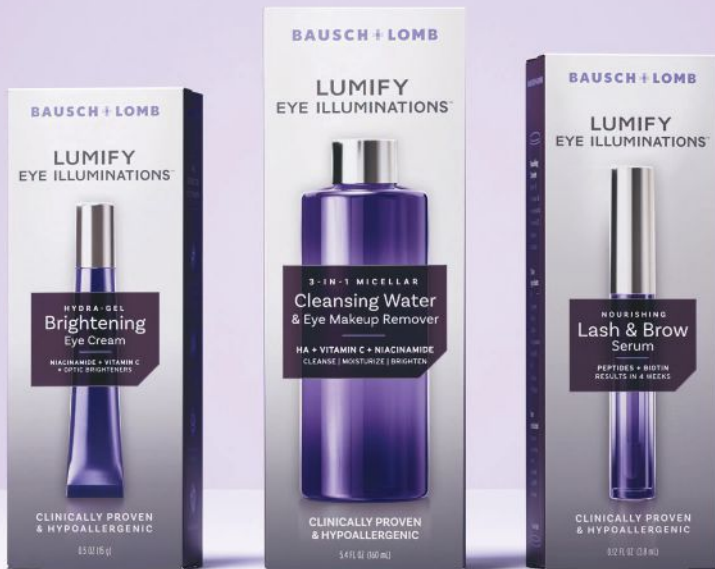15TH ANNUAL RETINA REPORT

Your Role in Stopping the Progression of



FROM THE EYE CARE EXPERTS AT **BAUSCH+LOMB**

LUMIFY EYE ILLUMINATIONS™



Non-irritating formulas | Developed with Eye Doctors and Dermatologists | Clinically-proven

A trio of specialty eye care products scientifically formulated for the sensitive eye area.
Clinically proven with 15,000 product applications up to 12 weeks.

Your patients can find this **in the eye care aisle.**

© 2023 Bausch + Lomb PN11256 LEM.0152.USA.23 **LUMIFYeyes.com**

REVIEW[®] *of* OPTOMETRY

June 15, 2024 • reviewofoptometry.com

Leadership in clinical care

BONUS FEATURE

Myopia Management:
Putting Theory
Into Practice

PAGE 36

15TH ANNUAL RETINA REPORT

Your Role in Stopping the Progression of Diabetic Eye Disease

Learn what to pay attention to and
when to take charge. *PAGE 58*

PLUS:

**AMD Staging: More
Than Wet vs. Dry**

PAGE 50

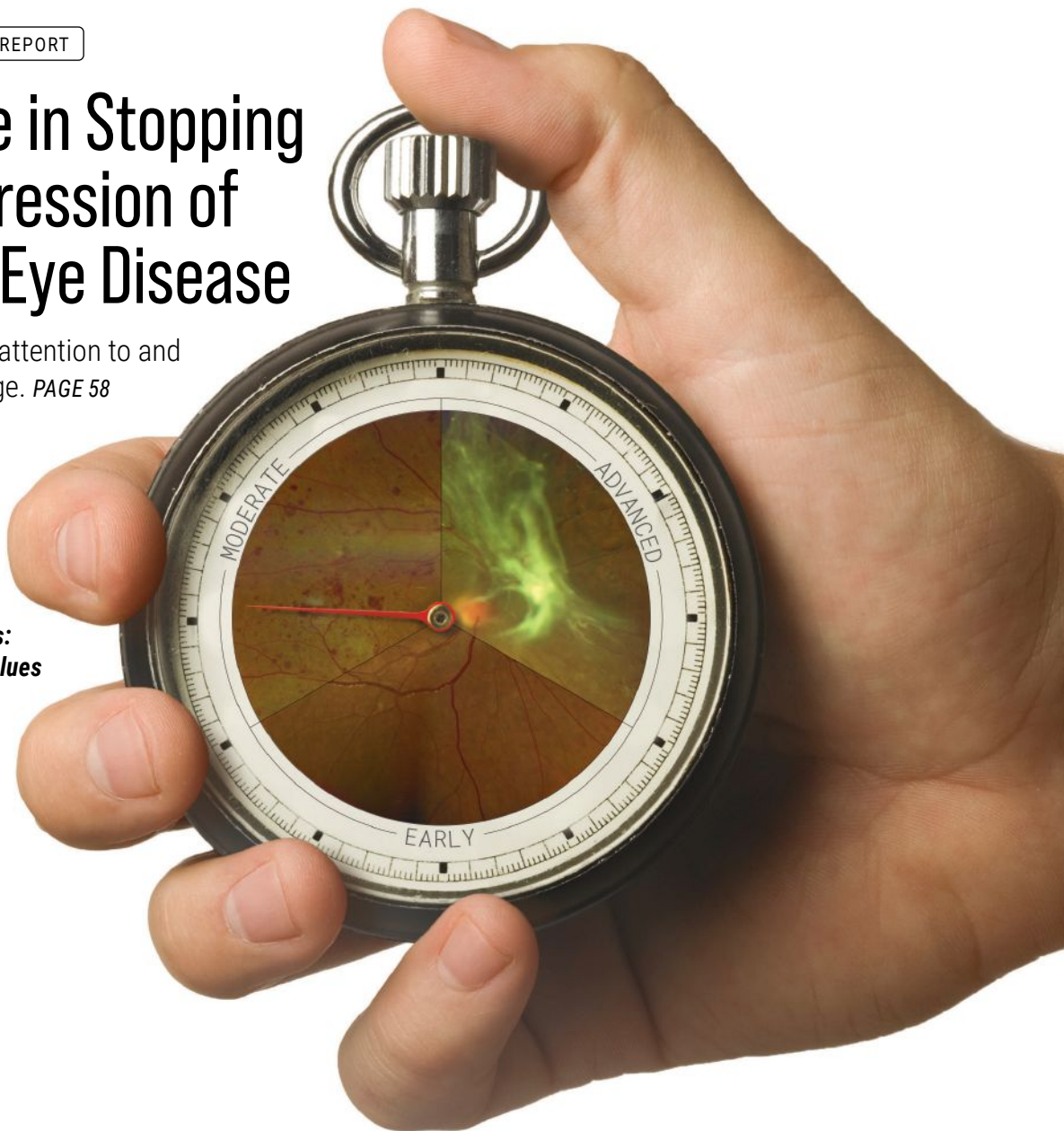
**Understanding Uveitis:
Causes and Clinical Clues**

PAGE 72

EARN 2 CE CREDITS:

**Are You Up to Speed
on Inherited Retinal
Dystrophies?**

PAGE 78



Indicated for the
treatment of the signs
and symptoms of DED

Miebo[™]
(perfluorohexyloctane
ophthalmic solution)

MIEBO is the first and only Rx eye drop for DED that directly targets evaporation¹



Inhibits tear evaporation^{1-3*}

- Forms a monolayer at the air-liquid interface of the tear film which can be expected to reduce evaporation



Rapid and sustained relief[†]

- Improvement in tCFS and eye dryness as early as Day 15 continued through Day 57 in 2 pivotal studies



Excellent tolerability^{1,4-6‡}

- Low rate of burning or stinging on instillation
- Blurred vision and conjunctival redness were reported in 1%-3% of individuals

***The exact mechanism of action for MIEBO in DED is not known.¹**

¹Study design: Two 57-day, multicenter, double-masked, saline-controlled studies (GOBI and MOJAVE) were conducted in adults ≥ 18 years old with a self-reported history of DED in both eyes. Across GOBI and MOJAVE, 614 patients received MIEBO and 603 patients received control with 591 and 575, respectively, assessed on Day 57. **Primary endpoints were change from baseline in tCFS and change from baseline in eye dryness score at Day 57.** Day 15 was the earliest time point at which signs and symptoms were evaluated in the trials. Day 57 was the last.^{1,5,6}

[†]In 2 pivotal studies of >1200 patients (614 patients received MIEBO), there were no incidences of serious ocular AEs with MIEBO. Most AEs were considered mild. The discontinuation rate for MIEBO was comparable to control (pooled: 0.2% vs 0.5%; GOBI: 0.3% vs 1.0%; MOJAVE: 0% vs 0%). 0.5% (pooled) of patients experienced instillation site pain AEs, such as burning or stinging (GOBI: 1.0%; MOJAVE: 0%). Blurred vision (pooled: 2.1%; GOBI: 3.0%; MOJAVE: 1.3%) and conjunctival redness (pooled: 0.8%; GOBI: 0%; MOJAVE: 1.3%) were reported in 1%-3% of individuals.^{1,4-6}

AE, adverse event; DED, dry eye disease; tCFS, total corneal fluorescein staining.

INDICATION

MIEBO[™] (perfluorohexyloctane ophthalmic solution) is a semifluorinated alkane indicated for the treatment of the signs and symptoms of dry eye disease.

IMPORTANT SAFETY INFORMATION

- MIEBO should not be administered while wearing contact lenses. Contact lenses should be removed before use and for at least 30 minutes after administration of MIEBO
- Instruct patients to instill one drop of MIEBO into each eye four times daily
- The safety and efficacy in pediatric patients below the age of 18 have not been established
- The most common ocular adverse reaction was blurred vision (1% to 3% of patients reported blurred vision and conjunctival redness)

You are encouraged to report negative side effects of prescription drugs to the FDA. Visit www.fda.gov/medwatch or call 1-800-FDA-1088.

Please see accompanying Brief Summary of full Prescribing Information for MIEBO.

References: **1.** MIEBO. Prescribing Information. Bausch & Lomb, Inc; 2023. **2.** Sheppard JD, Nichols KK. Dry eye disease associated with meibomian gland dysfunction: focus on tear film characteristics and the therapeutic landscape. *Ophthalmol Ther.* 2023;12(3):1397-1418. doi:10.1007/s40123-023-00669-1 **3.** Vittitow J, Kissling R, DeCory H, Borchman D. In vitro inhibition of evaporation with perfluorohexyloctane, an eye drop for dry eye disease. *Curr Ther Res Clin Exp.* 2023;98:100704. doi:10.1016/j.curtheres.2023.100704 **4.** Data on file. Bausch & Lomb, Inc; 2023. **5.** Tauber J, Berdy GJ, Wirta DL, Krösser S, Vittitow JL; GOBI Study Group. NOV03 for dry eye disease associated with meibomian gland dysfunction: results of the randomized phase 3 GOBI study. *Ophthalmology.* 2023;130(5):516-524. doi:10.1016/j.ophtha.2022.12.021 **6.** Sheppard JD, Kurata F, Epitropoulos AT, Krösser S, Vittitow JL; MOJAVE Study Group. NOV03 for signs and symptoms of dry eye disease associated with meibomian gland dysfunction: the randomized phase 3 MOJAVE study. *Am J Ophthalmol.* 2023;252:265-274. doi:10.1016/j.ajco.2023.03.008

BAUSCH + LOMB

©2024 Bausch + Lomb
MBO.0098.USA.23 V2.0



Learn more at
MIEBO-ECP.COM

BRIEF SUMMARY OF PRESCRIBING INFORMATION

This Brief Summary does not include all the information needed to use MIEBO safely and effectively. See full Prescribing Information for MIEBO.

MIEBO™ (perfluorohexyloctane ophthalmic solution), for topical ophthalmic use

Initial U.S. Approval: 2023

1 INDICATIONS AND USAGE

MIEBO™ (perfluorohexyloctane ophthalmic solution) is indicated for the treatment of the signs and symptoms of dry eye disease (DED).

4 CONTRAINDICATIONS

None.

5 WARNINGS AND PRECAUTIONS

MIEBO should not be administered while wearing contact lenses. Advise patients that contact lenses should be removed prior to and for at least 30 minutes after administration of MIEBO.

6 ADVERSE REACTIONS

6.1 Clinical Trials Experience

Because clinical trials are conducted under widely varying conditions, adverse reaction rates observed in clinical trials of a drug cannot be directly compared to rates in the clinical trials of another drug and may not reflect the rates observed in practice.

In patients with DED, 614 patients received at least one dose of MIEBO in two randomized controlled clinical trials across 68 sites in the United States. The most common ocular adverse reaction was blurred vision. Blurred vision and conjunctival redness were reported in 1-3% of individuals.

8 USE IN SPECIFIC POPULATIONS

8.1 Pregnancy

Risk Summary

There are no adequate and well controlled studies with MIEBO in pregnant women.

In animal reproduction studies with oral administration of perfluorohexyloctane during the period of organogenesis, no adverse maternal or developmental effects were observed in rats at doses up to 162 times the recommended human ophthalmic dose (RHOD) (*see Data*). Maternal toxicity, miscarriages and reduced fetal weights were observed in rabbits at all doses tested, with the lowest dose as 41 times the RHOD.

All pregnancies have a risk of birth defect, loss, or other adverse outcomes. In the US general population, the estimated background risk of major birth defects is 2 to 4%, and of miscarriage is 15 to 20%, of clinically recognized pregnancies.

Data

Animal Data

An embryofetal study was conducted in pregnant rabbits administered perfluorohexyloctane by oral gavage on gestation days 6 to 19, to target the period of organogenesis.

Perfluorohexyloctane produced maternal toxicity, characterized by reduced body weight gain and food consumption, and miscarriages at all doses tested, with the lowest dose as ≥ 250 mg/kg/day (41 times the RHOD based on body surface area). Reduced fetal weights were also observed at ≥ 250 mg/kg/day but no fetal mortality or malformations. A no observed adverse effect level (NOAEL) for maternal toxicity was not established in rabbits.

An embryofetal study was conducted in pregnant rats administered perfluorohexyloctane by oral gavage on gestation days 6 to 17, to target the period of organogenesis. There was no evidence of embryofetal toxicity or teratogenicity at doses up to 2,000 mg/kg/day (162 times the RHOD).

8.2 Lactation

There are no data on the presence of perfluorohexyloctane in human milk, the effects on the breastfed infant, or the effects on milk production. The lack of clinical data during lactation precludes a clear determination of the risk of MIEBO to an infant during lactation; however, the developmental and health benefits of breastfeeding should be considered along with the mother's clinical need for MIEBO.

8.4 Pediatric Use

The safety and effectiveness of MIEBO in pediatric patients below the age of 18 years have not been established.

8.5 Geriatric Use

No overall differences in safety and effectiveness have been observed between elderly and younger patients.

12 CLINICAL PHARMACOLOGY

12.3 Pharmacokinetics

The pharmacokinetics of perfluorohexyloctane following topical ocular administration of MIEBO has not been quantitatively characterized in humans. A single pharmacokinetic (PK) study was conducted that showed low systemic perfluorohexyloctane blood levels after topical ocular administration. Perfluorohexyloctane was not metabolized by human liver microsomes in vitro.

13 NONCLINICAL TOXICOLOGY

13.1 Carcinogenesis, Mutagenesis, Impairment of Fertility

Long-term studies in animals have not been conducted to evaluate the carcinogenic potential of perfluorohexyloctane.

Perfluorohexyloctane was not mutagenic or clastogenic in a standard battery of genotoxicity tests, including a bacterial mutagenicity assay (Ames assay), an in vitro chromosome aberration assay using human peripheral lymphocytes, and an in vivo bone marrow micronucleus assay in rats.

17 PATIENT COUNSELING INFORMATION

Use with Contact Lenses

Advise patients that contact lenses should be removed prior to and for at least 30 minutes after administration of MIEBO.

Administration Instructions

Advise patients to instill one drop of MIEBO four times daily into each eye as depicted in the Administration Instructions.

Distributed by:

Bausch & Lomb Americas Inc. Bridgewater, NJ 08807 USA

Patented. See <https://patents.bausch.com> for US patent information.

©2023 Bausch + Lomb

MBO.0046.USA.23 Issued: 5/2023



NAION Risk Higher in Patients on GLP-1 Drugs

Exposure to agonists such as Ozempic and Mounjaro was associated with a 3.24-fold higher likelihood, study finds.

Non-arteritic anterior ischemic optic neuropathy (NAION), the most common acute optic neuropathy in those over 50 years old, is not well understood and causes irreversible blindness. Glucagon-like peptide-1 (GLP-1) receptor analogs are a newer, highly effective category of medication for diabetes management. Drugs such as semaglutide (Ozempic and Wegovy, both Novo Nordisk), as well as tirzepatide (Mounjaro, Eli Lilly), have risen in popularity because of their efficacy for glycemic control and weight loss promotion. With an increasing number of diabetic patients being prescribed these drugs, it is important that eyecare providers understand the implications. At ARVO 2024 in Seattle, researchers from Massachusetts Eye and Ear as well as Harvard Medical School presented findings that highlighted the link between prescribed GLP-1 inhibitors and the development of vision loss due to NAION.

The retrospective cohort study examined the association between the GLP-1R agonist and the development of NAION over a six-year period in the neuro-ophthalmology clinic. Patients with no prior NAION events were

identified from a centralized clinical data registry and patients were matched by cardiovascular risk factors, contraindications and indications for the use of this GLP-1R agonist. From a total of 17,292 patients, 6,426 unique patients were identified to have risk factors for NAION, and 307 were prescribed and dispensed GLP-1R agonists. Of those, 30 patients were diagnosed with NAION (incidence rate: 4.83). From the 1,236 patients in the non-GLP1R agonist-exposed cohort, 88 patients were diagnosed with NAION (incidence rate: 1.05 and risk ratio: 4.59).

This study found that the hazard of NAION was 3.24 times higher in individuals exposed to the GLP-1R agonists compared with those who were not, after adjusting for confounders. Males had a higher risk of NAION compared to females. Those with diabetes as well as those with hyperlipidemia were also at a higher risk. The model's overall significance was confirmed by the likelihood ratio test, Wald test and score test, all of which showed highly significant p-values.

"Clinicians and patients may consider this risk before initiating this GLP-1R agonist in those with a his-

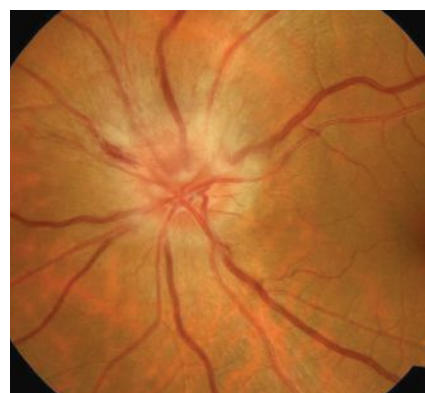


Photo: Neil Miller, MD

Men on these weight loss/diabetes control drugs had a higher risk of NAION compared with women.

tory of NAION, monocular patients and those with low vision at baseline," the researchers wrote in their abstract.

As more patients are started on GLP-1 analogues, optometrists should be aware of the frequency of potential worsening retinopathy that occurs with rapid, improved glycemic control. ◀

Original abstract content ©2024 Association for Research in Vision and Ophthalmology.

Carrero-Galeano JT, Krasniqi D, Rizzo JF, et al. Non-arteritic ischemic optic neuropathy in patients receiving a glucagon-like peptide receptor agonists in a tertiary care center. ARVO 2024 annual meeting.

IN BRIEF

■ **Post-cataract IOP Spike is Significant Predictor of Spike in Fellow Eye.** Research has established several contributing factors to elevated intraocular pressure (IOP) after cataract surgery, including male gender, high myopia, longer axial length, shallow anterior chamber depth, history of glaucoma treatment and

high baseline IOP. However, a study presented at ARVO 2024 explored the connection between an IOP spike in the first eye and its potential role in predicting one in the second eye.

The retrospective cohort study included 5,226 cataract patients in the University of Colorado Cataract Outcomes Database. IOP spike was defined as a post-surgery day one IOP >30mm Hg or IOP >10mm Hg change

from baseline. Researchers used multivariable logistic regression to assess the primary association with adjustment for potential confounding variables. They found the overall incidence of IOP spikes in the second eye was 4.6%, and 4.5% in the first eye. Patients who had an IOP spike in the first eye had a 23.9% incidence of an IOP spike in the second eye. The incidence rate was only 3.8% for

patients who didn't have an IOP spike in their first eye.

The authors concluded that a first-eye IOP spike has a profound influence on a second-eye IOP spike, regardless of other established preoperative and intraoperative risk factors.

Gnanaraj R, Taravella M, Lynch A, Patnaik J. First eye intraocular pressure spike as predictor of second eye spike in cataract surgery. ARVO 2024 annual meeting.



LEONARDO
science for a new vision



BUILD

your career

As EssilorLuxottica's innovative learning platform, Leonardo is the eyewear and eye care industry's leading educational resource. This new platform section is designed to help upskill staff and strengthen their knowledge, helping them become recognized as trusted optical practice members.



For more information or to find out how to enroll, visit leonardo.essilorluxottica.com

Low-dose Aspirin Not Effective in Preventing AMD

Although treatments that restore vision lost from AMD have flourished in the nearly two decades since the advent of anti-VEGF agents, there remains no proven intervention that can prevent onset on a widespread scale. Clinicians are left to advising patients on lifestyle modifications, including dietary changes and considerations of AREDS supplements. Aspirin, it seems, will be no help either.

That intervention was explored in a new study published recently in *JAMA Ophthalmology*. Researchers of this investigation looked at data from a large double-masked, placebo-controlled trial called Aspirin in Reducing Events in the Elderly (ASPREE), jointly conducted in the US and Australia from 2014 to 2018 that tested for efficacy of low-dose aspirin to prolong disability-free survival of older adults. An offshoot of the main study called ASPREE-AMD looked specifically at aspirin's influence on the course of the disease.

This substudy enrolled a total of 4,993 Australian individuals in ASPREE aged 70 or older without dementia, independence-limiting physical disability, cardiovascular disease or chronic illness limiting five-year survival and with gradable retinal images at baseline. Participants either received 100mg per day of aspirin or a placebo for three years. At trial termination, retinal follow-up

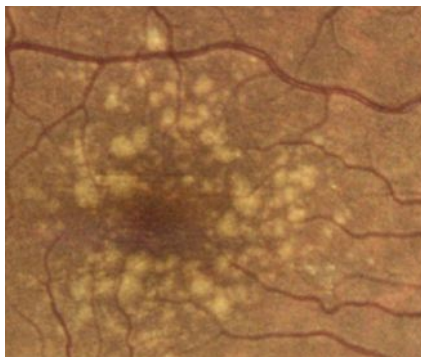


Photo: Jessica Hayes, OD

Low-dose aspirin was not found to have any benefit for AMD, although evidence was weaker for progression of AMD due to low numbers of cases that progressed.

data were available for 3,208 patients, with 3,171 being analyzed for AMD incidence and progression. This resulted in a median age of 73.5 years of age and median follow-up time was 3.1 years. The aspirin group saw a cumulative AMD incidence of 19.4% (195 of 1,004) while the placebo group's AMD rate was 19.1% (187 of 979). Cumulative progression from early/intermediate AMD to late AMD rates were also similar; the aspirin group rate was 2.3% (14 of 615) and the placebo group was 3.1% (18 of 573).

It should be noted that the ASPREE trial was terminated early and thus captured fewer cases of AMD progression. However, there was also no subgroup of participants for which the effects were different from the main results. That is,

aspirin's impact on AMD was not affected by age, use of alcohol or smoking, sex, BMI, hypertension or use of statins. As well, no evidence suggested that late AMD was more likely to occur in the group randomized to low-dose aspirin.

The study authors relay in their journal article that aspirin was proposed as an intervention for AMD because of its anti-inflammatory property, since inflammation likely plays a role in AMD pathogenesis. These suggestions that aspirin may be beneficial for reducing either AMD risk or progression came from the earlier randomized clinical trials of the Physicians' Health Study with five-year treatment and the Women's Health Study with 10-year treatment. However, neither result in these two studies were significant, despite the larger sample sizes and longer aspirin exposure. Both were limited instead by reliance on self-reported AMD status and confirmed by medical reports. Self-reporting is inaccurate, though, especially in early AMD stages.

In the article, the authors succinctly summarize that, "overall, these results do not support the suggestion that low-dose daily aspirin prevents the development or progression of AMD." ◀

Robman LD, Wolfe R, Woods RL, et al. Effect of low-dose aspirin on the course of age-related macular degeneration: a secondary analysis of the ASPREE randomized clinical trial. *JAMA Ophthalmol*. May 23, 2024. [Epub ahead of print].

IN BRIEF

■ Glaucomatous Eyes with High Systolic Blood Velocity May Progress Faster. The role of intraocular pressure (IOP) in glaucoma is central to discussions of disease management. Curiously, however, the interplay of IOP and blood pressure (BP) is likely a bit underemphasized in clinical practice.

In an ARVO study, researchers used a mathematical model based on the properties of blood flow in a large number of healthy eyes. Using color Doppler imaging (CDI), they documented a metric called peak systolic velocity and combined those findings with physiological principles to characterize POAG eyes and

identify those at a higher risk. Higher values for peak systolic velocity indicate stenosis, often in the carotid artery, as thinner vessels cause blood to traverse more rapidly.

The model developed by this team synthesizes cardiovascular principles with ocular findings. "If we feed it values that are easily measured like blood pressure, IOP and heart rate, it can estimate properties of blood in the body related to the eye," the researchers wrote in their abstract. "One of these properties is the systolic velocity of blood in the central retinal artery, which is important in getting the blood from the heart to the eye."

Over 900 POAG eyes with measurements of systolic velocity were

studied. Each subject's individualized IOP, blood pressure and heart rate values were then used estimate the peak velocity that would be expected from a standard healthy eye. The values estimated by the model were compared with CDI-measured values for each eye, then classified into three groups based on the difference between the model-estimated and the CDI-measured results as follows:

- Group 1: <2cm/s difference
- Group 2: 2-5cm/s difference
- Group 3: >5cm/s difference

Eyes in Group 1 had the highest values for retinal nerve fiber layer thickness, lowest cup-to-disc ratios and the lowest mean deviation and patterned standard deviation. In contrast, Group 3 showed the worst

structural and functional markers among the groups.

"We found that the eyes with the largest difference show the most damage. This shows promise for helping doctors recognize glaucoma eyes that are more at-risk of progressing," the authors explained in their abstract. The research continues to clarify the relationships between blood flow and IOP in ways that should help doctors to more strongly perceive that ocular health in the context of overall health and cardiovascular health specifically.

Rai R, Harris A, Vertiochio A, et al. Physiology-guided classification of primary open-angle glaucoma eyes based on systolic velocity deviation: a structural and functional analysis. ARVO 2024 annual meeting.

For the treatment of all stages
of neurotrophic keratitis (NK)



NOT JUST ANY SOLUTION A RESOLUTION

Complete and long-lasting resolution of NK for most patients*¹⁻⁴

- Up to 72% of patients achieved complete corneal healing in clinical trials*¹⁻³
- 80% of these patients remained healed at 1 year (REPARO trial)*⁴

*Resolution was evaluated in clinical trials as complete corneal healing, defined as the absence of staining in the lesion area and no persistent staining in the rest of the cornea after 8 weeks of treatment and as <0.5-mm lesion staining at 48-week follow-up.¹⁻³

¹Key study findings were after 8 weeks of treatment, 6 times daily. REPARO (Study NGF0212): 52 patients with Stage 2 or 3 neurotrophic keratitis (NK) in 1 eye per group; 72% (36/50) of patients completely healed; vehicle response rate 33.3% (17/51). Study NGF0214: 24 patients with Stage 2 or 3 NK in 1 or both eyes per group; 65.2% (15/23) completely healed; vehicle response rate 16.7% (4/24). Last post-baseline observation carried forward; chi-squared test. Patients without any post-baseline measurements were excluded from the analysis.¹⁻³

oxervate® 
(cenegermin-bkbj ophthalmic
solution) 0.002% (20 mcg/mL)

Important Safety Information WARNINGS AND PRECAUTIONS

Use with Contact Lenses

Contact lenses should be removed before applying OXERVATE because the presence of a contact lens (either therapeutic or corrective) could theoretically limit the distribution of cenegermin-bkbj onto the area of the corneal lesion. Lenses may be reinserted 15 minutes after administration.

Eye Discomfort

OXERVATE may cause mild to moderate eye discomfort such as eye pain during treatment. The patient should be advised to contact their doctor if a more serious eye reaction occurs.

ADVERSE REACTIONS

In clinical trials, the most common adverse reaction was eye pain following instillation which was reported in approximately 16% of patients. Eye pain may arise as corneal healing occurs. Other adverse reactions occurring in 1% to 10% of OXERVATE patients included corneal deposits, foreign body sensation, ocular hyperemia, ocular inflammation, photophobia, tearing, and headache.

USE IN SPECIFIC POPULATIONS

Pregnancy

There are no data from the use of OXERVATE in pregnant women to inform any drug associated risks.

Lactation

The developmental and health benefits of breastfeeding should be considered, along with the mother's clinical need for OXERVATE, and any potential adverse effects on the breastfed infant from OXERVATE.

Pediatric Use

The safety and effectiveness of OXERVATE have been established in the pediatric population. Use of OXERVATE in pediatric patients 2 years of age and older is supported by evidence from adequate and well-controlled trials of OXERVATE in adults with additional safety data in children.

INDICATION

OXERVATE® (cenegermin-bkbj) ophthalmic solution 0.002% (20 mcg/mL) is indicated for the treatment of neurotrophic keratitis.

DOSAGE AND ADMINISTRATION

Instill one drop of OXERVATE in the affected eye(s), 6 times a day at 2-hour intervals for eight weeks.

To report ADVERSE REACTIONS, contact Dompé U.S. Inc. at 1-833-366-7387 or FDA at 1-800-FDA-1088 or www.fda.gov/medwatch.

Please see the Brief Summary of full Prescribing Information for OXERVATE on the following page.

References: 1. OXERVATE® (cenegermin-bkbj) ophthalmic solution 0.002% (20 mcg/mL) [US package insert]. Boston, MA; Dompé U.S. Inc.; 2023. 2. Bonini S, et al. *Ophthalmology*. 2018;125:1332-1343. 3. Pflugfelder SC, et al. *Ophthalmology*. 2020;127:14-26. 4. Data on File. Clinical Study Report (NGF0212). Dompé U.S. Inc., 2016.

See more clinical data
OXERVATE.com/hcp



Brief Summary of full Prescribing Information

Consult the full Prescribing Information for complete product information, available at www.oxervate.com/prescribing-information.

INDICATIONS AND USAGE

OXERVATE[®] (cenegermin-bkbj) ophthalmic solution 0.002% is indicated for the treatment of neurotrophic keratitis.

DOSAGE AND ADMINISTRATION

General Dosing Information

Contact lenses should be removed before applying OXERVATE and may be reinserted 15 minutes after administration.

If a dose is missed, treatment should be continued as normal, at the next scheduled administration.

If more than one topical ophthalmic product is being used, administer the eye drops at least 15 minutes apart to avoid diluting products. Administer OXERVATE 15 minutes prior to using any eye ointment, gel or other viscous eye drops.

Recommended Dosage and Dose Administration

Instill one drop of OXERVATE in the affected eye(s), 6 times a day at 2-hour intervals for eight weeks.

WARNINGS AND PRECAUTIONS

Use with Contact Lens

Contact lenses should be removed before applying OXERVATE because the presence of a contact lens (either therapeutic or corrective) could theoretically limit the distribution of cenegermin-bkbj onto the area of the corneal lesion. Lenses may be reinserted 15 minutes after administration.

Eye Discomfort

OXERVATE may cause mild to moderate eye discomfort such as eye pain during treatment. The patient should be advised to contact their doctor if a more serious eye reaction occurs.

ADVERSE REACTIONS

Clinical Trials Experience

Because clinical studies are conducted under widely varying conditions, adverse reaction rates observed in the clinical studies of a drug cannot be directly compared to rates in the clinical studies of another drug and may not reflect the rates observed in practice.

In two clinical trials of patients with neurotrophic keratitis, a total of 101 patients received cenegermin-bkbj eye drops at 20 mcg/mL at a frequency of 6 times daily in the affected eye(s) for a duration of 8 weeks. The mean age of the population was 61 to 65 years of age (18 to 95). The majority of the treated patients were female (61%). The most common adverse reaction was eye pain following instillation which was reported in approximately 16% of patients. Eye pain may arise as corneal healing occurs.

Other adverse reactions occurring in 1% to 10% of OXERVATE patients included corneal deposits, foreign body sensation, ocular hyperemia, ocular inflammation, photophobia, tearing, and headache.

Postmarketing Experience

The following adverse reactions have been identified during postapproval use of OXERVATE. Because these reactions are reported voluntarily from a population of uncertain size, it is not always possible to reliably estimate their frequency or establish a causal relationship to drug exposure.

Eye disorders: eye irritation, blepharitis (including eyelid margin crusting and eyelid edema) and corneal neovascularization.

USE IN SPECIFIC POPULATIONS

Pregnancy

Risk Summary

There are no data from the use of OXERVATE in pregnant women to inform any drug associated risks.

Administration of cenegermin-bkbj to pregnant rats or rabbits during the period of organogenesis did not produce adverse fetal effects at clinically relevant doses. In a pre- and postnatal development study, administration of cenegermin-bkbj to pregnant rats throughout gestation and lactation did not produce adverse effects in offspring at clinically relevant doses.

Lactation

Risk Summary

There are no data on the presence of OXERVATE in human milk, the effects on breastfed infant, or the effects on milk production. The developmental and health benefits of breastfeeding should be considered, along with the mother's clinical need for OXERVATE, and any potential adverse effects on the breastfed infant from OXERVATE.

Pediatric Use

The safety and effectiveness of OXERVATE have been established in the pediatric population. Use of OXERVATE in this population is supported by evidence from adequate and well-controlled trials of OXERVATE in adults with additional safety data in pediatric patients from 2 years of age and older.

Geriatric Use

Of the total number of subjects in clinical studies of OXERVATE, 43.5 % were 65 years old and over. No overall differences in safety or effectiveness were observed between elderly and younger adult patients.

NONCLINICAL TOXICOLOGY

Carcinogenesis, Mutagenesis, Impairment of Fertility

Carcinogenesis and Mutagenesis

Animal studies have not been conducted to determine the carcinogenic and mutagenic potential of cenegermin-bkbj.

Impairment of fertility

Daily subcutaneous administration of cenegermin-bkbj to male and female rats for at least 14 days prior to mating, and at least 18 days post-coitum had no effect on fertility parameters in male or female rats at doses up to 267 mcg/kg/day (1709 times the MRHOD).

In general toxicology studies, subcutaneous and ocular administration of cenegermin-bkbj in females was associated with ovarian findings including persistent estrus, ovarian follicular cysts, atrophy/reduction of corpora lutea, and changes in ovarian weight at doses greater than or equal to 19 mcg/kg/day (119 times the MRHOD).



Study Reveals Effect of ADHD Medications on Glaucoma Risk

Attention deficit hyperactivity disorder (ADHD) affects between 5% to 10% of children and 4% of adults, many of whom manage their symptoms with medications including atomoxetine, methylphenidate and amphetamines. These drugs are contraindicated in patients with a history of angle-closure glaucoma (ACG) due to their sympathomimetic action, but their role in the development of open-angle glaucoma (OAG) vs. ACG remains unclear in the literature. This recently inspired researchers to conduct their own investigation with a retrospective cohort design and a case-control analysis, strengthened by the use of a large national database.

The study followed a total of 240,257 new users of atomoxetine (6.6% of the cohort), methylphenidate (33.8%) and amphetamines (44.5%) to the first diagnosis of ACG or OAG or until the end of follow-up. The mean age was 45, and

55% of the cohort was female. Four age-matched controls were selected for each case. The researchers adjusted the data for confounders and calculated adjusted incidence-rate ratios (aIRRs).

Throughout the study period of 2010 to 2018, 1,159 glaucoma cases were reported among the cohort. The data showed that regular users of atomoxetine and amphetamines had a higher aIRR for developing ACG compared with non-users (aIRR = 2.55 and 2.27, respectively), while methylphenidate users had a higher aIRR for developing OAG (aIRR = 1.23).

Although methylphenidate was the only drug in this investigation that appeared to increase the risk of OAG, the researchers pointed out in their paper on the study, published in the journal *Eye*, that, “It is worth noting that in our study, amphetamines and atomoxetine also trended towards increasing the risk

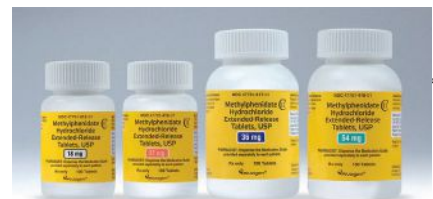

Photo: Avogon

Several common ADHD drugs are contraindicated in patients with a history of angle-closure glaucoma; however, this study found that one drug in particular—methylphenidate—was shown to have a greater effect on the risk of POAG.

of OAG, although this did not reach statistical significance.”

The authors concluded, “Given the prevalence of ADHD medication use (medically and recreationally), further studies are needed to confirm our findings and investigate associations of ADHD medication use and glaucoma,” while adding that their study merely “suggests a potential signal and not a major public health issue at present.” ◀

Darwich R, Etminan M, He B, Eadie BD. Medications for attention deficit hyperactivity disorder associated with increased risk of developing glaucoma. *Eye*. May 6, 2024. [Epub ahead of print].

High-dose Aflibercept Pushes Dosing Interval to Five Months

Since the launch of Eylea (aflibercept 2mg, Regeneron) over a decade ago, retina specialists and comanaging optometrists and ophthalmologists have relied heavily on this anti-VEGF agent for treating patients with neovascular age-related macular degeneration (nAMD) and other retinal disorders. However, the requirement of injections every one to two months can place a considerable burden on patients and practices, which led the company to develop a high-dose formulation (Eylea HD, 8mg) that can extend the maintenance interval by several months. The new drug gained FDA approval last summer based on the positive results of two clinical trials, Photon and Pulsar, which demonstrated non-inferiority and clinically equivalent vision gains at 48 weeks with eight-, 12- and 16-week dosing regimens after the three initial monthly doses.

Last month at ARVO in Seattle, researchers presented the 96-week results of the Pulsar trial, which evaluated the safety and efficacy of Eylea HD for nAMD. Similar to the 48-week outcomes, the drug showed that patients receiving high-dose aflibercept every 12 or 16 weeks—or longer in year two—maintained similar BCVA gains and had a safety profile compared with those treated with 2mg every eight weeks.

In the double-masked Pulsar trial, patients were randomly assigned 1:1:1 to receive aflibercept 8mg every 12 or 16 weeks (8q12 [n=335] or 8q16 [n=338]) or aflibercept 2mg every eight weeks (2q8 [n=336]), each after three initial monthly injections. From week 52 to week 96, dosing regimens for the high-dose aflibercept groups could be extended as needed based on study criteria. Here are the results recorded at week 96 of the Pulsar trial:

Seventy-five percent of 8q12 patients and 70% of 8q16 patients maintained ≥ 12 - and ≥ 16 -week dosing intervals. In the combined aflibercept 8mg arm, 47% who completed 96 weeks had dosing intervals of ≥ 20 weeks at week 96, and 28% had a 24-week interval. No new side effects were identified with the 8mg dose.

“In participants who received two years of aflibercept 8mg, almost half could have the time between injections increased to at least five months,” the presenters wrote. Accordingly, “These findings suggest that aflibercept 8mg may reduce the need for frequent injections in people with wet AMD,” they concluded. ◀

Original abstract content ©2024 Association for Research in Vision and Ophthalmology.

Sivaprasad S, Korobelnik JF. BCVA gains with aflibercept 8 mg maintained through week 96 in PULSAR with extended treatment intervals in patients with nAMD. ARVO 2024 annual meeting.

Study: Omega-3 Use for 12 Weeks Did Not Improve Dry Eye Symptoms

However, the regimen might prevent worsening of meibomian gland dropout in the condition.

Researchers in South Korea recently investigated whether the systemic re-esterified triglyceride (rTG) form of omega-3 fatty acid supplementation was effective in treating dry eye disease (DED) associated with MGD, compared with grapeseed oil supplementation (which has an antioxidant effect) using antioxidant foods that can be consumed in daily life as a control group. Their findings, which were published recently in *JAMA Ophthalmology*, did not show that supplementation of the rTG form of omega-3 fatty acid for 12 weeks was different from the control group taking grapeseed oil for ameliorating signs of dry eye by theoretically reducing inflammation in the plasma or ocular tissues. However, the supplementation did suggest greater changes in upper and lower eyelid telangiectasia and eyelid wiper epitheliopathy grades than with grapeseed oil.¹

This double-masked, parallel-group randomized clinical trial was

conducted at seven institutions with a total of 132 patients (mean age, 50.6 years; 78.0% women). The mean baseline OSDI scores of the omega-3 and grapeseed groups were 43.5 and 44.1, respectively. The study notes that 87.9% and 86.4% in the omega-3 and grapeseed groups, respectively, completed the 12 weeks of follow-up. The primary endpoint was the Ocular Surface Disease Index (OSDI) from baseline to six and 12 weeks.

The research team found no differences in compliance with the dietary supplement intake between groups

(omega-3, 95.8% and grapeseed, 95.4%). The OSDI change from baseline to six and 12 weeks was -20.5 and -22.7, respectively, in the omega-3 group and -15.1 and -18.8, respectively, in the grapeseed control group (difference at six weeks = -5.4 and at 12 weeks = -3.9). There were no changes in safety parameters or adverse events related to taking the dietary supplement in either group. Still, fewer than 60 participants were evaluated in each group.

“Although the amount of change in OSDI in each group was greater than the minimal clinically important difference suggested in the previous research, the difference in the OSDI change between groups was smaller than the minimal clinically important difference,” the researchers wrote in their paper.

Despite no differences in upper meibomian gland dropout change between groups, there was a difference suggested for the lower meibomian gland dropout changes between groups, which the study authors emphasized as a hypothesis-generating conclusion that warranted future clinical trials to determine this efficacy.

“In this study, lower meibomian gland dropout was possibly only exacerbated in the grapeseed group,” the researchers wrote. “Therefore, ω-3 supplementation could not improve meibomian gland dropout, but it might

“The duration of follow-up was only 12 weeks, so it is unclear how these participants would have fared with longer durations of therapy, the commentary noted.”



Photo: CGM Labs

Although no adverse events were noted with the dietary supplements, no benefit of the rTG form of omega-3 fatty acid was found in ameliorating DED signs by theoretically reducing inflammation in the plasma or ocular tissues.

prevent the worsening of meibomian gland dropout in DED associated with MGD if future clinical trials can compare this.”¹

A commentary also published in *JAMA Ophthalmology* highlighted that “the duration of follow-up was only 12 weeks, so it is unclear how these participants would have fared with longer durations of omega-3 supplementation. However, 12 weeks is also the median duration of follow-up in pivotal randomized, clinical trials submitted to the US FDA for approval of topical treatments for dry eye.”²

As the study was able to suggest omega-3 supplements may be associated with improvements in other secondary outcomes, the commentary author wrote that “more work may need to be done before the field makes a firm conclusion and fully closes the chapter on omega-3 fatty acid supplements for patients with evaporative dry eye.”²

1. Eom Y, Jun I, Jeon HS, et al. Re-esterified triglyceride ω-3 fatty acids in dry eye disease with meibomian gland dysfunction. *JAMA Ophthalmol.* May 16, 2024. [Epub ahead of print].
 2. Saldanha IJ. ω-3 fatty acid supplements may not improve dry eye symptoms. *JAMA Ophthalmol.* May 16, 2024. [Epub ahead of print].

INTRODUCING

THE RYZUMVI™ DIFFERENCE

Reverse dilation and reimagine
the post-dilation experience
for patients.^{1,2}

REDEFINE
the PATIENT
EXPERIENCE
POST-DILATION



 **Ryzumvi**™
(phentolamine
ophthalmic solution) 0.75%



1

RYZUMVI is the first and only relatively non-selective alpha-1 and alpha-2 adrenergic antagonist approved to reverse pharmacologically-induced mydriasis.¹



RYZUMVI reversibly binds to alpha-1 adrenergic receptors on the radial iris dilator muscle, thereby reducing pupil diameter, and indirectly reverses mydriasis induced by muscarinic antagonist effects on the iris sphincter muscle.¹



The onset of action after administration of RYZUMVI generally occurs in 30 minutes, with the maximal effect seen in 60 to 90 minutes, and the effect lasting at least 24 hours.¹

INDICATION

RYZUMVI™ (phentolamine ophthalmic solution) 0.75% is indicated for the treatment of pharmacologically-induced mydriasis produced by adrenergic agonists (e.g., phenylephrine) or parasympatholytic (e.g., tropicamide) agents.

IMPORTANT SAFETY INFORMATION

Warnings and Precautions

- **Uveitis:** RYZUMVI is not recommended to be used in patients with active ocular inflammation (e.g., iritis).
- **Potential for Eye Injury or Contamination:** To avoid the potential for eye injury or contamination, care should be taken to avoid touching the vial tip to the eye or to any other surface.
- **Use with Contact Lenses:** Contact lens wearers should be advised to remove their lenses prior to the instillation of RYZUMVI and wait 10 minutes after dosing before reinserting their contact lenses.

Adverse Reactions

The most common adverse reactions that have been reported are instillation site discomfort (16%), conjunctival hyperemia (12%), and dysgeusia (6%).

Please see Brief Summary of Prescribing Information on the adjacent page and the full Prescribing Information at RYZUMVI.com.



Visit RYZUMVI.com



Ryzumvi™

(phentolamine
ophthalmic solution) 0.75%

BRIEF SUMMARY: Consult the full Prescribing Information for complete product information available at www.RYZUMVI.com

INDICATIONS AND USAGE: RYZUMVI is indicated for the treatment of pharmacologically-induced mydriasis produced by adrenergic agonists (e.g., phenylephrine) or parasympatholytic (e.g., tropicamide) agents.

CONTRAINDICATIONS: None.

WARNINGS AND PRECAUTIONS

- **Uveitis:** RYZUMVI is not recommended when active ocular inflammation (e.g., iritis) is present because adhesions (synechiae) may form between the iris and the lens.
- **Potential for Eye Injury or Contamination:** To avoid the potential for eye injury or contamination, care should be taken to avoid touching the vial tip to the eye or to any other surface.
- **Use with Contact Lenses:** Contact lens wearers should be advised to remove their lenses prior to the instillation of RYZUMVI and wait 10 minutes after dosing before reinserting their contact lenses.

ADVERSE REACTIONS

Clinical Trials Experience: Because clinical trials are conducted under widely varying conditions, adverse reaction rates observed in the clinical trials of a drug cannot be directly compared to rates in the clinical trials of another drug and may not reflect the rates observed in practice.

RYZUMVI was evaluated in 642 subjects in clinical trials across various subject populations. The most common ocular adverse reactions reported in >5% of subjects were instillation site discomfort including pain, stinging, and burning (16%) and conjunctival hyperemia (12%). The only non-ocular adverse reaction reported in >5% of subjects was dysgeusia (6%).

USE IN SPECIFIC POPULATIONS

Pregnancy: **Risk Summary:** There are no available data with RYZUMVI administration in pregnant women to inform a drug-associated risk. In animal toxicology studies, when phentolamine was administered orally to pregnant mice and rats during the period of organogenesis skeletal immaturity and decreased growth was observed in the offspring at doses at least 24-times the recommended clinical dose. Additionally, a lower rate of implantation was seen in pregnant rats treated with phentolamine administered at least 60-times the recommended clinical dose. No malformations or embryofetal deaths were observed in the offspring of pregnant mice, rats, and rabbits administered phentolamine during the period of organogenesis at doses of at least 24-, 60-, and 20-times, respectively, the recommended clinical dose (see Data). RYZUMVI should only be used during pregnancy if the potential benefit justifies the potential risk to the fetus.

Data Animal Data Oral administration of phentolamine to pregnant rats and mice at doses at least 24-times the recommended clinical dose (based on a body weight per surface area (mg/m²) comparison with a 60-kg human)

References: 1. RYZUMVI (phentolamine ophthalmic solution). Prescribing Information. Ocuphire. 2. Boyd K. Mendoza O. What are dilating eye drops? American Academy of Ophthalmology. Available at: <https://www.aao.org/eye-health/drugs/dilating-eyedrops>. Accessed February 8, 2024.

resulted in slightly decreased growth and slight skeletal immaturity of the fetuses. Immaturity was manifested by increased incidence of incomplete or unossified calcanei and phalangeal nuclei of the hind limb and of incompletely ossified sternebrae. At oral phentolamine doses at least 60-times the recommended clinical dose (based on a mg/m² comparison with a 60-kg human), a slightly lower rate of implantation was found in rats. Phentolamine did not affect embryonic or fetal development in rabbits at oral doses at least 20-times the recommended dose (based on a mg/m² comparison with a 60-kg human). No malformations or embryofetal deaths were observed in the rat, mouse or rabbit studies.

Lactation: **Risk Summary:** There is no information regarding the presence of phentolamine in human milk, the effects on the breastfed infants, or the effects on milk production during lactation to inform risk of phentolamine ophthalmic solution 0.75% to an infant. The developmental and health benefits of breastfeeding should be considered along with the mother's clinical need for RYZUMVI and any potential adverse effects on the breastfed child from RYZUMVI.

Pediatric Use: The safety and effectiveness of RYZUMVI have been established in pediatric patients aged 3 to 17 years. No overall differences have been observed between pediatric and adult subjects.

Geriatric Use: No overall differences in safety and effectiveness have been observed between elderly and younger adult subjects.

OVERDOSAGE

No deaths due to acute poisoning with phentolamine have been reported. Overdosage with parenterally administered phentolamine is characterized chiefly by cardiovascular disturbances, such as arrhythmias, tachycardia, hypotension, and possibly shock. In addition, the following might occur: excitation, headache, sweating, visual disturbances, nausea, vomiting, diarrhea, or hypoglycemia. There is no specific antidote; treatment consists of appropriate monitoring and supportive care. Substantial decreases in blood pressure or other evidence of shock-like conditions should be treated vigorously and promptly.

CARCINOGENESIS, MUTAGENESIS, IMPAIRMENT OF FERTILITY

Carcinogenesis: Carcinogenicity studies with RYZUMVI have not been conducted.

Mutagenesis: Phentolamine was not mutagenic in the in-vitro bacterial reverse mutation (Ames) assay. In the in-vitro chromosomal aberration study in Chinese hamster ovary cells, numerical aberrations were slightly increased after a 4-hour exposure to phentolamine without metabolic activation, and structural aberrations were slightly increased after a 4-hour exposure to phentolamine with metabolic activation only at the highest concentrations tested, but neither numerical nor structural aberrations were increased after a 20-hour exposure without metabolic activation. Phentolamine was not clastogenic in two in-vivo mouse micronucleus assays.

Impairment of Fertility: The effect of phentolamine on female fertility has not been studied. Male rats treated with oral phentolamine for nine weeks (four weeks prior to mating, 3 weeks during the mating period and 2 weeks after mating) were mated with untreated females. At doses up to 648-times human therapeutic exposure levels at the C_{max}, no adverse effects on male fertility parameters or on reproductive parameters in the untreated females mated with the treated males were observed.

Marketed by: Oyster Point Pharma, Inc., a Viatris company



Bariatric Surgery May Reduce Risk for Ocular Diseases

Obesity is a major health concern linked to increased mortality risk. Studies show that bariatric surgery for morbid obesity effectively reduces BMI and risk

factors for heart disease and metabolic syndrome. Obesity has also been connected to ocular disease states such as diabetic retinopathy and glaucoma, prompting increased attention on the

TABLE 1. ASSOCIATIONS WITH BARIATRIC SURGERY

Condition	Postsurgical Relative Risk
diabetic retinopathy	0.283
macular edema	0.224
vitreous hemorrhage	0.459
ocular hypertension	0.387
glaucoma	0.360
use of glaucoma drugs	0.565
AMD	0.628
cataract surgery	0.524
low vision and blindness	0.328

potential effects of this surgery on ocular health. In a recent paper, researchers found bariatric surgery was linked to future risk reduction of several ocular disease states.

The retrospective study identified patients with the ICD-10 code for morbid obesity and a procedural code for bariatric surgery in a national database. A matched control cohort of those without a bariatric surgery procedural code was also included (both groups, n=42,408).

The researchers reported that bariatric surgery was associated

with a reduced future risk of diabetic retinopathy, macular edema, vitreous hemorrhage, ocular hypertension, glaucoma, use of ocular pressure lowering medications, AMD, cataract surgery, and low vision and blindness vs. patients who didn't undergo the surgery. Relative risk figures are shown in *Table 1*.

"This study largely supports and adds clarity to what has been reported in the literature regarding patients undergoing bariatric surgery and ocular pathology," the researchers concluded in their paper, although they also point out that it's the first conducted across a large population and one of the first to connect the surgery with changes in future glaucoma risk. ◀

Russell MW, Kumar M, Li A, et al. Incidence of ocular pathology following bariatric surgery for with morbid obesity across a large United States national database. *Eye*. April 27, 2024. [Epub ahead of print].

More Evidence Supports Red Light Therapy in Myopia

As the prevalence of myopia continues to grow, there is a greater need for treatments to slow progression of or reduce incidence of the condition. Previous studies have shown a difference in the mean change in the spherical equivalent refraction (SER) between treatments such as atropine and low-level red light (LLRL). New research published in *JAMA Ophthalmology* evaluating the efficacy and safety of daily LLRL for one year found slowing of progression in both SER and axial length (AL) with no safety concerns.

A total of 336 children between the ages of six and 12 were randomly allocated into the LLRL group or control group in a 1:1 ratio. The control group contained 86 female patients and the treatment group contained 90 female patients with the mean age of nine. A total of 161 in the LLRL group and 159 in the control group returned for the six-month follow-up. A total of 157 in the LLRL group and 152 in the control group returned for the 12-month follow-up.

The mean change in SER among untreated controls was almost 1D more myopic, and these subjects also gained about one-third of a millimeter in axial length. "These findings suggest daily use of 650nm LLRL for one year can slow progression of SER and AL without safety concerns identified," the authors explained in their paper for the journal. "In terms of AL and SER, children with myopia benefit 30% or more from 650nm intervention treatment than children without myopia," the authors explained.

The authors noted there may be a dose-response effect. "In a previous study that used 650nm LLRL five days per week, the one-year mean difference in AL between the treatment and control groups was 0.26mm; however, in the present study, with a higher frequency of seven days per week, the one-year mean difference in AL was 0.37mm," the authors noted.

In all these studies, the participants were of similar age, the duration of a single intervention was the same (three

minutes) and the power of the laser entering the pupil was the same (0.29mW). One of the studies showed a median compliance of 75%, and 14.2% of the patients had a compliance rate less than 50%. In this current study, the median compliance was 86% and the lowest compliance was 63%. The higher compliance may explain why the effect in this study seems better than that in previous studies, the authors suggested.

Three children reported seeing after images and four reported feeling strong light; otherwise, no adverse events occurred. OCT and fundus images revealed no structural damage to the retina and there was no decrease in uncorrected distance visual acuity.

"Confirmation of these findings at independent sites seems warranted, as well as determining whether these effects can be sustained with or without continued treatment," the authors concluded. ◀

Cao K, Tian L, M DL, et al. Daily low-level red light for spherical equivalent error and axial length in children with myopia. *JAMA Ophthalmol*. April 25, 2024. [Epub ahead of print.]

SITA Fast and Faster Need Modified Criteria

One recent ARVO study revealed that applying SITA Standard mean deviation cutoffs to the newer protocols can lead to misdiagnosis.

Last month at ARVO 2024 in Seattle, many changes and advancements in glaucoma were discussed, including the evolution of visual field testing as more patient friendly protocols become mainstream. One study specifically delved into the topic of differences between SITA Standard and the newer strategies of SITA Fast and SITA Faster. As practices adopt the faster testing methods, do the SITA Standard criteria to classify glaucoma severity and rate of expected mean deviation (MD) still apply?

This is exactly what a group of researchers from Wilmer Eye Institute at Johns Hopkins University explored, collecting a total of 392,654 visual fields (VFs) using the 24-2 pattern for all three SITA protocols from 42,035 glaucoma patients and suspects. All included had at least five VFs conducted at Wilmer over a 26-year period. Percent misdiagnosis was estimated through the researchers' construction of a "within six-month" retest distribution, consisting of all sensitivities measured by a given test strategy within six months of a SITA Standard baseline dB value. Expected sensitivities (means of the retest distributions) and expected MD values were compared between test strategies and used to adjust Hodapp-Parrish-Anderson (HPA) criteria for SITA Fast and SITA Faster.

The researchers found that HPA cutoffs should be adjusted for partitioning MD data into classifications of

severe, moderate and mild. As the two faster protocols use fewer stimuli, clinicians who move patients from SITA Standard to a Fast or Faster test sometimes observe an artificially "better" result from the less rigorous protocols. Failure to adjust for this phenomenon could lead to misdiagnosis.

For instance, this study found that percentages of moderate glaucoma cases to be misclassified as mild were 21.5% for SITA Fast and 22.3% for SITA Faster results. Rates of misdiagnosis of severe glaucoma as moderate were 19.9% for SITA Fast and 30.2% for SITA Faster. Rapid MD worsening (>90th percentile) was misjudged as moderate (75th to 90th percentile) at rate of 9.8% for SITA Fast and 22.7% for SITA Faster, while moderate MD worsening was misconstrued as mild at rates of 7.6% for SITA Fast and 15.4% for SITA Faster.

The authors consequently note that "potentially significant levels of misdiagnosis may result when applying SITA Standard based criteria for classifying glaucoma severity and the rate of MD worsening to SITA Fast and SITA Faster. Classification criteria should be appropriately adjusted when using SITA Fast or SITA Faster. Based on their research, adjustments need to

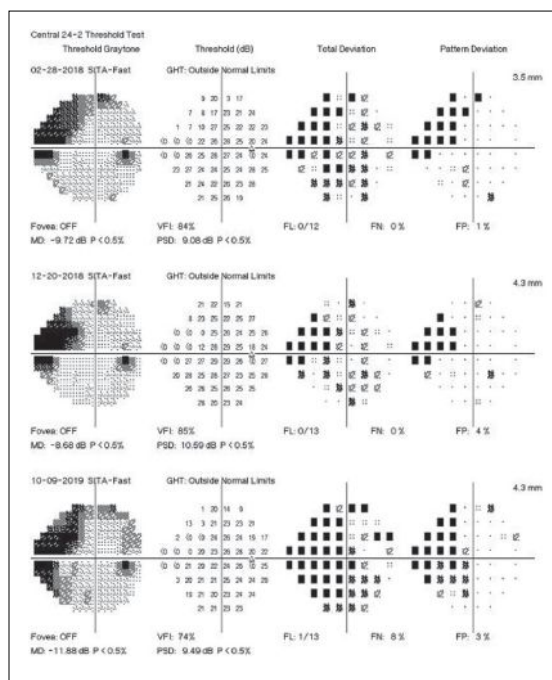


Photo: Michael Chelgajian, OD

Glaucoma progression should be closely monitored for progression due to a potentially high misdiagnosis rate when switching to newer versions of VF testing.

be made for the newer SITA protocols as seen in *Table 1*.

Andrew Rixon, OD, of Southern College of Optometry, offers some greater insight into how these findings project clinically. He mentions that the study "addresses the concern that in moderate and severe diseases progression may be masked by the faster strategies and we need to be vigilant in our practices in attaining sufficient information to determine change once we change strategies."

He also cautions that "it should reinforce to us that transitioning to newer strategies, even on the same device, does not mean these newer strategies will blend perfectly with the old."

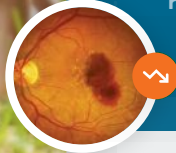Original abstract content ©2024 Association for Research in Vision and Ophthalmology.

Bradley C, Almidani L, Herbert P, Yohannan J. Estimating percent misdiagnosis when applying SITA-Standard criteria to SITA-Fast and SITA-Faster. ARVO 2024 annual meeting.

TABLE 1. GLAUCOMA STAGING BY HPA CRITERIA WITH PROPOSED MODIFICATIONS

	Early	Moderate	Severe
SITA Standard (HPA)	below -6 dB	between -6 and -12 dB	above -12 dB
SITA Fast (proposed)	below -5.3 dB	between -5.3 and -10.8 dB	above -10.8 dB
SITA Faster (proposed)	below -5.2 db	between -5.2 and -10 dB	above -10 dB

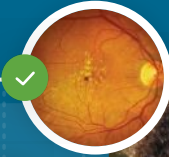Prevent AMD Vision Loss with Digital Healthcare



IRIS REGISTRY

20/83 VA

Average at wet AMD diagnosis according to IRIS Registry real-world data¹



ALOFT STUDY

≥20/40 VA

Average at wet AMD diagnosis with ForeseeHome²



ForeseeHOMETM
AMD Monitoring Program

Early Detection Helps Preserve Vision

ForeseeHome is a **remote monitoring** program for at-risk dry AMD patients that helps **detect wet AMD earlier** and alerts you of changes.


Remote patient monitoring leads to better outcomes and stronger optometric practices

- ✓ FDA Cleared
- ✓ Medicare Covered

- Plug and play digital health solution for your patients
- Solidify long-term relationships with your patients
- No cost to your practice
- Strengthen your referral relationships with qualified wet AMD referrals

The Key to Successful Home Monitoring

NOTAL VISION MONITORING CENTER



Engagement & Education

Benefits Verification & Authorization

Continuous Monitoring



Practice Workflow Implementation

Remote Patient Management

Vision Alert Management



ForeseeHome is a registered trademark, and the ForeseeHome AMD Monitoring Program and logo and the Notal Vision logo are trademarks of Notal Vision. © 2023 Notal Vision, Inc. All rights reserved.

References: 1. Rao P et al. *Ophthalmology*. 2018;125(4):522-528. 2. Mathai M, Reddy S, Elman MJ, Garfinkel RA, Ladd B, Wagner A, Sanborn GE, Jacobs J, Busquets M, Chew EY; ALOFT study group. Analysis of the Long-term visual Outcomes of ForeseeHome Remote Telemonitoring - The ALOFT study. *Ophthalmology Retina*. 2022;6:922-929.

See website for FDA Indication for Use.

SM-169.3



GET STARTED TODAY

1-855-600-3112

Mon-Fri, 8 AM to 6 PM EST

notalvision.info/revopt

Three Scope Expansion Efforts Remain Active, Others Stall

At the start of 2024, a record number of states—more than a dozen—were advocating for the expansion of their optometric scope, 10 of which were proposing the use of optometric lasers. We’re nearly halfway through the year and just three bills remain in pursuit in New Jersey, Ohio and Washington D.C.

The only state to witness the passage of its scope bill this year has been South Dakota, which brought the tally of optometric laser states up to 12. Under the new law, which was enacted in March and goes into effect on July 1, optometrists in the state with the proper certifications will be permitted to perform SLT, YAG capsulotomy, certain injections and intense pulsed light.

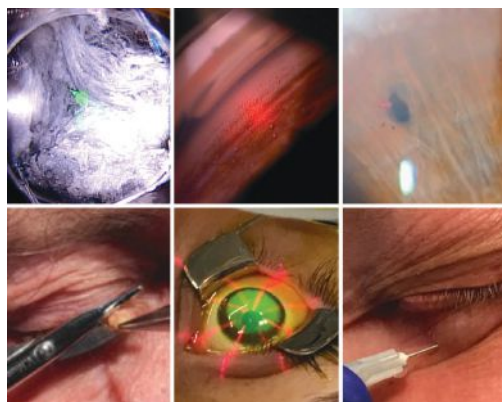
Several other states pursuing scope expansion this year were met with a less favorable outcome. California, Utah, Kansas, West Virginia, Vermont, Nebraska, Minnesota, Missouri and, most recently, New Hampshire, all had their scope bills voted against or postponed since January. Additionally, a laser bill in Alabama failed to make it out of negotiations in time to play out in this year’s legislative session.

Wins and losses aside, let’s take a look at where things stand with the three active scope battles that remain.

New Jersey

Last year, this state introduced two identical laser bills (A-920 and S-354) proposing to add SLT, capsulotomy, LPI, removal of lid lesions and an expansion of vaccine and prescription authority. The legislation’s progress has since been slow but steady; most recently, on March 14 the Assembly Regulated Professions Committee voted unanimously to release A-920 with only minor amendments.

“The bill language was tightened up so the New Jersey State Board of Optometrists has less authority to identify procedures that are not specified in the bill,” explains Keira Boertzel-Smith, Executive Director of the New Jersey Society of Optometric Physicians. The Assembly bill



Optometrists across the country continue to advocate for the right to practice to the full extent of their education by bringing in numerous advanced procedures. The always contentious issue has seen its share of both wins and losses this year.

is now on second reading in the Committee.

Meanwhile, S-354 is still pending in the Senate Commerce Committee. Feeling optimistic, Ms. Smith comments, “We are continuing to build support for the bill and hope the bill will receive further action later in the spring.”

Ohio

Looking to update their 17-year-old scope bill, optometrists and advocates in this state introduced Senate Bill 129 last June, which proposes to allow Ohio ODs to remove benign lesions, cysts and skin tags, as well as use lasers for YAG capsulotomy, SLT and LPI. It also seeks to broaden ODs’ pharmaceutical authority and permit epinephrine injections. Additionally, the bill advocates increasing the authority of the Vision Professionals Board to establish training guidelines.

SB 129 hasn’t seen much movement in the past year since its introduction. It currently resides in the state’s Senate Health Committee, which heard the proponent testimony last month on April 24. Opponent testimony will follow, though no date has been scheduled at this time.

D.C.

It’s been 25 years since this jurisdiction last updated its optometric scope

of practice, but that could change as soon as next week. On June 3, the mayor of D.C., Muriel Bowser, is due to respond to Bill 25-0545, which seeks to update the practice scope for numerous allied health professionals, including optometrists.

If passed, the bill would allow ODs in D.C. to prescribe and administer controlled substances for ocular conditions—a right that’s been granted to optometrists nearly everywhere else in the country, with the exception of Hawaii, Maryland and New York.

The Ones that Got Away

The constraint of time prevented several states’ scope bills from moving further along this year, though it’s likely most will be reintroduced in the next legislative session. Here’s what went down in a few states whose scope bills were recently put on pause.

New Hampshire. Introduced at the start of the year, Senate Bill 400 proposed to authorize YAG capsulotomy, SLT and other minor surgical procedures. The legislation also intended to increase the authority of the state’s optometry board, which would allow it to have “more ability to approve certain things as new training and technology comes along without having to go back for legislation every time,” explains Angelique Sawyer, OD, of the New Hampshire Optometric Association.

The state’s Senate passed SB 400 in early February, and on May 13 the New Hampshire House Executive Departments and Administration Committee passed the legislation with a vote of 14-6 but recommended it be referred for interim study to gather more data on safety. Unfortunately, in order to allow time for the interim study, the New Hampshire House voted to table the bill on May 23; essentially, this means that the legislation may be considered at a later date.

Missouri. This state had two identical laser bills in the running this year—SB 956 and HB 1963—both of which gained a favorable vote in their respective com-

mittees in late April. Unfortunately, the bills didn't have a chance to be voted on by their full chambers before the state's legislative session adjourned earlier this month. Hopefully, optometrists and their advocates in Missouri will be able to pick up where they left off next January.

Nebraska. Last year, Nebraska introduced LB 216, legislation proposing to add a single laser procedure—SLT—to optometrists' legal practice scope. The bill was heard by the Health and Human Services Committee last January and carried over into this year's legislative session. Unfortunately, the document didn't make it out of the Committee before the session adjourned last month. At the time of this writing, the Nebraska Optometric Association (NOA) says it cannot yet report on the bill's future endeavors.

Looking ahead, the NOA is redirecting its focus on helping to enhance the state's Credentialing Review Program, which may require statutory changes (requiring legislation), as well as regulatory and administrative process changes and could have implications for optometrists'

scope of practice in the state. The process will involve the Nebraska Department of Health and Human Services, the Nebraska Board of Health and allied health organizations.

The Nebraska Board of Health appointed a subcommittee to develop recommendations for the Program, and an interim study is underway now. Keep an eye on our News Feed for updates.

Minnesota. While not pursuing laser authority for its ODs, Minnesota introduced several scope bills last year proposing to allow eyelid injections and prescribing of oral carbonic anhydrase inhibitors, oral antiviral medication and oral steroids. Additionally, the legislation proposes allowing the state's Board of Optometry to establish the scope of practice guidelines. The state wrapped up the 2024 legislative session earlier this month without granting a final verdict on any of the proposed bills, though hopefully they'll be considered again next year.

Vermont. This state's laser bill (S.233) spent the duration of the 2024 legislative

session awaiting a hearing in the state's Senate Healthcare Committee that, similar to in Missouri and Nebraska, didn't have a chance to occur before the session adjourned earlier this month. The Vermont Optometric Association is currently mapping out its next steps to try and push the legislation further along in 2025.

Alabama. Following an unsuccessful pursuit of laser authority in 2023, the Alabama Optometric Association and fellow scope expansion advocates in the state have been working alongside legislators to introduce a similar bill. For the entirety of this year's legislative session, which wrapped up on May 7, Alabama's laser bill remained in negotiations, a process that will continue in the 2025 legislative session.

Howard Day, OD, president of the Alabama Optometric Association, is hopeful that by next January, they will be able to reach a compromise with organized medicine and ophthalmology, who aggressively pushed back against the bill during its last legal run. ◀

Elevate Your Practice With 4 Easy Steps

Like a well-oiled machine, the  Zea Performance System™ components are designed to support and elevate each other and your practice.

1. MEASURE

Measure macular pigment optical density (MPOD), a critical biomarker for eye and overall health, with the new Zx Pro™.



2. PRESCRIBE

Prescribe EyePromise nutraceuticals, the most clinically backed and comprehensive line of eye health nutraceuticals available and the only products guaranteed to increase MPOD.

3. ENROLL

Enroll patients into the Auto Refill Program, the industry-leading compliance solution that benefits practice and patient.



4. MONITOR

Monitor patients' progress with 6-month MPOD retests using the Zx Pro to help ensure patients are getting the results you expect.

Find out how the Zea Performance System can take your practice success to the next level.



CLINICAL EDITORS

CHIEF CLINICAL EDITOR ~ PAUL M. KARPECKI, OD

ASSOCIATE CLINICAL EDITORS ~ JOSEPH P. SHOVLIN, OD, CHRISTINE SINDT, OD

CONTRIBUTING EDITORS

RAMI ABOUMOURAD, OD, MIAMI

PAUL C. AJAMIAN, OD, ATLANTA

SHERRY J. BASS, OD, NEW YORK

ALISON BOZUNG, OD, MIAMI

DEREK N. CUNNINGHAM, OD, AUSTIN, TX

JAMES L. FANELLI, OD, WILMINGTON, NC

ANDREW S. GURWOOD, OD, PHILADELPHIA

PAUL M. KARPECKI, OD, LEXINGTON, KY

BISANT LABIB, OD, ELKINS PARK, PA

NATE LIGHTHIZER, OD, TAHLEQUAH, OK

PAMELA H. SCHNELL, OD, MEMPHIS

JOSEPH P. SHOVLIN, OD, SCRANTON, PA

JEROME SHERMAN, OD, NEW YORK

MARC TAUB, OD, MEMPHIS

MONTGOMERY VICKERS, OD, DALLAS

WALTER O. WHITLEY, OD, MBA, VIRGINIA BEACH, VA

EDITORIAL ADVISORY BOARD

JEFFREY R. ANSHEL, OD, KAUAI, HAWAII

JILL AUTRY, OD, RPH, HOUSTON

SHERRY J. BASS, OD, NEW YORK

EDWARD S. BENNETT, OD, ST. LOUIS

MARC R. BLOOMENSTEIN, OD, SCOTTSDALE, AZ

ALISON BOZUNG, OD, MIAMI

MILE BRUJIC, OD, BOWLING GREEN, OH

CHRIS J. CAKANAC, OD, MURRYSVILLE, PA

JERRY CAVALLERANO, OD, PhD, BOSTON

BRIAN CHOU, OD, SAN DIEGO

MICHAEL CHAGLASIAN, OD, CHICAGO

A. PAUL CHOUS, MA, OD, TACOMA, WA

GLENN S. CORBIN, OD, WYOMISSING, PA

MARK T. DUNBAR, OD, MIAMI

S. BARRY EIDEN, OD, DEERFIELD, IL

STEVEN FERRUCCI, OD, SEPULVEDA, CA

MURRAY FINGERET, OD, HEWLETT, NY

IAN BEN GADDIE, OD, LOUISVILLE, KY

GARY S. GERBER, OD, HAWTHORNE, NJ

JESSICA HAYNES, OD, MEMPHIS

MILTON HOM, OD, AZUSA, CA

DAVID KADING, OD, SEATTLE

JEROME A. LEGERTON, OD, MBA, SAN DIEGO

THOMAS L. LEWIS, OD, PhD, PHILADELPHIA

BLAIR B. LONSBERRY, MS, OD, MED, PORTLAND, OR

KELLY A. MALLOY, OD, PHILADELPHIA

DANICA MARRELLI, OD, HOUSTON

RON MELTON, OD, CHARLOTTE, NC

PAMELA J. MILLER, OD, JD, HIGHLAND, CA

MARC MYERS, OD, COATESVILLE, PA

CARLO J. PELINO, OD, JENKINTOWN, PA

JOSEPH PIZZIMENTI, OD, FORT LAUDERDALE, FL

CHRISTOPHER J. QUINN, OD, ISELIN, NJ

MOHAMMAD RAFIEETARY, OD, MEMPHIS

JOHN L. SCHACHET, OD, ENGLEWOOD, CO

JACK SCHAEFFER, OD, BIRMINGHAM, AL

PAMELA H. SCHNELL, OD, MEMPHIS

LEO P. SEMES, OD, JACKSONVILLE, FL

DIANA L. SHECHTMAN, OD, FORT LAUDERDALE, FL

JEROME SHERMAN, OD, NEW YORK

LEONID SKORIN, JR., OD, DO, ROCHESTER, MN

JOSEPH W. SOWKA, OD, SARASOTA, FL

JESSICA STEEN, OD, DAVIE, FL

BRAD M. SUTTON, OD, INDIANAPOLIS

LORETTA B. SZCZOTKA, OD, PhD, CLEVELAND

MARC TAUB, OD, MEMPHIS

TAMMY P. THAN, MS, OD, SUN CITY, AZ

RANDALL THOMAS, OD, MPH, CONCORD, NC

SARA WEIDMAYER, OD, ANN ARBOR, MI

KAREN YEUNG, OD, LOS ANGELES



Business Offices

19 Campus Boulevard, Suite 101
Newtown Square, PA 19073
Subscription inquiries (877) 529-1746 (USA only)
outside USA, call (847) 763-9630

PUBLISHER

MICHAEL HOSTER

(610) 492-1028

mhoster@jobson.com

SENIOR MANAGER, STRATEGIC ACCOUNTS

MICHELE BARRETT

(610) 492-1014

mbarrett@jobson.com

REGIONAL SALES MANAGER

JONATHAN DARDINE

(610) 492-1030

jdardine@jobson.com

PRODUCTION MANAGER

KAREN LALLONE

(610) 492-1010

kallone@jobson.com

DIGITAL MARKETING MANAGER

MATT EGGER

(610) 492-1029

megger@jobson.com

CLASSIFIED ADVERTISING

(888) 498-1460

SUBSCRIPTIONS

\$63 PER YEAR, \$99 (US) IN CANADA,
\$158 (US) IN ALL OTHER COUNTRIES
revoptometry@cambeywest.com

CIRCULATION

PO BOX 71, CONGERS, NY 10920-0071

(877) 529-1746

OUTSIDE USA: (845) 267-3065

SENIOR CIRCULATION MANAGER

HAMILTON MAHER

(212) 219-7870

hmaher@jihhealth.com

CEO, INFORMATION GROUP SERVICES

BILL SCOTT

SENIOR VICE PRESIDENT, CREATIVE SERVICES & PRODUCTION

MONICA TETTAMANZI

CREATIVE DIRECTOR • INTERNATIONAL MEDICAL NEWSGROUP

LOUISE KOENIG

DIRECTOR, PRODUCTION /MANUFACTURING

REBECCA SLEBODNIK

SENIOR VICE PRESIDENT, HUMAN RESOURCES

TAMMY GARCIA

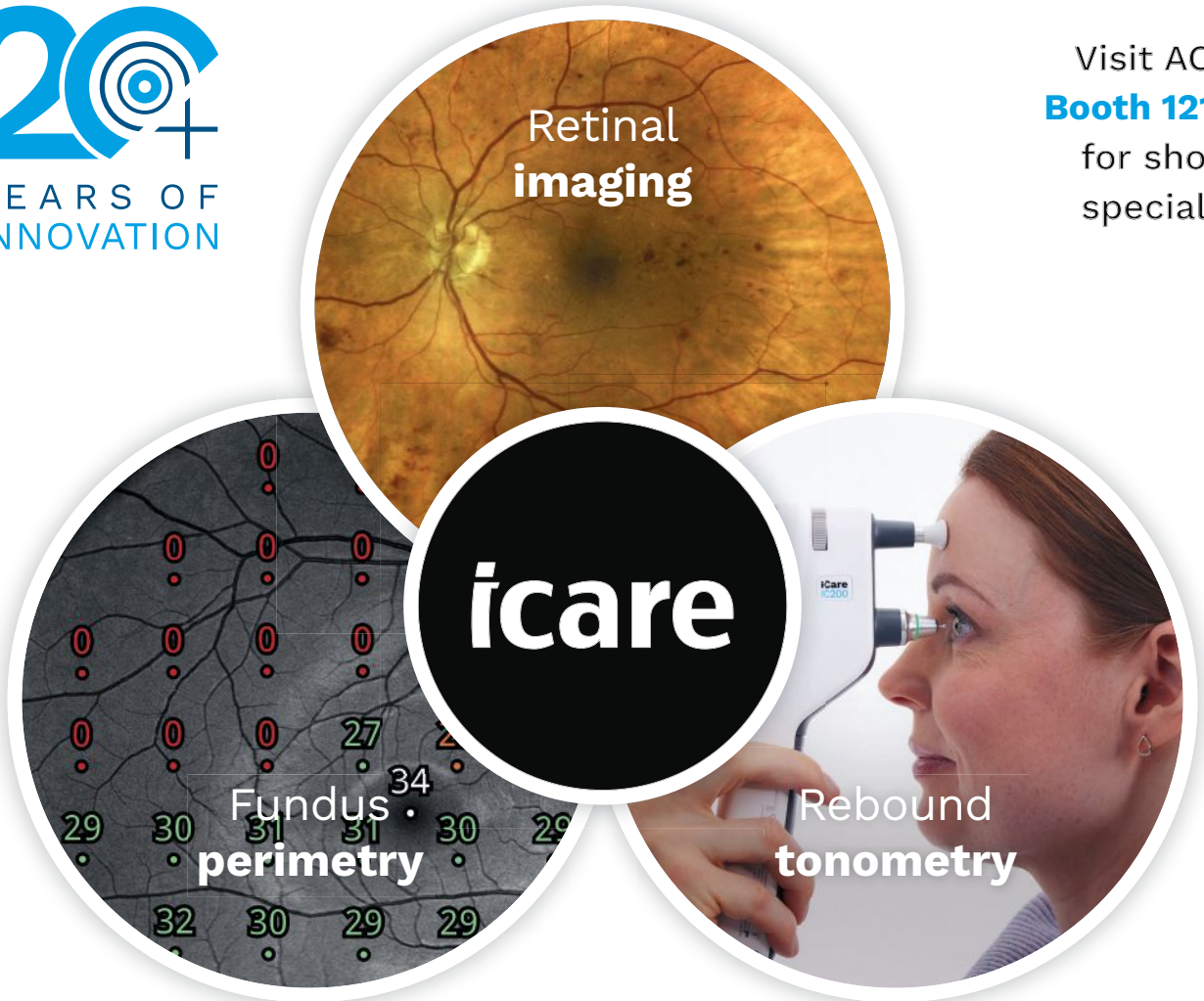
VICE PRESIDENT, CIRCULATION

JARED SONNERS

Jobson Health Information/WebMD
299 Market St. 2 Gateway Center - 4th Floor Newark NJ 07102



Visit AOA
Booth 1212
for show
specials!



You know us for tonometry.
**Get to know iCare for
imaging and perimetry.**



Discover the next level of eye care
with our full line of devices.

Scan or visit www.icare-world.com/USA

icare

iCare is a trademark of Icare Finland Oy. Icare Finland Oy, Icare USA, Inc., iCare World Australia Pty Ltd and Centervue S.p.A., are parts of Revenio Group and represent the brand iCare. iCare COMPASS, iCare DRSpplus, iCare EIDON, iCare EIDON AF, iCare EIDON FA, iCare IC100, iCare IC200 and iCare ILLUME are trademarks or registered trademarks of Icare Finland Oy in the EU and the USA and/or other countries. Centervue S.p.A. is the legal manufacturer of DRSpplus, COMPASS, EIDON, EIDON AF, EIDON FA, EIDON UWF Module, DRS, MAIA and S-MAIA. Not all products, accessories, services or offers are approved in every market. Approved labeling and instructions may vary from one country to another.
©2024 Icare Finland Oy. All rights reserved. ICARE-TRADE-ADS-378-EN-1.0-US

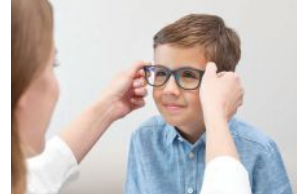FEATURES

REVIEW OF OPTOMETRY • Vol. 161, No. 6 • JUNE 15, 2024

36 Myopia Management: Putting Theory into Practice

A huge body of literature supports the concept, but many ODs struggle to implement various interventions. Here are lessons learned from the research that can help you.

By Langis Michaud, OD



15TH ANNUAL RETINA REPORT

50 AMD Staging: More than Wet vs. Dry

Various imaging biomarkers can help you get a truer sense of disease status and predict a patient's risk of progression. Here's what to look out for.

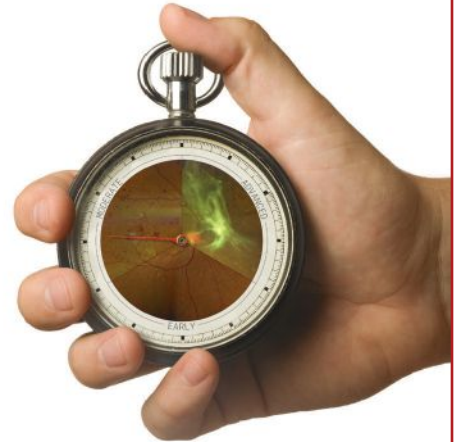By Steven Ferrucci, OD, and Mohammad Rafieetary, OD

COVER STORY

58 Diabetic Eye Disease: A Comprehensive Look at the Optometrist's Role

Learn what to pay attention to and when to take charge.

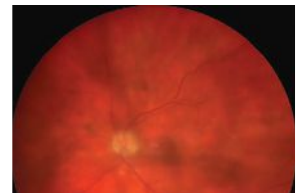
By Jessica Tarka, OD, and Carolyn Majcher, OD



72 Understanding Uveitis: Causes and Clinical Clues

We dive into common and uncommon etiologies for this condition and give advice on how to come up with a proper differential diagnosis for each patient.

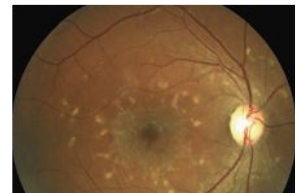
By Tunde Trennepohl, OD, William Hileman, OD, and Daniel Grangaard, OD



78 Are You Up to Speed on Inherited Retinal Dystrophies? – EARN 2 CE CREDITS

Enhance your patient care with an improved understanding of these genetic disorders and how they present in clinical practice.

By Roya Attar, OD, Rachel Steele, OD, and Jim Williamson, OD



REVIEW OF OPTOMETRY (ISSN 0147-7633) IS PUBLISHED MONTHLY, 12 TIMES A YEAR BY JOBSON MEDICAL INFORMATION LLC/WebMD, 283-299 MARKET STREET, 2 GATEWAY CENTER, 4TH FLOOR, NEWARK, NJ 07102. PERIODICALS POSTAGE PAID AT NEWARK, NJ AND ADDITIONAL MAILING OFFICES. POSTMASTER: SEND ADDRESS CHANGES TO REVIEW OF OPTOMETRY, PO BOX 81, CONGERS, NY 10920-0081. SUBSCRIPTION PRICES: US: ONE YEAR \$56; TWO YEARS \$97, CANADA: ONE YEAR \$88, TWO YEARS \$160, INT'L: ONE YEAR \$209, TWO YEARS \$299. FOR SUBSCRIPTION INFORMATION CALL TOLL-FREE (877) 529-1746 (USA); OUTSIDE USA, CALL (845) 267-3065. OR EMAIL US AT REVOPOTOMETRY@CAMBEYWEST.COM. PUBLICATIONS MAIL AGREEMENT NO: 40612608. CANADA RETURNS TO BE SENT TO BLEUCHIP INTERNATIONAL, P.O. BOX 25542, LONDON, ON N6C 6B2.

THE POWER OF **CARE**

You're there for them. We're here for you.

Care is everything. Integrated EHR/PM software makes healthcare better for everyone.

- Optometry-specific workflows
- Hands-free mobile documentation
- Revenue cycle management
- Frictionless interoperability

NextGen.com/Power-OPT

DEPARTMENTS

REVIEW OF OPTOMETRY • JUNE 15, 2024

FOLLOW US ON SOCIAL MEDIA

Facebook: revoptom

Twitter: revoptom

Instagram: revoptom

Threads: revoptom

LinkedIn: company/review-of-optometry

4

NEWS REVIEW

Clinical, legislative and practice updates for ODs.

24

OUTLOOK

School of Hard Knocks

Optometric education is both growing and stagnating at the same time. New colleges are fine. We need new ideas, too.

Jack Persico, Editor-in-Chief

27

THROUGH MY EYES

Make Your Mark

There are new options to manage retinal disease.

Paul M. Karpecki, OD

30

CHAIRSIDE

Jot It All Down

Looking back at memories of family and patients is priceless.

Montgomery Vickers, OD

32

FOCUS ON REFRACTION

It's Time for a Clip Show!

Celebrate our halfway point to 100 published columns with some of the highlights.

Pamela Schnell, OD, and Marc B. Taub, OD




34

CLINICAL QUANDARIES

Fade to Black

Be aware of the ups and downs of blood pressure in your cataract patients in case this situation occurs.

Paul C. Ajamian, OD



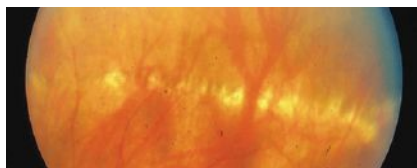
88

YOU BE THE JUDGE

Vicarious Liability Leads to Blindness

Yes, you may be responsible for the actions of your employees.

Jerome Sherman, OD, and Sherry Bass, OD



90

THERAPEUTIC REVIEW

Heartfelt Insight

Be aware of the cardiopulmonary effects of beta blockers.

Jessica Steen, OD



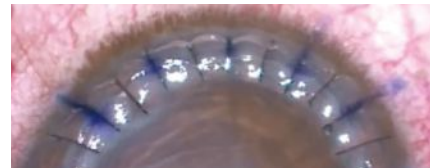92

SURGICAL MINUTE

A Close-up on Corneal Transplant Surgeries

We look carefully at the original procedure—PK—with a focus on post-op management.

Joshua Black, OD



94

PRODUCT REVIEW

New items to improve clinical care.


96

DIAGNOSTIC QUIZ

Clouding the Post-op Recovery

A patient with a complex posterior segment history presents with new anterior segment findings. What's happening and why?

Andrew S. Gurwood, OD



We Welcome Your Comments

Feedback from within the community provides important insights about clinical practice. If you would like to share your thoughts on the topics discussed in this issue—or the wider field of optometry at large—write to: editor@reviewofoptometry.com

BAUSCH+LOMB

The trifecta of **dry eye relief**

The first and only over-the-counter drop for dry eyes to combine hyaluronic acid and lipid nanoemulsion to relieve both evaporative and aqueous deficient symptoms.

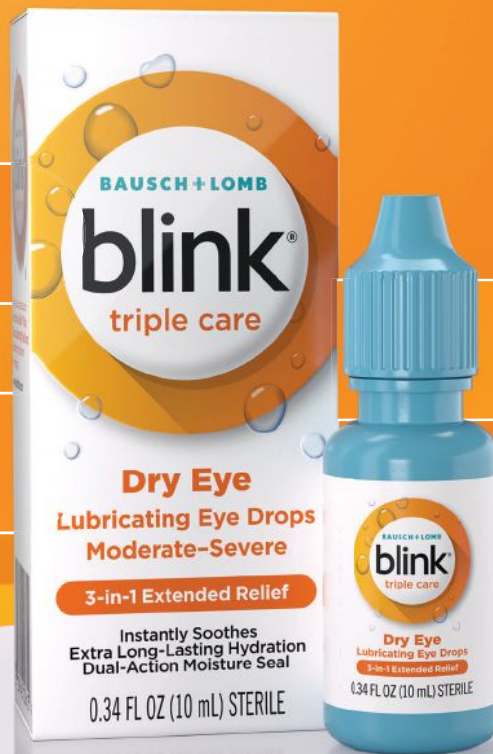

Instantly soothes



Extra long-lasting hydration

Locks in moisture



Call 1-855-542-5682 for samples!

EDITOR-IN-CHIEF

JACK PERSICO
(610) 492-1006 • jpersico@jobson.com

SENIOR EDITOR

JULIE SHANNON
(610) 492-1005 • jshannon@jobson.com

SENIOR ASSOCIATE EDITOR

MARK DE LEON
(610) 492-1021 • mdeleon@jobson.com

ASSOCIATE EDITOR

LEANNE SPIEGLE
(610) 492-1026 • lspiegle@jobson.com

ASSOCIATE EDITOR

RACHEL RITA
(610) 492-1000 • rrita@jobson.com

SENIOR SPECIAL PROJECTS MANAGER

JILL GALLAGHER
(610) 492-1037 • jgallagher@jobson.com

ART DIRECTOR

LYNNE O'CONNOR
lyoconnor@jobson.com

GRAPHIC DESIGNER

JAINE KOPALA
jkopala@jobson.com

DIRECTOR OF CE ADMINISTRATION

REGINA COMBS
(212) 274-7160 • rcombs@jobson.com**Clinical Editors**

Chief Clinical Editor • Paul M. Karpecki, OD

Associate Clinical Editors

Joseph P. Shovlin, OD, Christine W. Sindt, OD

Clinical & Education Conference Advisor

Paul M. Karpecki, OD

Case Reports Coordinator • Andrew S. Gurwood, OD

Columnists*Advanced Procedures* – Nate Lighthizer, OD*Chairside* – Montgomery Vickers, OD*Clinical Quandaries* – Paul C. Ajamian, OD*Cornea and Contact Lens Q+A* – Joseph P. Shovlin, OD*Diagnostic Quiz* – Andrew S. Gurwood, OD*The Essentials* – Bisant A. Labib, OD*Focus on Refraction* – Marc Taub, OD, Pamela Schnell, OD*Glaucoma Grand Rounds* – James L. Fanelli, OD*Ocular Surface Review* – Paul M. Karpecki, OD*Retina Quiz* – Rami Aboumourad, OD*Surgical Minute* – Derek Cunningham, OD, Walter Whitley, OD*Therapeutic Review* – Jessica Steen, OD*Through My Eyes* – Paul M. Karpecki, OD*Urgent Care* – Alison Bozung, OD*You Be The Judge* – Jerome Sherman, OD, Sherry Bass, OD**Editorial Offices**

19 Campus Blvd., Suite 101 • Newtown Square, PA 19073

Jobson Medical Information/WebMD
283-299 Market Street, 2 Gateway Center, 4th Floor
Newark, NJ 07102Subscription inquiries: (877) 529-1746
Continuing Education inquiries: (800) 825-4696

Printed in USA

BY JACK PERSICO
EDITOR-IN-CHIEF
OUTLOOK

School of Hard Knocks

Optometric education is both growing and stagnating at the same time. New colleges are fine. We need new ideas, too.

Optometry is getting bigger all the time. More ODs, more responsibilities, more patients, more products. Also, more optometry schools. We learned last month that the University of Texas Rio Grande Valley is gearing up to add a school of optometry. Two others have been in the works in North Carolina for a while, too. If all three come to pass, the US will have 27 schools and colleges of optometry in a few years.

Predictably, this news set off another round of hand-wringing about oversupply of ODs. I think rising workforce levels are worth being cognizant of—especially at the local level, where increased competition puts downward pressure on salaries and earnings—but mostly aren't the existential threat some make them out to be. As I harp on all the time in this column, ophthalmology's ranks are in decline, so optometry's growth is both necessary and welcome.

Many also express concern over perceived softness in the college acceptance process, pointing out that the ratio of applicants to matriculated students is pretty much 1:1 every year. If you want a spot, you'll get it. That's not a recipe for bringing the best and brightest into optometry's ranks, detractors say. The recurring bouts of collective panic over that also strike me as sort of a knee-jerk reaction. It's not exactly a welcome circumstance, but at face value it doesn't mean those new students aren't up to the task.

Critics will point to the declining NBEO board exam pass rates as evidence that too many subpar students do in fact get accepted. Admittedly, this one does strike a nerve. A whole lot of schools have first-time pass rates south of 50%. It would be an oversimplification to point the finger at any one college—old, new

or on the drawing board. But I think it's also unfair to pin that on the students themselves. Widespread failure rates point to a systemic problem more so than any individual student's shortcomings.

Rather, school curricula and teaching methods profession-wide need an upgrade, or at least a candid reappraisal, especially given the high cost of tuition. Optometry schools are enrolling ambitious young people who come in with the expectation that the institution's vetting process indicates they're fairly likely to succeed—then the school saddles them with six-figure debts. To me, this puts the onus on the schools to deliver on that bargain. Recent grads and current students complain of uninspiring lecturers who sometimes just flip through a slide deck and call it a lesson.

The NBEO itself comes in for its share of criticism for administering an exam process that is opaque to its applicants and too focused on esoterica than the applied clinical skills that new ODs will need. It certainly doesn't help that the footprint of what could/should be learned keeps growing as optometric scope expands. I know it keeps us at *Review* on our toes. For instance, just five years ago myopia control barely got a mention. This month, we have Langis Michaud giving us a 6,500-word summation of this burgeoning field and where it fits in optometric practice. What will we be publishing five years from now? Stick around and let's find out together.

But, that the thing. A field as dynamic as optometry needs to evolve its methods and culture of education to remain nimble. I would love to see a summit of all the stakeholders in optometric education held to hash it out. ASCO, NBEO and the societies for a start. Who's in? ■

IYUZEH™ (latanoprost ophthalmic solution) 0.005% is the first and only preservative-free latanoprost for patients with open-angle glaucoma (OAG) and ocular hypertension (OHT).

iyuzeh[™]
(latanoprost ophthalmic solution) 0.005%



Transform how you lower IOP.
**POWER
WITHOUT
PRESERVATIVES.**



Having the opportunity to prescribe IYUZEH for my patients is a game-changer. With IYUZEH, I can confidently prescribe an efficacious treatment to help lower IOP without preservatives.



Michael Chaglasian, OD, FAAO

Dr. Chaglasian is a paid consultant of Thea Pharma Inc.



INDICATIONS AND USAGE

IYUZEH™ (latanoprost ophthalmic solution) 0.005% is a prostaglandin F2a analogue indicated for the reduction of elevated intraocular pressure in patients with open-angle glaucoma or ocular hypertension.

IMPORTANT SAFETY INFORMATION

CONTRAINDICATIONS

Known hypersensitivity to latanoprost or any other ingredients in this product.

WARNINGS AND PRECAUTIONS

IYUZEH may cause changes to pigmented tissues. Most frequently reported changes are increased pigmentation of the iris, periorbital tissue (eyelid), and eyelashes. Pigmentation is expected to increase as long as IYUZEH is administered. Iris pigmentation is likely to be permanent. Eyelid skin darkening and eyelash changes may be reversible.

IYUZEH may cause gradual change to eyelashes including increased length, thickness, and number of lashes. These changes are usually reversible upon discontinuation of treatment.

IYUZEH should be used with caution in patients with a history of intraocular inflammation (iritis/uveitis) and should generally not be used in patients with active intraocular inflammation.

IYUZEH should be used with caution in aphakic patients, in pseudophakic patients with a torn posterior lens capsule, or in patients with known risk factors for macular edema.

Reactivation of herpes simplex keratitis has been reported during treatment with latanoprost. IYUZEH should be used with caution in patients with a history of herpetic keratitis.

Contact lenses should be removed prior to the administration of IYUZEH and may be reinserted 15 minutes after administration.

ADVERSE REACTIONS


The most common adverse reactions (5% to 35%) for IYUZEH are: conjunctival hyperemia, eye irritation, eye pruritus, abnormal sensation in eye, foreign body sensation in eyes, vision blurred, and lacrimation increased.

DRUG INTERACTIONS

The combined use of two or more prostaglandins or prostaglandin analogs including IYUZEH is not recommended. It has been shown that administration of these prostaglandin drug products more than once daily may decrease the IOP lowering effect or cause paradoxical elevations in IOP.

Please see full Prescribing Information at www.iyuzeh.com and Brief Summary on the next page.

Explore the power of preservative-free latanoprost at iyuzeh.com



Thea
let's open our eyes

IYUZEH is a trademark of Laboratoires Théa.
Copyright ©2024 Thea Pharma Inc. | All Rights Reserved. | PRC-IYZ-1953-v1 03.2024

iyuzeh™

(latanoprost ophthalmic solution) 0.005%

HIGHLIGHTS OF PRESCRIBING INFORMATION

This brief summary does not include all the information needed to use IYUZEH safely and effectively. See full prescribing information for IYUZEH.

Initial U.S. Approval: 2022

INDICATIONS AND USAGE

IYUZEH is a prostaglandin F2α analogue indicated for the reduction of elevated intraocular pressure in patients with open-angle glaucoma or ocular hypertension.

CONTRAINDICATIONS

Known hypersensitivity to latanoprost or any other ingredients in this product.

WARNINGS AND PRECAUTIONS

Pigmentation: Topical latanoprost ophthalmic products, including IYUZEH have been reported to cause changes to pigmented tissues. The most frequently reported changes have been increased pigmentation of the iris, periorbital tissue (eyelid), and eyelashes. Pigmentation is expected to increase as long as latanoprost is administered.

The pigmentation change is due to increased melanin content in the melanocytes rather than to an increase in the number of melanocytes. After discontinuation of latanoprost, pigmentation of the iris is likely to be permanent, while pigmentation of the periorbital tissue and eyelash changes have been reported to be reversible in some patients. Patients who receive treatment should be informed of the possibility of increased pigmentation. The long-term effects of increased pigmentation are not known.

Iris color change may not be noticeable for several months to years. Typically, the brown pigmentation around the pupil spreads concentrically towards the periphery of the iris and the entire iris or parts of the iris become more brownish. Neither nevi nor freckles of the iris appear to be affected by treatment. While treatment with IYUZEH can be continued in patients who develop noticeably increased iris pigmentation, these patients should be examined regularly.

Eyelash Changes: Latanoprost ophthalmic products, including IYUZEH may gradually change eyelashes and vellus hair in the treated eye; these changes include increased length, thickness, pigmentation, the number of lashes or hairs, and misdirected growth of eyelashes. Eyelash changes are usually reversible upon discontinuation of treatment.

Intraocular Inflammation: IYUZEH should be used with caution in patients with a history of intraocular inflammation (iritis/uveitis) and should generally not be used in patients with active intraocular inflammation because inflammation may be exacerbated.

Macular Edema: Macular edema, including cystoid macular edema, has been reported during treatment with latanoprost ophthalmic products, including IYUZEH. IYUZEH should be used with caution in aphakic patients, pseudophakic patients with a torn posterior lens capsule, or in patients with known risk factors for macular edema.

Herpetic Keratitis: Reactivation of herpes simplex keratitis has been reported during treatment with latanoprost. IYUZEH should be used with caution in patients with a history of herpetic keratitis and should be avoided in cases of active herpes simplex keratitis because inflammation may be exacerbated.

Contact Lens Use: Contact lenses should be removed prior to the administration of IYUZEH and may be reinserted 15 minutes after administration.

ADVERSE REACTIONS

The following adverse reactions have been reported with the use of topical latanoprost products and are discussed in greater detail in the prescribing information:

- Iris pigmentation changes
- Eyelid skin darkening
- Eyelash changes (increased length, thickness, pigmentation, and number of lashes)
- Intraocular inflammation (iritis/uveitis)
- Macular edema, including cystoid macular edema

Because clinical trials are conducted under widely varying conditions, adverse reaction rates observed in the clinical trials of a drug cannot be directly compared to rates in the clinical trials of another drug and may not reflect the rates observed in practice.

In the two clinical trials conducted with IYUZEH (latanoprost ophthalmic solution) 0.005% comparing it to XALATAN the preserved 0.005% latanoprost reference product, the most frequently reported ocular adverse reactions were conjunctival hyperemia and eye irritation (Table 1).

Table 1. Adverse Reactions

Symptom/Finding	Adverse Reactions [n (%)]	
	IYUZEH (n=378)	XALATAN (n=358)
Conjunctival hyperemia	129 (34)	133 (37)
Eye irritation	72 (19)	112 (31)
Eye pruritus	57 (15)	58 (16)
Abnormal sensation in eyes	51 (14)	52 (15)
Foreign body sensation in eyes	44 (12)	36 (10)
Vision blurred	28 (7)	30 (8)
Lacrimation increased	19 (5)	14 (4)
Photophobia	13 (3)	17 (5)

POSTMARKETING EXPERIENCE

The following adverse reactions have been identified during post-approval use of topical latanoprost products. Because these reactions are reported voluntarily from a population of uncertain size, it is not always possible to reliably estimate their frequency or establish a causal relationship to drug exposure. The reactions, which have been chosen for inclusion due to either their seriousness, frequency of reporting, possible causal connection to ophthalmic latanoprost products, or a combination of these factors, include:

- Nervous System Disorders: Dizziness; headache; toxic epidermal necrolysis
- Eye Disorders: Eyelash and vellus hair changes of the eyelid (increased length, thickness, pigmentation, and number of eyelashes); keratitis; corneal edema and erosions; intraocular inflammation (iritis/uveitis); macular edema, including cystoid macular edema; trichiasis; periorbital and lid changes resulting in deepening of the eyelid sulcus; iris cyst; eyelid skin darkening; localized skin reaction on the eyelids; conjunctivitis; pseudomphigoid of the ocular conjunctiva.
- Respiratory, Thoracic and Mediastinal Disorders: Asthma and exacerbation of asthma; dyspnea
- Skin and Subcutaneous Tissue Disorders: Pruritis
- Infections and Infestations: Herpes keratitis
- Cardiac Disorders: Angina; palpitations; angina unstable
- General Disorders and Administration Site Conditions: Chest pain

DRUG INTERACTIONS

The combined use of two or more prostaglandins, or prostaglandin analogs including IYUZEH is not recommended, and administration of these prostaglandin drug products more than once daily may decrease the IOP lowering effect or cause paradoxical IOP elevations.

USE IN SPECIFIC POPULATIONS

Pregnancy: There are no adequate and well-controlled studies of IYUZEH administration in pregnant women to inform drug-associated risks.

Lactation: It is not known whether this drug or its metabolites are excreted in human milk. Because many drugs are excreted in human milk, caution should be exercised when IYUZEH is administered to a nursing woman. The developmental and health benefits of breastfeeding should be considered along with the mother's clinical need for IYUZEH and any potential adverse effects on the breastfed child from IYUZEH.

Pediatric Use: The safety and effectiveness of IYUZEH have not been established in pediatric patients.

Geriatric Use: No overall differences in the safety or effectiveness of IYUZEH have been observed between elderly and younger adult patients.

OVERDOSAGE

Intravenous infusion of up to 3 mcg/kg of latanoprost in healthy volunteers produced mean plasma concentrations 200 times higher than during clinical treatment with latanoprost ophthalmic solution and no adverse reactions were observed. IV dosages of 5.5 to 10 mcg/kg caused abdominal pain, dizziness, fatigue, hot flushes, nausea, and sweating.

HANDLING THE CONTAINER

IYUZEH is a sterile solution that does not contain a preservative supplied in a single-dose container. The solution from one individual container is to be used immediately after opening for administration to one or both eyes. Since sterility cannot be maintained after the individual container is opened, the remaining contents should be discarded immediately after administration. Open a new single-dose container every time you use IYUZEH.

Manufactured for: Thea Pharma Inc. Waltham, MA.

All rights reserved.

U.S. Patent N°: 8,637,054.

Revised: 04/2023

©2021 Laboratoires Théa. All Rights Reserved. IYUZEH™ is a trademark of Laboratoires Théa.



BY PAUL M. KARPECKI, OD
CHIEF CLINICAL EDITOR

THROUGH MY EYES

Make Your Mark

There are several new options to manage retinal disease.

The world of retina care continues to move at a rapid rate; staying on top of these advances can enhance our ability to practice fully, provide vision, prevent blindness and give hope to those looking for the next potential treatment. I had the incredible experience of completing a preceptorship at Retina Associates of Kentucky and saw patients for more than three years, which provided much insight into optometry's current opportunity.

New Approaches to Wet AMD

Two key advances in drug therapy are Vabysmo (faricimab-svoa, Genentech) and Eylea HD (aflibercept, Regeneron Pharmaceuticals). The big advantage of these new drugs is that they require far less frequent injections. While the standard was to treat monthly and then extend the interval judiciously, many patients receiving Vabysmo or Eylea HD are down to about three injections per year.

Hope for GA

The new complement inhibitor intravitreal drugs—Syfovre (pegcetacoplan, Apellis) and Izervay (avacincaptad pegol, Iveric Bio)—are showing success in delaying progression of geographic atrophy (GA).

Before recommending a retina consult to consider these medications, first identify appropriate GA patients via OCT; the pattern to look for is that of a “barcode” hypertransmission through lost RPE. Once the “barcode” is identified, refer to a retina specialist. Autofluorescence, especially with technolo-

gies that better define the lesion, such as confocal retinal imaging using the Eidon TrueColor Widefield Confocal Scanner (iCare), can further refine ideal candidates. Patients whose GA spares the fovea are some of the best candidates, but keep in mind that this pattern will progress faster.

Next, discuss the “needle in the eye.” Although it sounds daunting, I tell patients that between eight and 10 million retinal injections are performed each year and, although there are risks (endophthalmitis, occlusive vasculitis), they are extremely low. Consequently, not treating GA will result in the inevitable progression to central vision loss.

I also explain how these drugs work. Injecting medications in the eye inhibits a key component in the inflammatory cascade leading to cell loss, thus slowing the progression of devitalized (damaged) RPE cells. This should maintain the vision they have for longer, but the great hope is in long-term therapy. Recent data suggests it may be possible that complement inhibitor drugs can further slow (and hopefully halt) the progression of healthy RPE cells from becoming devitalized and then eventually to atrophy.

Separate Yourself

Based on a great discussion with world-renowned retina specialist John Kitchens, MD, the following actions separate the top ODs in this field:

Contact the retina specialist early. Even if you are not sure if a referral is warranted, reach out to describe the patient's retinal findings to the specialist

and send imaging such as the OCT or retinal photography. If you believe the condition requires prompt scheduling, text the retina specialist. Certainly, some conditions, like a macula-on retinal detachment, require same-day scheduling, but others—like wet AMD—have more time (two weeks) with little consequence to visual outcome.

Make a follow-up appointment in your clinic, even if you are referring them; this way they stay in your system. These patients require regular exams, monitoring of the optic nerve for glaucoma, dry eye management and more.

“While the standard was to treat monthly and then extend the interval judiciously, many patients receiving Vabysmo or Eylea HA are down to about three injections per year.”

Treat the retinal conditions you can treat; refer the ones you can't. A good example is post-cataract cystoid macular edema. Prescribe Durezol (difluprednate ophthalmic emulsion 0.05%) QID and possibly a topical NSAID such as Prolensa (bromfenac ophthalmic solution 0.07%) QD for three weeks. At that point, if improvement is noted you can discontinue the NSAID but slowly taper the steroid to TID for two to three weeks, then BID for two to three weeks, and then QD for two to three weeks, all while regularly monitoring intraocular pressure.

No longer is this clinical acumen only valuable to the retina specialist. Without optometry's knowledge in this space, there would be a significant drop in patients being seen in retina practices, as well as a significant permanent vision loss in patients. ■

About
Dr. Karpecki

Dr. Karpecki is the director of Cornea and External Disease for Kentucky Eye Institute and an associate professor at KYCO. He is the Chief Clinical Editor for Review of Optometry and chair of the New Technologies & Treatments conferences. A fixture in optometric clinical education, he consults for a wide array of ophthalmic clients, including ones discussed in this article. Dr. Karpecki's full disclosure list can be found in the online version of this article at www.reviewofoptometry.com.



TRULY OBJECTIVE TONOMETRY WITH TONO-VERA® TONOMETER.

Introducing the all-new Reichert® **Tono-Vera®**, an innovative and thoughtfully designed handheld tonometer featuring the advanced, patented **ActiView™ Positioning System**, which quickly guides the you to the apex of the cornea and automatically measures when aligned. Tono-Vera provides more objective and repeatable results, giving you confidence in your IOP readings, all in a refined rebound tonometer experience.

LEARN MORE



AVAILABLE NOW: REICHERT.COM/TONOVERA
VISIT US AT AOA #1231!



passionate about eye care



Reichert
AMETEK

17.4
OD

18.1
OS

AUTO

X



Jot It All Down

Looking back at memories of family and patients is priceless.

I have been journaling since December 31, 2012. It started out every single day. After all, there is nothing more exciting than each and every day as an optometrist, right? Watching real-time broadcasts of local city council budget meetings may be the only equal.

Why, you may ask, did I start journaling? It's because I couldn't remember what Renee and I did on New Year's Eve 2011. Easy now... it's not what you think. I'll admit, there were various liquid refreshments that made me forget what I did on New Year's Eve from ages 18 through 27, but after achieving my Doctor of Optometry degree and getting engaged to the lady I call my first wife (still Renee since 1980, but who's counting?) I put on a white dress shirt and tie (that I borrowed from my younger brother since everything I owned was tie-dyed) and was suddenly sophisticated and in control.

I do remember one New Year's Eve since then. Renee and I had gone to bed and missed the New York City ball drop. She was very disappointed, which has been a theme with her since marrying me, I suspect. I took control and looked up the ball drop on the internet. We cheerfully counted down: "Three, two, one... HAPPY NEW YEAR 1993!"

Unfortunately, it was actually 1997, but I tried.

Why do I bring up my journaling and New Year's Eve experiences in the Spring of 2024? Because I wish my dad had journaled. Because even our little mundane and repetitive, "Which is better? Number one or number two?"

means so much to this lovely person in our chair that moment and we need to allow ourselves to look back and remember that day... this day... this patient.

Charting is our professional journaling, right? If you see somebody on June 3, 2021, you can glance at the chart for any important information. To me, the most important information on a patient's chart is stuff they told me about their kid playing baseball or that mom had a fall. That's right. I put that kind of stuff in their notes because I want them to know that I do see them as a person, not as a vision plan member.

Mostly this works out well when they come back the following year and say, "How did you remember that?" Nah. I don't tell them.

But these notes can get you in trouble when you ask about their ski trip last year and their seven-year-old broke his leg and now they tell you every moment of the whole trip in between, "Which is better?"

But, overall, more information is always better than less, which brings us back to journaling. Wonder what Dad was thinking out there in

the North Atlantic on his destroyer escort dodging torpedoes in World War II? Wonder what Mom was thinking when he came back and proposed?

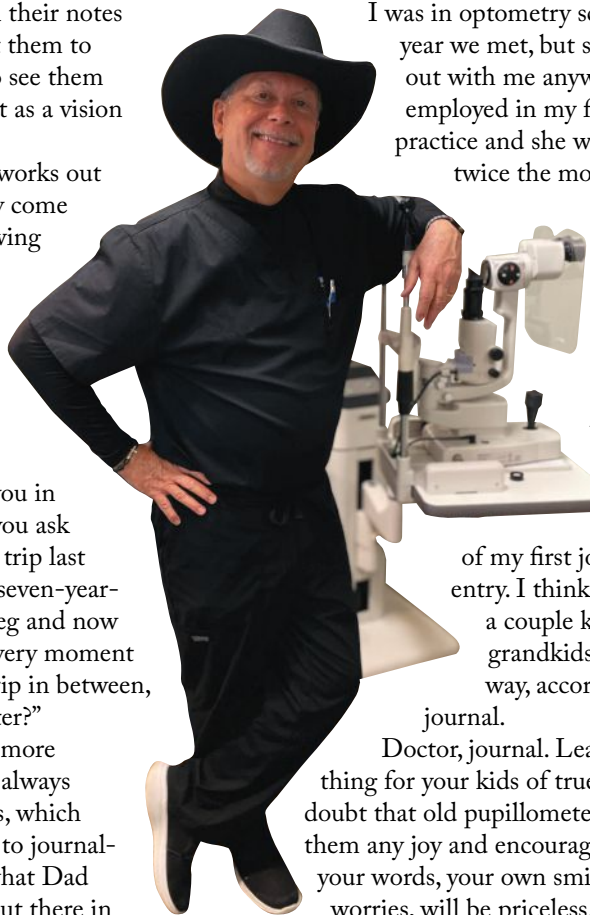
Wonder what I was thinking when I bet my girlfriend on Superbowl XIV and lost so I had to propose? Hey, I spotted Renee 14 points. That's love, y'all! Wonder what she was thinking when she said "OK?"

I don't need a journal that far back to clearly remember that the night I announced this to my parents and grandmother was the only time, up to that age, that I ate green beans I was so nervous. And I do remember the reaction. My mom looked ill (could have been the green beans) and my grandmother muttered, "Oh Law!"

I was in optometry school the year we met, but she went out with me anyway. I was employed in my first private practice and she was making twice the money working for IBM. After that, I don't remember anything until December 31, 2012, the day

of my first journal entry. I think there were a couple kids and grandkids along the way, according to the journal.

Doctor, journal. Leave something for your kids of true value. I doubt that old pupillometer will give them any joy and encouragement, but your words, your own smiles and worries, will be priceless. ■



About Dr. Vickers

Dr. Vickers received his optometry degree from the Pennsylvania College of Optometry in 1979 and was clinical director at Vision Associates in St. Albans, WV, for 36 years. He is now in private practice in Dallas, where he continues to practice full-scope optometry. He has no financial interests to disclose.

From the makers of the #1-prescribed dry eye brand in Europe*

Covering the spectrum of

Dry Eye Relief

Over-the-counter iVIZIA® lubricant eye drops protect the ocular surface and deliver a unique combination of immediate and long-lasting relief in a **preservative-free** formulation.

- A unique formulation—including povidone (active), trehalose (inactive), and hyaluronic acid (inactive)
- Proprietary, **multi-dose preservative-free (MDPF)** bottle

Chronic Dry Eye Patient Usage Study†:

Up to
8 hours
of relief

as well as improved comfort during computer work, reading, and driving¹

84%

of users reported iVIZIA worked better than their previous eye drops¹



Safe for use with contact lenses‡



Scan here.

Recommend iVIZIA and request samples by visiting [iVIZIA.com/ECP](https://www.ivizia.com/ECP)

*Prescription market data, Dec. 2022 – S01K without cyclosporine.

¹In a chronic dry eye patient usage study, participants from a variety of socioeconomic backgrounds answered questions about their experience with iVIZIA lubricant drops. In the study, 203 chronic dry eye patients, 28-80 years old, switched from their dry eye artificial tears to iVIZIA for a month.¹

[‡]To limit blurriness when using contact lenses, remove contacts, apply drops, then insert contacts.

Reference: 1. Thea Data on File.

Copyright ©2024 Thea Pharma Inc. | All Rights Reserved. | PRC-IED-1030-v4 1.2024





BY PAMELA H. SCHNELL, OD, AND MARC B. TAUB, OD, MS, EdD

FOCUS ON REFRACTION

It's Time for a Clip Show!

Celebrate our halfway point to 100 published columns with some of the highlights.

In all the excitement of writing the last column for Focus on Refraction, it somehow slipped by us that it was the 50th! When I (Dr. Taub) was originally approached by the editors to help identify authors for a new column that focused on refraction and prescribing, I immediately raised my hand for the assignment and drafted Dr. Paul Harris as a partner in crime. We wrote together, typically taking turns in writing and editing, for seven years. Once he stepped away, I found a new writing partner in Dr. Pam Schnell, and we have been at it for another two and a half years. We have covered a spectrum of topics and tools that we use to help in prescribing decisions and have even waxed the philosophical (just a bit).

For our 51st column, we wanted to do a “clip show” and highlight some of the past 50 columns as a refresher for those of you who might have missed them. They are all available on the *Review of Optometry* website, so you can dig in at your leisure. Here's a key point or two from each.

Buff up Your Buffers (Dec. 2020)

There are two important buffers the body has implemented in the visual system to help reduce the impacts of stress: low hyperopia and low exophoria. In prescribing, especially for school-aged children, keeping the two values of +0.50D and four exophoria

in your consciousness is quite crucial. Similar to overdraft protection for your bank account as a buffer from overspending, keeping enough plus and exophoria helps from overtaxing the visual system. Accidentally over-minusing in search of that extra line of visual acuity or pushing plus on a hyperope are obvious ways to blow out your buffers.

Prescribing for Young Children (April 2020)

Just because you measure something does not mean that you need to take action. Vision changes in children over time and can do so significantly in the first few years of life. Prescribing early can interfere with natural develop-


ment and emmetropization. Every optometrist has a comfort level in their prescribing that is based on their experience in patient care. Presented in this column is research from a group of optometrists who practice following the developmental/behavioral model. The takeaway is that as patients increase in age from three months to seven years, doctors become more proactive in prescribing.

Take it to the Limit (Dec. 2017)

As mentioned above, over-minusing is common and can damage visual development. While we are often proud that the patient can see the 20/15 line with each eye, how many extra clicks were needed to attain that visual acuity? Giving too much minus can also cause trouble with binocular vision/accommodation. Please keep in mind the impact of your prescribing.

Addition by Subtraction: Cutting the Cyl (Dec. 2022)

We have all had patients who show small amounts of cylinder at axis 90 or 180, and we often prescribe it without hesitation. What if we didn't?



Simulation of significant cylindrical blur.

About Drs. Taub and Schnell

Dr. Taub is a professor and co-supervisor of the Vision Therapy and Pediatrics residency at Southern College of Optometry (SCO) in Memphis. He specializes in vision therapy, pediatrics and brain injury. **Dr. Schnell** is a professor at SCO and teaches courses on ocular motility and vision therapy. She works in the pediatric and vision therapy clinics and is co-supervisor of the Vision Therapy and Pediatrics residency. Her clinical interests include infant and toddler eye care, vision therapy, visual development and the treatment and management of special populations. They have no financial interests to disclose.

Photo: Philip Trumble, Southern College of Optometry

We have found that eliminating the small cyl and providing the spherical equivalent does not change the visual acuity. Prescribing the cyl can embed it, making it harder to remove from future prescriptions and condemning the child to a lifetime of astigmatism when it could have been avoided.

Make Way for Yoked Prism (April 2021)

Prism seems to scare the heck out of many doctors. They run from it and crawl into the fetal position at the thought. Well, what if we told you that prism prescribed with both bases in the same direction can be used therapeutically to influence visual and body posture and behavior? We have successfully used yoked prism for patients with brain injury, special needs and even strabismus. The changes are typically immediate, impactful and force the patient to adapt to the altered visual input.

Double the Glasses, Double the Success (Feb. 2022)

Some of the most challenging patients to work with are those who have suffered a brain injury. They can complain of photosensitivity, visual field loss and trouble seeing out of their glasses. Brain-injured patients often have trouble with fine eye movements, which can include putting their eyes in the appropriate locations to see out of the various aspects of their lenses. Given that this population often uses bifocals or progressive addition lenses, one of the easiest ways to alleviate symptoms is to provide the patient with separate glasses for distance and near.

Fresnel Prism to the Rescue (April 2018)

Diplopia is a common complaint for patients with brain injury secondary to trauma or stroke. It can be challenging to manage due to the spectrum of reasons for the diplopia and the progression of improvement. Fresnel prism can be used for short-term alleviation of the condition. It has the benefit of being able to be changed frequently



A variety of tints from the Chadwick Optical ABI flipper set and the Bowan grating card.

and easily, in contrast to ground-in prism, as the magnitude of the prism hopefully decreases. Fresnel prism can also be used in a leapfrogging manner therapeutically.

Low-Tech TBI Rehabilitation (April 2017)

Patients who have suffered brain injuries often have issues with focusing. We have heard this described in so many ways, from “something just does not feel right” to “the words keep moving” to “I can’t concentrate on reading.” In these cases, we break out the “magic tape” and apply binasal occlusion to the patient’s glasses. Of course it isn’t magic, but when it works, it certainly can seem like it to the patient.

While there are many theories why binasal occlusion works, we subscribe to the concept that for these patients, there is just too much visual noise, as there is a duplication of information in the center due to the overlapping visual fields. Binasal occlusion simply reduces the amount of visual input, allowing the patient to deal with less throughout the healing process.

Little Occlusion Goes a Long Way (Dec. 2016)

The type of occlusion that we highlighted in this column is different than the binasal occlusion mentioned above. Spot or strip occlusion is sometimes the only treatment option when a

brain-injured patient cannot put two images together; their brains are just not ready for that challenge. This first step is temporary and allows for the patient to have improved function in other therapies, as well as in navigating their environment. Generally, within a few weeks, we can transition to Fresnel prism.

Looking Through Rose-Colored Glasses (Feb. 2023)

Photosensitivity can be life-changing. Can you imagine the constant pain from not only light outside but also from the lights that hang in almost any public venue? Using custom tints with saturations that range from light blockage (15%) to dark (60% to 80% blockage), we have the power to give patients their freedom back. The most common colors that we employ are a yellow-orange (FL-41) and blue. The changes in visual comfort are immediate and can even help patients with migraines in which light is a trigger.

Visuoscopia Review (Aug. 2023)

Over the years, we have discussed a variety of exam techniques to aid in the diagnostic process. Visuoscopia takes about 30 seconds and provides insight into fixation ability and why your patient might not be capable of seeing 20/20. Knowing whether fixation is decentered or unsteady helps in the treatment decision-making tree and provides insight that you would not otherwise have gotten through your normal exam routine.

Aiming for 100

Dr. Taub’s grandfather, when asked how he was doing, used to respond that “the first 100 years are the hardest.” Well, we can say that the first 50 columns were honestly not the hardest, but exactly the opposite; we had so much fun writing them! They represent our philosophy regarding the visual process and how we practice, and we have been honored to share them with you all—or “y’all” if you live in the South like we do! We look forward to the next 49 on our way to 100! ■



EDITED BY PAUL C. AJAMIAN, OD

CLINICAL QUANDARIES

Fade to Black

Be aware of the ups and downs of blood pressure in cataract patients in case this situation occurs.

Q I have seen several post-op cataract patients who complain of blacking out of vision when going from a sitting to standing position. The eye looks fine. What is going on?

A “Intraocular pressure (IOP) change after cataract surgery is a commonly seen postoperative complication that can manifest in several different ways,” says Himakshi Bhatt, OD, of Ophthalmic Consultants of Connecticut in Fairfield, CT. “Fortunately, these events can be easily handled in office by any comanaging doctor.”

Elevated IOP the day after surgery is often caused by residual viscoelastic in the trabecular meshwork. Corneal signs include microcystic epithelial edema and stromal folds. If IOP is lower than average, note anterior chamber depth and check for a seidel at the incision sites. Patients are often asymptomatic with low IOPs or if IOPs have increased into the 20s. However, once pressure starts creeping into the 30s and 40s, patients may start complaining of headaches and eye aches, as well as blurred or hazy vision.

Infrequently, patients may complain of blacking out of vision in the surgical eye, as described by this patient. This interesting finding is most likely related to perfusion pressure at the optic nerve head. Dr. Bhatt had two similar cases recently. Both patients were women in their 50s with low blood pressures and elevated IOPs. One woman had pressures in the high 30s and the other in the mid 20s. They experienced momentary blacking out of

vision in the operative eye when going from a sitting to a standing position. All slit lamp and dilated fundus exam findings were unremarkable besides the elevated IOP. In both cases, symptoms completely resolved once IOPs reached a normotensive level.

A Rush of Blood


To understand the mechanism of action for this unique surgical complication, it is important to review optic nerve head blood supply and vasculature. The optic nerve head is supplied by the posterior ciliary arteries, which branch from the ophthalmic artery.¹ Blood returns from the nerve head and peripapillary region via the central retinal vein.¹ Ocular perfusion pressure (OPP) is the difference between arterial and venous blood pressure and is the pressure at which blood enters the eye.^{1,2} Arterial pressure pushes blood into the eye while IOP pushes blood

out. The balance between these two determines blood supply and oxygen delivery to the optic nerve and retinal ganglion cells. OPP is low when systemic blood pressure is low, when IOP is high or both.^{2,3}

Blood supply to cerebral structures can be affected by positional changes. When going from sitting or supine to standing, there is a sudden reduction in arterial blood pressure, as body fluid pools in the legs and lower body.⁴ This momentary and sudden drop in blood flow to the head is highlighted in patients with orthostatic hypotension or orthostatic intolerance.⁴ Women may be more prone to the effects of this postural change vs. men.⁴

“Adding together the patients’ low blood pressure and reduced blood supply caused by a positional change, along with an increased IOP, it creates the perfect storm for reduced ocular perfusion, and therefore transient vision loss as seen in the cases described above,” Dr. Bhatt says. “When IOP returns to normal levels, this balance is restored and the vision change is resolved. A proper work-up should be performed for any patient complaining of repeated temporary vision loss, or amaurosis fugax.”

“Elevated IOP is an easily managed complication after cataract surgery, but may present in more than just one way,” she emphasizes. “Take care of IOP in the 30s with drops and 40s by burping the wound. Then, make sure you measure their blood pressure.” ■



Transient post-surgical elevated IOP can be easily managed with topical hypotensive therapy.

1. Mackenzie PJ, Cioffi GA. Vascular anatomy of the optic nerve head. *Can J Ophthalmol.* 2008;43(3):308-12.

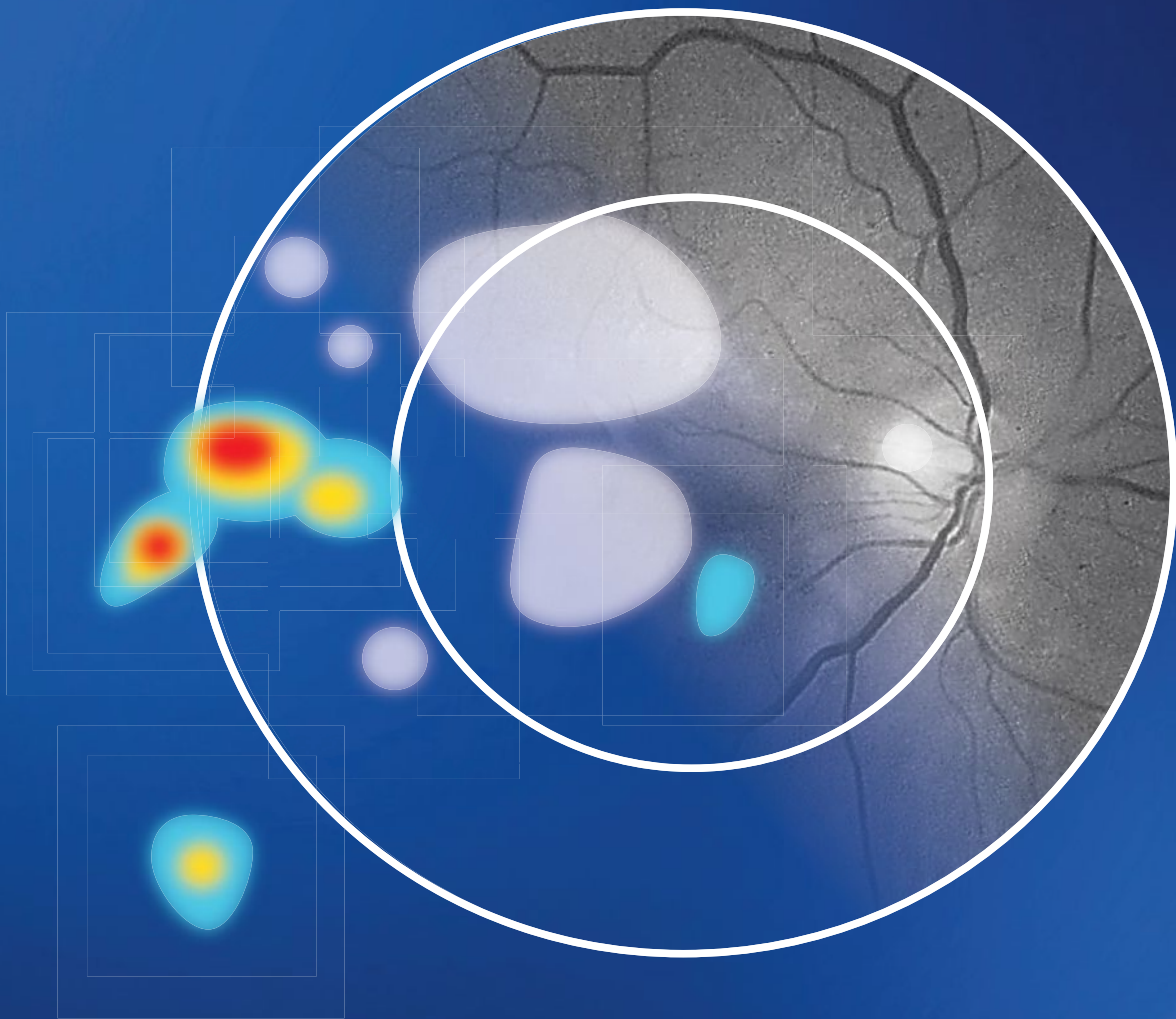
2. Cherecheanu AP, Garhofer G, Schmidl D, et al. Ocular perfusion pressure and ocular blood flow in glaucoma. *Curr Opin Pharmacol.* 2013;13(1):36-42.

3. Kim KE, Oh S, Baek SU, et al. Ocular perfusion pressure and the risk of open-angle glaucoma: systematic review and meta-analysis. *Sci Rep.* 2020;10(1):10056.

4. Patel K, Rössler A, Lackner HK, et al. Effect of postural changes on cardiovascular parameters across gender. *Medicine (Baltimore).* 2016;95(28):e4149.

About
Dr. Ajamian

Dr. Ajamian is board certified by the American Board of Optometry and serves as Center Director of Omni Eye Services of Atlanta. He is vice president of the Georgia State Board of Optometry and general CE chairman of SECO International. He has no financial interests to disclose.



Modern Management of Geographic Atrophy in Optometry

Miguel A. Busquets, MD, FACS, FASRS
Retina Associates of Kentucky

Carolyn Majcher, OD, FAAO
Oklahoma College of Optometry at Northeastern State University

Mary Anne C. Murphy, OD
Front Range Eye Associates

Sponsored by Apellis Pharmaceuticals Inc and Carl Zeiss Meditec USA, Inc.

Modern Management of Geographic Atrophy in Optometry

Geographic atrophy (GA) is an advanced form of age-related macular degeneration (AMD), a leading cause of significant vision loss worldwide. It is defined by atrophic lesions, resulting from loss of photoreceptors, retinal pigment epithelium (RPE), and underlying choriocapillaris.^{1,2}

- It currently affects about 1 million people in the United States³
- Prevalence of GA and neovascular age-related macular degeneration (nAMD) in the US are ~973,000 and ~1.2 million, respectively³

In this new era in which there are more options for patients with GA, collaborative care between optometrists, comprehensive ophthalmologists, and retina specialists is more important than ever. Indeed, shared care is a growing imperative that is necessary to ensure that patients receive proper treatment, as well as emotional support. Because this is a new model, the paradigm is evolving in real time, but one thing is certain: it requires trust and effective communication that includes a common clinical vocabulary. As life expectancy rises, eye care professionals are anticipated to encounter an increasing number of patients with GA in the future.^{4,6} Consequently, there is a crucial need for the accurate identification of disease, timely referral, and ongoing monitoring of these patients.⁷

Optometrists play a pivotal role in identifying and referring individuals with GA, and collaborating with other eye care providers to enhance overall patient care.^{8,9} By working together as a team, we aspire to enhance the overall experience for patients grappling with this debilitating and life-changing disease. Here, we outline unmet needs and describe best practices for identifying and referring GA patients.

GA Basics

GA and neovascular age-related macular degeneration (nAMD) represent distinct forms of advanced AMD. Neovascular AMD involves disruption of the outer blood/retinal barrier that results in exudation, which can be reversed with current anti-VEGF treatments. In contrast, GA is defined by age-related tissue atrophy and irreversible vision loss.¹⁰⁻¹² It's noteworthy that individuals with GA can progress to develop nAMD, and vice versa.^{2,10}

Although some clinicians perceive GA progression as slow, it is typically continuous and invariably irreversible.^{11,13}

Indeed, GA may progress more rapidly than previously thought.¹⁴ The rate of progression is variable, with some experiencing more rapid deterioration leading to vision loss and a decrease in quality of life.^{1,5} The prospective AREDS study involving 3640 participants revealed that among the 397 patients who developed central GA, the median time from initial GA diagnosis to foveal involvement was just 2.5 years from the time of diagnosis.¹⁵

GA Symptoms

Patients with GA may experience one or more of these symptoms.^{7,16}

- Straight lines that appear crooked
- Hazy or blurred vision
- Blurry spot in the center of vision
- Dull or washed-out colors
- Difficulty seeing in low light
- Missing spots in vision

Unmet Needs

AMD needs to be diagnosed as early as possible. When disease remains undiagnosed, patients cannot benefit from proper care.^{5,14} Unfortunately, studies indicate that AMD might be overlooked in older adults. In research involving 644 patients ages 60 and older undergoing a comprehensive eye examination with dilation in a primary eye care setting, it was discovered that 25% of eyes initially categorized as "normal" exhibited macular changes typical of AMD, as per a clinical classification staging system, putting these eyes at risk for progression to GA.¹⁷ In such cases, at the time of GA diagnosis, substantial atrophy has already occurred.

This underscores the importance of early identification of susceptible patients and factors contributing to progression.⁵

For patients at high risk of GA development, more frequent monitoring may be beneficial. Increasing confidence in the ability to identify the disease, utilize multimodal imaging to accurately diagnose GA, and make timely referrals for retinal evaluations when needed is crucial.^{8,9,13}

Complement overactivation may lead to excess phagocytosis, inflammation, and cell lysis, culminating in retinal cell damage in GA^{11,18}

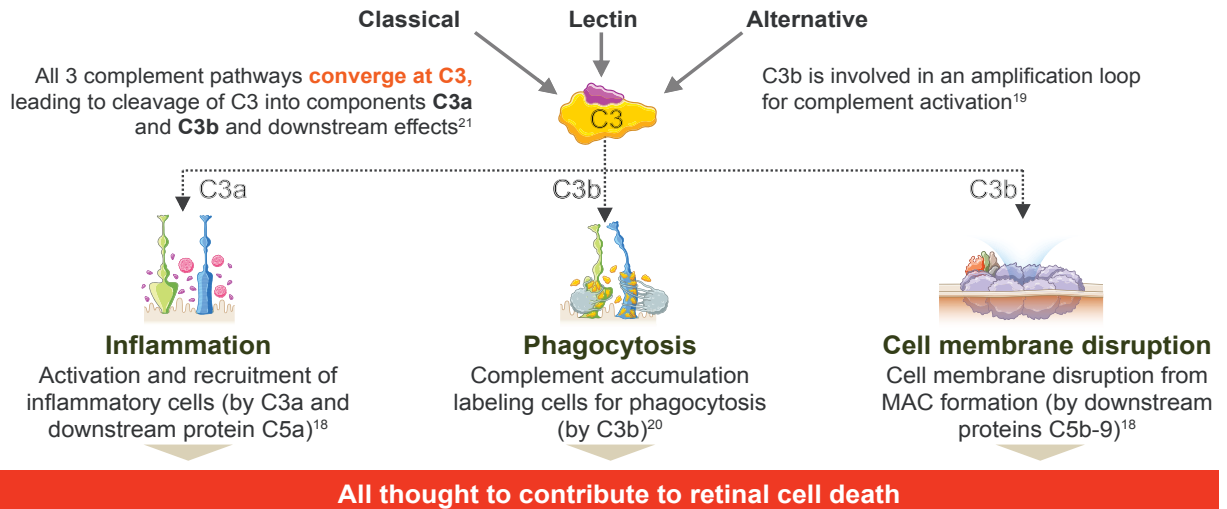


Image does not reflect all proteins involved in the complement cascade.

MAC=membrane attack complex.

Risk Factors for the Development of GA

- **Genetics:** Family history (genetic predisposition)²²
- **Physiology:** Age, Obesity, Certain dyslipidemias, Cardiovascular disease/hypertension²²
- **Lifestyle/Environment:** History of smoking, Diet²²
- **Clinical Findings from Imaging:** GA in fellow eye, Increased drusen volume^{1,23}



IMPACT:

GA progression is relentless and irreversible.^{11,13} From age 50, the prevalence of GA quadruples every 10 years.⁶

2.5 years: Median time to foveal encroachment from diagnosis.¹⁵ Early recognition of the signs and symptoms of GA and referral for retinal evaluation prior to irreversible central vision loss is critical.

Approximately 1 million people in the US are affected by GA.³

In a retrospective study (n=523), 2 out of 3 patients with bilateral GA who were eligible to drive at baseline lost that ability in a median time of <2 years from the earliest record indicating diagnosis of GA.²⁴

In the 2021 global Geographic Atrophy Insights Survey (GAINS) (N=203), conducted by The Harris Poll and sponsored by Apellis Pharmaceuticals²⁵:

People living with GA report feeling



ANXIOUS



POWERLESS



FRUSTRATED



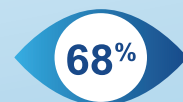76% of people living with GA agree that prior to their diagnosis, they attributed their vision loss to a natural part of aging



86% wish there were more educational materials available for patients and caregivers



83% at the time of diagnosis wish they understood the irreversible impact GA would have on their vision



68% agree the impact of vision decline on QOL and independence is worse than they expected



91% want more information and options about GA to feel empowered to take control of their disease



90% of those who have difficulty recognizing faces feel frustrated when they cannot recognize the faces of friends or family

Patient Impact

It is critical to recognize GA and refer patients in a timely manner, as disease progression is relentless and irreversible. Moreover, GA can impact patients more rapidly than anticipated.^{11,25-27} Even in the early stages of GA, many patients contend with substantial challenges, including reading difficulties, the inability to drive, diminished health-related quality of life, and mental health issues such as depression.¹⁷

The Geographic Atrophy Insights Survey (GAINS)* study reveals the diverse ways in which patients are affected, underscoring the considerable burden of GA on their ability to perform daily activities.²⁵ Many patients experienced the impact of GA in less than 2 years. A significant UK retrospective study with bilateral GA patients revealed that

two-thirds of those eligible to drive at baseline lost that ability within a median time of <2 years (n=523).²⁴ According to a qualitative study in the United States (n=8), 63% of GA patients face difficulty reading for everyday tasks or leisure, representing a substantial challenge.²⁸ † Some individuals opt to drive only under specific conditions, while others abandon driving altogether, resulting in a notable loss of independence. Public transportation is not always a viable alternative, particularly for patients with impaired vision. Moreover, patients miss out on leisure activities they once enjoyed, like reading books and traveling. Patients who have GA often exhibit a significant emotional impact, marked by fear of the future and mourning for what they have lost. The shift from independence to reliance on others for assistance contributes to feelings of sadness and withdrawal.²⁵

* The global GAINS study was sponsored by Apellis Pharmaceuticals and conducted by The Harris Poll between October 12 and December 10, 2021. To accommodate visually impaired respondents, the survey was conducted online and via the telephone among 203 participants aged 60 or over (mean age, 70 years) residing in the United States, United Kingdom, France, Germany, Italy, the Netherlands, Sweden, Canada, and Australia, who self-reported that they have been diagnosed with AMD and have dry AMD in at least one of their eyes. They must also have indicated that they have advanced atrophic age-related macular degeneration, or advanced atrophic AMD, advanced/late/late-stage dry age-related macular degeneration, or advanced dry AMD, or GA in one or both of their eyes. Included patients must have been currently experiencing at least 3 GA symptoms and currently do/used to do/have been suggested by an eye care professional but have not done at least one of the following: take a high-dose formulation of antioxidant vitamins and minerals, stop smoking, maintain a healthy weight and exercise regularly, choose a healthy diet, manage other medical conditions, have check-ups of the retina regularly, or wear sunglasses with ultraviolet protection. Included patients must not have been diagnosed with glaucoma, Stargardt disease, or dementia, or be receiving regular injections into the affected eye every 4 to 6 weeks.²⁵

† A cross-sectional qualitative study of patients with symptomatic GA, their caregivers, and eye care professionals who treat patients with GA (N=19) who were interviewed at United States sites to evaluate understanding of the disease, costs and burden of illness, use of vision aids or services, and impact on emotional or psychological well-being and on daily activities.²⁸

Identifying GA

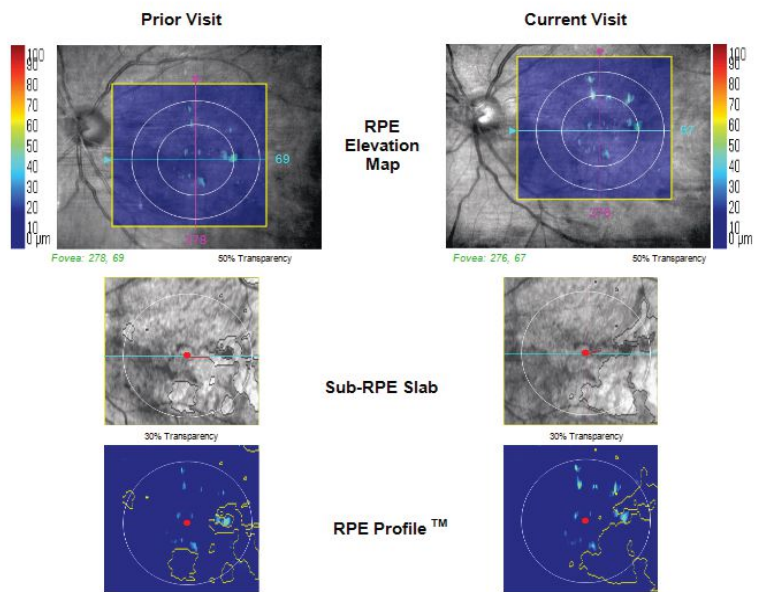
The ZEISS CIRRUS OCT offers an Advanced RPE Analysis designed to assist clinicians in managing various forms of non-exudative AMD. This analysis combines two algorithms, namely the RPE Elevation Map for assessing drusen burden and the Sub-RPE Slab for measuring GA. By reprocessing data from standard macular cube scans (512x128 or 200x200), the Advanced RPE Analysis delivers reproducible and quantifiable OCT-based measurements of drusen and GA burden. These algorithms can be applied to any macular cube scan, regardless of when it was conducted, and the results can be exported as individualized reports.

Drusen Detection

The RPE Elevation Map is an OCT-based method for identifying soft-type drusen, measuring drusen area, and assessing drusen volume. Any RPE elevation exceeding 19.4µm is automatically identified and included in the analysis. Evaluation of RPE elevations, acting as an OCT surrogate for soft drusen, can be done qualitatively using the color-coded RPE Elevation Map or quantitatively through calculated metrics. The color-coded RPE Elevation Map, displayed as a transparent overlay on the fundus image, aids in correlating with clinical examination. Measurements of RPE elevation area and volume can be conducted within a 3mm or 5mm diameter circle centered on the fovea. When interpreting the RPE Elevation Map, it is important to recognize that lesions other than just soft drusen may be included in the analysis such as neovascular or serous containing pigmented epithelial detachments.

While OCT-based drusen detection complements ophthalmoscopic or color fundus photographic methods, it is not equivalent. Ophthalmoscopy and color fundus photography help identify pigmentary changes associated with drusen, whereas the

Advanced RPE Analysis : Macular Cube 512x128 OD OS



*The calculated difference does not consider test-retest variability.

RPE Elevations	Prior	Current	Difference*	% Change
Area in 3 mm Circle (mm ²)	0.3	0.3	0.0	0.0%
Area in 5 mm Circle (mm ²)	0.4	0.6	0.2	50.0%
Volume in 3 mm Circle (mm ³)	0.01	0.01	0.00	0.0%
Volume in 5 mm Circle (mm ³)	0.01	0.02	0.01	100.0%
Sub-RPE Illumination	Prior	Current	Difference*	% Change
Area in 5 mm Circle (mm ²)	3.1	4.9	1.8	58.1%
Closest distance to Fovea (mm)	0.8	0.5	-0.3	-37.5%

Advanced RPE Analysis detects RPE elevations corresponding to soft drusen. In managing non-neovascular AMD, ongoing monitoring for disease progression is crucial. The RPE Elevation Map offers an automatic, reproducible, and objective approach for monitoring drusen progression or regression. Changes in RPE elevation are quantified within 3mm and 5mm circles centered on the fovea, with automatically calculated metrics comparing the present examination to a previous one for both RPE elevation area and volume differences.

AMD Finding	Description
Geographic Atrophy	Clinical term used to denote areas of retinal and RE atrophy without the presence of present/past CNV
iRORA	Vertically aligned photoreceptor/outer retinal degeneration, RE attenuation or disruption, and increased signal transmission into the choroid Must not qualify as cRORA
cRORA	Vertically aligned zone of hypertransmission of ≥250 µm, zone of attenuation or disruption of RPE band of ≥250 Mm, and evidence of overlying photoreceptor degeneration whose features include ONL thinning, ELM loss, and EZ and IZ loss Must exclude scrolled RPE or other signs of RPE tear

RPE: retinal pigment epithelium; iRORA: incomplete RPE and retinal atrophy; cRORA: complete RPE and retinal atrophy; ONL: outer nuclear layer; ELM: external limiting membrane; EZ: ellipsoid zone; IZ: interdigitation zone; CV: choroidal neovascularization

Geographic Atrophy Detection

The Sub-RPE Slab, an exclusive ZEISS CIRRUS algorithm, is designed to identify areas of RPE thinning or atrophy. As the RPE thins and eventually atrophies in GA, the underlying choroid becomes hyper-illuminated and is more visible on OCT scans. Leveraging this OCT phenomenon, the Sub-RPE Slab quantifies regions of choroidal hypertransmission and RPE atrophy, serving as an OCT-based surrogate for GA. Qualitatively, the Sub-RPE Slab can be visualized as an enface overlay, while quantitatively, it provides an area summation within a 5mm circle centered on the fovea. The Advanced RPE Analysis automatically identifies the fovea and calculates the shortest distance between any area of sub-RPE illumination and the fovea.

While short-wavelength fundus autofluorescence (FAF) has traditionally been the preferred imaging method for monitoring GA enlargement, OCT is emerging as a modern diagnostic tool. In contrast to FAF, the Advanced RPE Analysis offers automated and objective comparisons against baseline scans, facilitating the detection of GA progression. The progression analytics enable the identification of any increase in GA and its encroachment toward the fovea.

The Geographic Atrophy Paradigm Shift

GA was a term traditionally used in funduscopy or color fundus photography to indicate areas of atrophy of the photoreceptors, choriocapillaris, and RPE. The Classification of Atrophy Meetings (CAM) group has introduced a new global consensus classification system for atrophy secondary to AMD. The term Complete RPE and Retinal Atrophy (cRORA) is an OCT-based definition, approximately synonymous with clinical GA in older classification systems (refer to Table 1).²⁹ When observed with OCT, the RPE will show signs of attenuation, disruption, or absence, accompanied by degeneration of the outer retina above. The choroid becomes hyper-reflective and is more clearly visible due to the absence of the RPE's masking effect, which typically absorbs much of the OCT signal. Incomplete RPE and retinal atrophy (iRORA) precedes cRORA.³⁰

Our evolved understanding of GA is transforming diagnosis and monitoring into a more comprehensive strategy. This emerging GA paradigm mandates precise diagnosis based on OCT findings as outlined by the CAM group, followed by thorough monitoring of the disease progression using OCT and clinical evaluation.

Tools like progression analytics, featured in the Advanced RPE Analysis, will play a crucial role in assessing patients. These analytics can also serve as a powerful educational resource and can be used to enlighten patients regarding their personal GA progression rates. Through the Advanced RPE Analysis, clinicians can visually depict the natural disease progression throughout the entire patient journey.

Implementing Advanced RPE Analysis

The Advanced RPE Analysis functions as an algorithm, not a specific scan protocol, and is applicable to any macular cube scan. Following the completion of a macular cube scan, whether 512x128 or 200x200, users can select the Advanced RPE Analysis in the top right-hand corner (refer to Figure 1). This analysis is versatile, suitable for any non-neovascular AMD manifestation, making it essential for scans displaying dry AMD signs. In cases of early or intermediate dry AMD, the RPE Elevation Map is effective for detecting and monitoring macular soft drusen burden. For late non-neovascular AMD, the Sub-RPE Slab can identify areas of GA, assessing progression or encroachment onto the fovea. After applying the Advanced RPE Analysis to a macular cube scan, the analysis can be saved as a standalone report and exported to the patient chart.

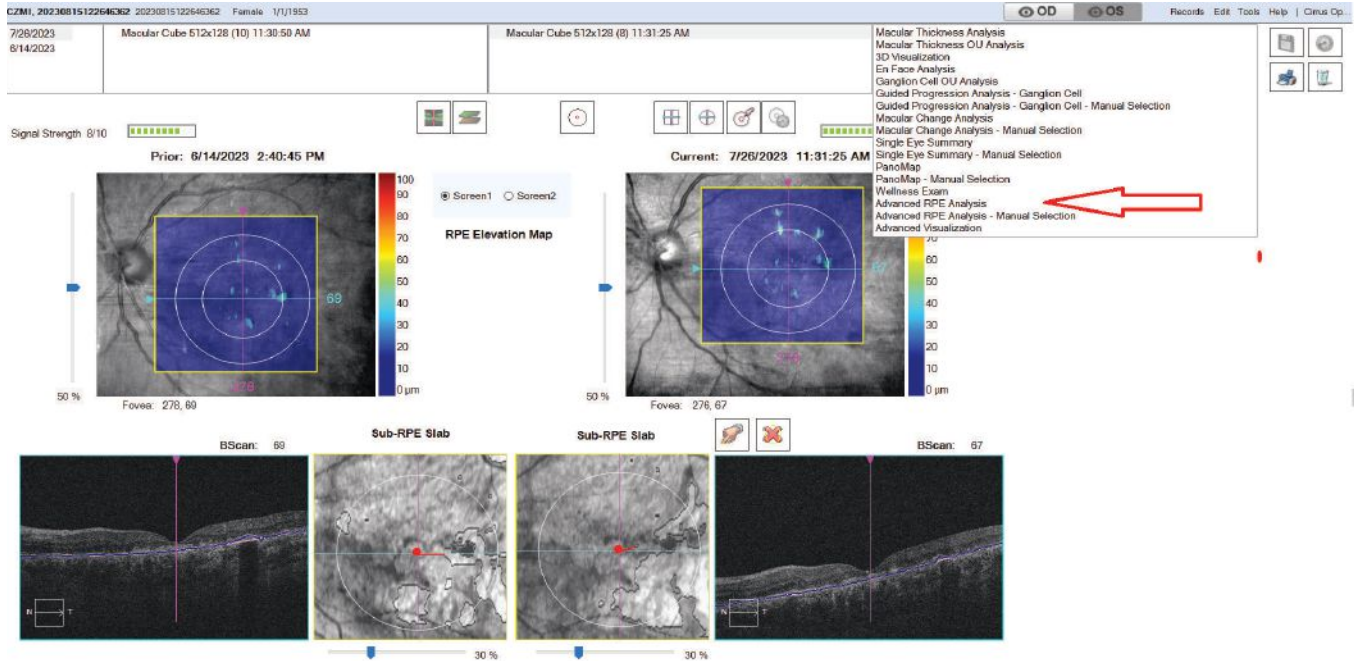
While the ZEISS CIRRUS OCT has long been recognized for managing neovascular AMD, the often-overlooked Advanced RPE Analysis offers a comprehensive approach to OCT-based drusen and GA management. ZEISS has integrated macular cube scans, high-definition raster scans, progression analyses, and the Advanced RPE Analysis into the CIRRUS OCT, creating a comprehensive suite of tools for effectively managing all forms of non-neovascular AMD.

AMD Classification Language

Collaborative efforts between optometrists and ophthalmologists, using a shared language and imaging data, will be essential in achieving the common goal of providing vision-saving care. The ZEISS CIRRUS OCT, equipped with its Advanced RPE Analysis and AngioPlex[®], stands as a foundational tool for both optometrists and ophthalmologists to detect and monitor all forms of AMD.

There are two commonly employed classification systems for AMD in clinical practice—the classic AREDS system and the newer Beckman Committee criteria. These systems, while similar, are not interchangeable and aid eyecare providers in appropriately staging AMD patients. To ensure accurate and effective collaborative care, it's crucial for optometrists and ophthalmologists to use the same grading system.

The ZEISS CIRRUS OCT features the Advanced RPE Analysis, designed to assist clinicians in managing non-neovascular AMD at various stages, including early, intermediate, and late AMD. The RPE Elevation Map measures soft drusen burden, while the Sub-RPE Slab detects and quantifies GA. As patients progress through AMD stages, the Advanced RPE Analysis provides an objective means to quantify drusen and GA progression. Proper AMD classification and objective OCT-based detection enhance the comanagement relationship between optometry and ophthalmology, enabling each provider to optimize their practice scope.



With the emergence of GA therapies, it becomes essential to ensure early identification of GA in patients with AMD, timely and appropriate referral to a retina specialist or injecting ophthalmologist, and initiation of treatment when necessary. Keeping up with the latest nomenclature is essential for optometrists and ophthalmologists to establish proper referral patterns and management protocols.

The Patient Journey

For a long time, optometrists and general ophthalmologists would monitor dry AMD patients for neovascularization and/or exudation features and when discovered refer them to a retinal specialist for consideration of anti-VEGF treatment. However, the AMD patient's journey has evolved and there is now a heightened importance of accurate diagnostics. Accordingly, an influx of AMD patients to optometrists, general ophthalmologists, and retinal specialists is anticipated. A collaborative eyecare model among these professionals will be increasingly vital to ensure prompt intervention for the patients who need it.

Leveraging OCT-based definitions established by the Classification of Atrophy Meetings group and OCT-based analyses like the Advanced RPE Analysis will facilitate communication and seamless transitions between optometrists and treating ophthalmologists or retina specialists. Initial assessments for GA patients may involve ophthalmoscopy, later confirmed with OCT. Standardized OCT criteria, such as complete RPE and outer retinal atrophy (cRORA) and incomplete RPE and outer retinal atrophy (iRORA), will help guide the decision for referral. The

Sub-RPE Slab can detect criteria for GA referral. These criteria may include GA distance from the fovea, overall GA area, or the rate of GA progression, all objectively and automatically calculated using the Advanced RPE Analysis.

When a candidate with GA is identified, referral to a treating eyecare professional for potential treatment is considered. The Advanced RPE Analysis aids in monitoring treatment effects through the progression analysis report. Given the higher risk of neovascular AMD development in patients undergoing GA treatment with complement inhibition, diligent monitoring and screening for neovascular AMD is crucial. OCT angiography (OCTA) systems like the ZEISS CIRRUS AngioPlex gain significance, enabling noninvasive screening for neovascular AMD. Ideally, OCTA allows doctors to detect nonexudative neovascular AMD before substantial vision loss occurs.

Collaborative Care

Collaboration between optometry and ophthalmology can ultimately result in improved patient outcomes. The ZEISS CIRRUS OCT plays a pivotal role in supporting this collaborative relationship by offering objective and reproducible dry AMD imaging through the Advanced RPE Analysis and neovascularization detection with AngioPlex. This advanced technology streamlines the referral process, minimizing the need for patients to navigate multiple practices for non-treatable AMD care. Collaboration becomes particularly vital in rural areas, where patients may face lengthy travels to see an injecting ophthalmologist or retinal specialist.

References

- Fleckenstein M, Mitchell P, Freund KB, et al. The progression of geographic atrophy secondary to age-related macular degeneration. *Ophthalmology*. 2018;125(3):369-390.
- van Lookeren Campagne M, LeCouter J, Yaspan BL, Ye W. Mechanisms of age-related macular degeneration and therapeutic opportunities. *J Pathol*. 2014;232(2):151-164.
- Friedman DS, O'Colmain BJ, Muñoz B, et al; for the Eye Disease Prevalence Research Group. Prevalence of age-related macular degeneration in the United States. *Arch Ophthalmol*. 2004;122(4):564-572.
- Foreman K, Marquez N, Dolgert A, et al. Forecasting life expectancy, years of life lost, and all-cause and cause-specific mortality for 250 cases of death: reference and alternative scenarios for 2016-40 for 195 countries and territories. *Lancet*. 2018;392(10159):2052-2090.
- Gehrs KM, Anderson DH, Johnson LV, Hageman GS. Age-related macular degeneration: emerging pathogenetic and therapeutic concepts. *Ann Med*. 2006;38(7):450-471.
- Rudnicka AR, Jarrar Z, Wormald R, Cook DG, Fletcher A, Owen CG. Age and gender variations in age-related macular degeneration prevalence in populations of European ancestry: a meta-analysis. *Ophthalmology*. 2012; 119(3):571-580.
- Sacconi R, Corbelli E, Querques L, Bandello F, Querques G. A review of current and future management of geographic atrophy. *Ophthalmol Ther*. 2017;6(1):69-77.
- Flaxel CJ, Adelman RA, Bailey ST, et al. Age-Related Macular Degeneration Preferred Practice Pattern®. *Ophthalmology*. 2020;127(1):P1-P65.
- American Optometric Association. AOA comprehensive adult eye and vision examination. *Quick Reference Guide: Evidence-Based Clinical Practice Guideline*. 1st ed. American Optometric Association 2015. Accessed April 5, 2024. https://www.aoa.org/documents/EBO/Comprehensive_Adult_Eye_and_Vision%20QRG.pdf
- Kaszubski P, Ben Ami T, Saade C, Smith RT. Geographic atrophy and choroidal neovascularization in the same eye: a review. *Ophthalmic Res*. 2016;55(4):185-193.
- Boyer DS, Schmidt-Erfurth U, van Lookeren Campagne M, Henry EC, Brittain C. The pathophysiology of geographic atrophy secondary to age-related macular degeneration and the complement pathway as a therapeutic target. *Retina*. 2017;37(5):819-835.
- Cummings M, Cunha-Vaz J. Treatment of neovascular age-related macular degeneration in patients with diabetes. *Clin Ophthalmol*. 2008;2(2):369-375.
- Holz FG, Strauss EC, Schmitz-Valckenberg S, van Lookeren Campagne M. Geographic atrophy: clinical features and potential therapeutic approaches. *Ophthalmology*. 2014;121(5):1079-1091.
- Rahimy E, Khan MA, Ho AC, et al. Progression of geographic atrophy: Retrospective analysis of patients from the IRIS® registry (Intelligent Research in Sight). *Ophthalmol Sci*. 2023; 3(4):100318. eCollection 2023 Dec.
- Lindblad AS, Lloyd PC, Clemons TE, et al; for the Age-Related Eye Disease Study Research Group. Change in area of geographic atrophy in the Age-Related Eye Disease Study: AREDS report number 26. *Arch Ophthalmol*. 2009;127(9):1168-1174.
- Schultz NM, Bhardwaj S, Barclay C, Gaspar L, Schwartz J. Global burden of dry age-related macular degeneration: a targeted literature review. *Clin Ther*. 2021;43(10):1792-1818.
- Neely DC, Bray KJ, Huisingsh CE, et al. Prevalence of undiagnosed age-related macular degeneration in primary eye care. *JAMA Ophthalmol*. 2017;135(6):570-575.
- Mastellos DC, Reis ES, Ricklin D, Smith RJ, Lambris JD. Complement C3- targeted therapy: replacing long-held assertions with evidence-based discovery. *Trends Immunol*. 2017;38(6):383-394.
- Smailhodzic D, Klaver CCW, Klevering BJ, et al. Risk alleles in CFH and ARMS2 are independently associated with systemic complement activation in age-related macular degeneration. *Ophthalmology*. 2012;119(2):339-346.
- Merle NS, Noe R, Halbwegs-Mecarelli L, Fremeaux-Bacchi V, Roumenina LT. Complement System Part II: Role in Immunity. *Front Immunol*. 2015;6:257.
- Ricklin D, Reis ES, Mastellos DC, Gros P, Lambris JD. Complement component C3-the "Swiss Army Knife" of innate immunity and host defense. *Immunol Rev*. 2016;274(1):33-58.
- Sobrin L, Seddon JM. Nature and nurture- genes and environment-predict onset and progression of macular degeneration. *Prog Retin Eye Res*. 2014;40:1-15.
- Nassisi M, Lei J, Abdelfattah NS, et al. Optical coherence tomography risk factors for development of late age-related macular degeneration in the fellow eyes of patients enrolled in the HARBOR study. *Ophthalmology*. 2019;126(12):1-16.
- Chakravarthy U, Bailey CC, Johnston RL, et al. Characterizing disease burden and progression of geographic atrophy secondary to age-related macular degeneration. *Ophthalmology*. 2018;125(6):842-849.
- Data on file. Apellis Pharmaceuticals Inc.
- Kimel M, Leidy NK, Tschosik E, et al. Functional reading independence (FRI) index: a new patient-reported outcome measure for patients with geographic atrophy. *Invest Ophthalmol Vis Sci*. 2016;57(14):6298-6304.
- Sadda SR, Chakravarthy U, Birch DG, Staurengi G, Henry EC, Brittain C. Clinical endpoints for the study of geographic atrophy secondary to age-related macular degeneration. *Retina*. 2016;36(10):1806-1822.
- Singh RP, Patel SS, Nielsen JS, Schmier JK, Rajput Y. Patient-, caregiver-, and eye care professional-reported burden of geographic atrophy secondary to age-related macular degeneration. *Am J Ophthalmic Clin Trials*. 2019;2(1):1-6.
- Sadda SR, Guymer R, Holz FG, et al. Consensus definition for atrophy associated with age-related macular degeneration on OCT: classification of atrophy report 3. *Ophthalmology*. 2018;125(4):537-548.
- Guymer RH, Rosenfeld PJ, Curcio CA, et al. Incomplete retinal pigment epithelial and outer retinal atrophy in age-related macular degeneration: classification of atrophy meeting report 4. *Ophthalmology*. 2020;127(3):394-409.

en-INT_31_010_01251 The statements of the authors reflect only their personal opinions and experiences and do not necessarily reflect the opinion of any institution that they are affiliated with. The authors alone are responsible for the content of their experience reported and any potential resulting infringements. Apellis Pharmaceuticals, Inc. and Carl Zeiss Meditec AG and their affiliates do not have clinical evidence supporting the opinions and statements of the authors nor accept any responsibility or liability of the authors' content.

© Carl Zeiss Meditec, Inc., 2024. All rights reserved.

Apellis Pharmaceuticals, Inc. does not endorse nor accept any responsibility or liability for use of any ZEISS products.

APELLIS® is a registered trademark of Apellis Pharmaceuticals, Inc. Other trademarks referenced herein are the property of their respective owners

©2024 Apellis Pharmaceuticals, Inc. All rights reserved. 5/24 US-GA-2400005 v1.0

This supplement was developed by Review of Optometry with support from Apellis Pharmaceuticals, Inc. and Carl Zeiss Meditec USA, Inc.

Dr. Miguel Busquets, Dr. Carolyn Majcher, and Dr. Mary Anne Murphy have been compensated for their participation.



Hire qualified opticians with Eyes On Eyecare

If you're frustrated by the hiring game, partner with Eyes On Eyecare® to find qualified candidates for your practice. For more than 10 years, Eyes On Eyecare has helped busy practice owners take the headaches out of hiring with specialized job posting and recruiting services.

SOURCE OPTICAL TALENT MORE EFFICIENTLY WITH OUR:

- ✓ Engaged audience of licensed opticians - including active and passive job seekers
- ✓ Enhanced exposure of your job listing with syndication to top job platforms and our affiliate network
- ✓ Specialized recruiting team with years of eyecare experience to source and screen candidates

I was able to attract good quality candidates to fill my openings.

- Paul Naftali, OD

"I had such a wonderful experience using Eyes On Eyecare. It was so easy to post a job and they walk you through the entire process. I recommend them to everyone I know."

- Ashley Wojcik

PROUD PARTNER OF JOBSON OPTICAL GROUP

Learn more at eyesoneyecare.com/hire-now



MYOPIA MANAGEMENT: PUTTING THEORY INTO PRACTICE

A huge body of literature supports the concept, but many ODs struggle to implement various interventions. Here are lessons learned from the research that can help you.



BY LANGIS MICHAUD, OD
MONTRÉAL

There's no professional conference or discussion forum these days that ignores myopia and the need to control its development, but what happens in practice? The most recent data indicates that less than 20% of eyecare practitioners provide any method of myopia control.¹ Worldwide, single vision lenses are still the most commonly prescribed, despite mounting evidence in the literature to support other interventions.² Is this a collective denial of the myopia epidemic Brien Holden alerted us to a decade ago, or is there simply a disconnect between what we *want* to achieve and what we're *capable* of achieving? With limited financial resources and even less free time, is the thought of reengineering our practices to make them suited to myopia management simply a bridge too far?

In this article, we will look at the evidence and try to translate findings from research into clinical practice. We'll also tackle some of the most

Photo: Getty Images



A 2023 survey of eyecare practitioners globally found conventional single vision spectacle lenses to be the most prescribed option for progressive myopia in children (32.2% of respondents). However, this has been declining since 2019, the report states, and myopia control spectacles (15.2%), myopia control contact lenses (8.7%) and combination therapy (4.0%) are growing in popularity.

common myths that hold back the adoption of various myopia interventions. Perhaps it will then be possible to move the needle and increase the number of patients who benefit from effective myopia control.

Where Does Myopia Come From?

This is a fundamental question. We need to understand the factors that can

trigger myopia and those that can cause it to progress, even in adulthood. With this understanding, it becomes easier to select control methods and, most importantly, understand their limitations so that we can set realistic expectations about their effectiveness.

Any first-year optometry student will tell you that myopia can be defined as a refractive error in which rays of light entering the eye parallel to the

optical axis are focused in front of the retina when ocular accommodation is relaxed.³ This usually results from the eye being too long from front to back, but can also be caused by an overly steep cornea, a lens with increased optical power, or both. This is the common understanding of most eyecare professionals around the world. However, this definition fails to account for dynamic

About the author

Dr. Michaud is the former dean of the School of Optometry at the L'École d'optométrie de Université de Montréal. He is a diplomate of the American Academy of Optometry and a fellow of the British Contact Lens Association, the Scleral Lens Education Society, the European Academy of Optometry and the International Academy of Orthokeratology and Myopia Management. He was awarded the Donald R. Korb for excellence in research by the AOA and named the GPLI Educator of the year, both in 2023. He has received honoraria from Bausch + Lomb, CooperVision, Johnson & Johnson and Alcon.

processes during growth that, importantly, we have the ability to influence.

On closer inspection, myopia is more a matter of a loss of retinal homeostasis that disrupts the balance achieved during emmetropization, resulting in an eye that is too long for its dioptric power.⁴ The refractive error, therefore, does not define the nature of the damage but rather its consequence.

In fact, as with other organs, the eye's growth is regulated by homeostatic control mechanisms. In this case, the eye relies on the quality of the visual signal hitting the retina as a principal input to guide its growth.⁵ In this way, the retina can react to whether the image is clear or blurred. The retina we're talking about here is the central retina (the foveal retina) and the one within 10° to 20° of the fovea (macular retina).⁶ Specifically, this is limited to the macular area (1° = 0.3mm; 15° to 20° = 4.5mm to 6.0mm).^{7,8} Outside this more sensitive zone, the retinal signal becomes noise that cannot be well interpreted by the retinal tissue, especially due to the asymmetry of the ocular structure between the different quadrants.⁹

A blurred image that forms in front of the peripheral retina is referred to as myopic defocus, while a blurred image that forms behind the retina is referred to as hyperopic defocus. The former causes the eye to resist elongation, while the latter favors an increase in axial length and thus greater myopization.¹⁰

When we talk about defocus, we mean optical aberrations produced by spectacle lenses, or, in the case of ortho-K, by the shape of the cornea. Myopic defocus is due to a more convex power and is therefore associated with positive spherical aberrations and coma, whereas hyperopic defocus is associated with negative aberrations, as found in single-vision spectacle lenses. More specifically, when positive aberrations increase significantly (which is the goal in myopia management), they cause a decrease in contrast sensitivity to the point where the retina becomes

confused. This is what slows down the development of myopia.¹¹

Similarly, in emmetropia the presence of one type of defocus theoretically balances the presence of the other, and retinal homeostasis is reached.¹² The retina, thus exposed to conflicting stimuli, remains neutral and aligned with its dioptric power. When one of the two signals becomes dominant, the retina resumes its resistance to elongation (*e.g.*, in the presence of multifocal/bifocal contact lenses) or, conversely, favors axial length increase (wearing single-vision minus powered lenses).

All this happens through the release of biomodulators that affect the blood flow and the choroid, then the sclera. In the presence of myopic defocus, biomodulators thicken the choroid and lead to collagen fibers remodeling to make sclera stiffer.¹³ With hyperopic defocus, the choroid thins and blood flow is reduced, causing hypoxia. The scleral fibers remodel, with the tissue becoming softer and more easily deformable.¹⁴ It's important to remember that the central retina is not

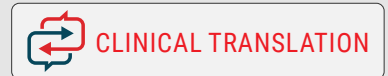just passive. Foveal blur is interpreted as form deprivation and leads to axial elongation.¹⁵ In all of these mechanisms, we must remember that each retina is unique, with its own threshold of stimulation.¹⁶ It also operates under a dose-response phenomenon.¹⁷

Goal of Myopia Management

Once this first step of understanding the mechanisms underlying myopia has been achieved, it's time to set realistic goals for intervention methods. Keep in mind that the physical growth of a child, and therefore the growth of the eye, generates an axial elongation, especially during growth spurt.¹⁹ We can't prevent this from occurring. Consequently, the goal must be to mimic the eye growth of an emmetropic patient whose retina is in homeostasis. Studies have shown that, across all ethnic groups, a mean increase in axial length of 0.2mm between the ages of five and 10, 0.1mm between the ages of 10 and 16, and no change thereafter is the norm for emmetropes.²⁰ These limits should become

Myth No. 1: Myopes are all the same.

The existence of an individual threshold at the retinal level is undoubtedly the strongest argument that should convince us to treat each myopic child or patient as a unique individual and not as a statistic or an average. The child sitting in your chair may be within or outside the standard deviation or just in the middle of it. The important thing is to recognize that their treatment plan must be as unique as their condition. This means treating myopia one child at a time.



Myth No. 2: Undercorrection protects against myopic evolution.

It's not uncommon for parents or patients to argue for a downward revision of their optical prescription. It's also not uncommon for eyecare professionals to knowingly undercorrect a myopic patient, thinking they're helping. All central blur is associated with increased myopia.¹⁸ Undercorrection must be avoided under any circumstances.

Clinically, this means that the lenses worn must always provide unimpaired visual acuity. It also means that the patient must be seen regularly. A patient with -1.50D of myopia who receives ophthalmic lenses of this power will be well-corrected. If he or she is not seen again until a year later and their myopia has progressed to -2.50D, this means that for several months of the year the child's visual quality has been reduced, and this form deprivation has only accelerated the process of myopia progression.

In this particular case, the visual acuity could be reduced to 6/18, making the child visually handicapped for several weeks. This is unacceptable. Patients should therefore be seen more frequently, and, above all, the correction should be changed as soon as the visual acuity is reduced. My personal criterion is a visual acuity of 6/7.5 (20/25) monocularly and 6/6 (20/20) binocularly. Lower visual acuity levels prompt me to update the patient's prescription.

our reference criteria for judging the myopic evolution of patients.

Time to Take Action

The need to intervene is well-established. Now, it's time to take action. Let's explore what tools we have in hand.

Depending on where in the world you practice, access to myopia control products may vary greatly. It's understandable that a practitioner with access to limited resources might feel deprived. On the other hand, even if the treatment prescribed is not optimal, at least that professional is making an effort to correct myopia by understanding the underlying issues. There is always a way to help a child.

Basic Principles

Based on what we know about the mechanisms leading to myopia and its evolution, it makes sense to consider any device through the angle of their optical and physiological impacts. In order to select the best approaches, the following principles are important to consider:

1. Take the time to complete a thorough case history:



Photos: Hoya, Essilor

The Miyosmart lens from Hoya (left) contains a 9.4mm diameter central zone of distance vision surrounded by a honeycomb-like pattern of 396 defocusing lenslets of +3.50D power, equally distributed. Essilor's Stellest (right) is designed with a similar 9mm central zone. However, the surrounding is made of highly aspherical lenses, varying in distribution and power vs. distance refractive error correction, along 11 segmented rings, to generate a volume of defocus following the retinal shape.

- rapid progression factors (age, sex, ethnicity, genetics, binocular vision)
 - patient's visual needs
 - environment (screen time, working distance, outdoor exposure)
 - willingness to wear contact lenses
 - factors that may influence compliance (sleep time, sports and other activities)
 - parents' and patient's preferences
 - budget
2. Make sure to collect valid and accurate clinical data.

3. Select the strategy based on the risk of high myopia and long-term pathology. I strongly recommend the use of percentile growth charts according to ethnicity.^{25,26} These tables indicate, according to age and axial length, the expected progression as well as the risk of high myopia, and therefore of greater pathology. Thus, any age/axial length combination that exceeds the 50th percentile merits active control of the myopic condition. If this combination exceeds 75th percentile, more intensive measures should be considered.

For example: two kids, 10 years old, both -2.00D myopes, same school, same neighborhood, same video games, same everything. Child A shows axial length of 23.1mm and child B has a longer eye: 24.5mm. The first one reaches barely the 50th percentile associated with no high myopia risk and the former one is peaking at the 95th percentile with 16% chance of high (blinding) myopia. Strategy and treatment will not be the same to keep both safe. In the first case, anti-myopia glasses may be enough while a combined therapy with low-dose atropine will be needed for the kid at higher risk.

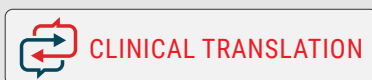4. Select the optimal dose of defocus without impairing distance vision. The defocus dose is determined by the amount of positive optical aberrations produced and the area it covers in the macular area. The dose can be increased by using more convex power

Myth No. 3: Axial length is not a mandatory measurement in myopia management.

I am a firm believer that axial length measurement must be the standard and only objective measure of a patient's myopia progression. Our goal is to control myopia in order to reduce the risk of high myopia in the future.²¹ However, this risk is based on the stretching of the tissues and not on the dioptric evolution, which is an optical phenomenon. Correlation between axial length and refractive error is not always present.²² There are several cases where the diopter has been stabilized but the axial length has continued to evolve in an unconsidered manner. The classic case is the ATOM1 study.²³

Basing the assessment of myopia control efficiency on diopters is like navigating blindly in the fog without really knowing what's going on in front of you. The analogy here with glaucoma must be made. Would we treat this pathology by relying solely on the measurement of intraocular pressure? Certainly not. Studies have long proven that pressure is, at best, a risk factor, but certainly not a metric for monitoring the evolution of glaucoma.²⁴ What OCT scans of the optic nerve are to glaucoma, axial length measurements are to myopia control.

Take the example of a patient wearing ortho-K lenses visiting you in the late afternoon who shows low residual myopia (-0.50D). Is this a normal effect of the restoration of the corneal curvature or is it an increase in their refractive error? It's always possible to confirm by re-measuring acuity with the OK lenses in place, but the truest and most reliable measurement will come from axial length assessment. When thinking about pathology prevention, we must be minimally serious and take the appropriate tools to assess myopic condition.



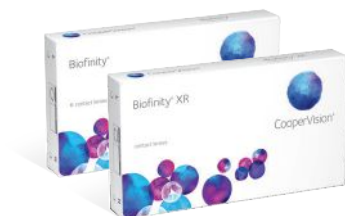

Looking to bring even more patients into
the incredible comfort of Biofinity®?¹

YOU'RE GOLDEN

Biofinity® and Biofinity® XR together offer sphere powers from +15.00D to -20.00D; 1.5x greater than some other monthly replacement spherical silicone hydrogel lenses.² With Biofinity® contact lenses, you can provide vision correction for 99.9% of spherical prescriptions.³ And these lenses are now available at an equal price and with equal patient rebates across the full range, providing greater support across the full range of sphere powers. With Biofinity®, you're golden.

EXPLORE A
GOLDEN
OPPORTUNITY



Biofinity®
sphere | XR



CooperVision®

1. CVI Data on file, 2022. Based on global product sales and internal estimates of products using Aquaform® Technology over 12 months in 2022.

2. CVI data on file, 2023. US market data. Products are Ultra Sphere and Acuvue Vita sphere. December 2023.

3. CVI data on file, 2020. Rx coverage database; 14 to 70 years; Rx with <0.75DC.

TABLE 1. SPECTACLE LENS OPTIONS FOR MYOPIA MANAGEMENT

Lens Type	Manufacturer	Design	Study Duration	Axial Length Change (mm) Subjects/Controls	Rx Change (D) Subjects/Controls	Efficacy
DIMS ²⁸	Hoya	9mm diameter central zone surrounded by a zone of 33mm of +3.50 lenslets (ratio 50-50)	6 years	Year 1: 0.10/0.32 Year 3: 0.31/NA Year 6: 0.60/NA	Year 1: -0.18/-0.58 Year 3: -0.53/NA Year 6: -0.95/NA	High
HALT ²⁹	Essilor	9mm diameter central zone surrounded by 11 rings of highly aspherical lenslets (ratio 50-50; power between +3.50 and +6.00). Their distribution varies based on distance refractive error.	3 years	Year 1: 0.12/0.36 Year 3: 0.49/0.98	Year 1: -0.25/-0.82 Year 3: -1.00/-2.05	High
DOT ³⁰	Sight Glass	5mm diameter central zone surrounded by translucent microscopic diffusers (diameter of 0.14mm) to scatter light	4 years	Year 1: 0.15/0.30 Year 3: 0.59/0.72	Year 1: -0.14/-0.54 Year 3: -0.83/-1.16	Moderate
CARE ³¹	Zeiss	A: 7mm diameter central zone and mean surface power of +4D (for kids <10) B: 9mm diameter central zone and mean surface power of +3.80D (kids >10)	1 year*	Year 1: 0.26/0.36*	Year 1: -0.56/-0.71*	Low*
MDPL ³²	IOT	7mm clear central zone Asymmetric defocus (temporal:+1.87D; nasal:+1.50D; inferior:+2.00D; superior: none)	1 year	Year 1: 0.14/0.23	Year 1: -0.56/-0.71	Low
Perifocal ³³	Russian design distributed by Rodenstock and others	10mm clear central zone surrounded by asymmetric horizontal progressive defocus (+2.50D @ 25mm temporal; +2.00D @ 25mm nasal)	4 years	Results are not credible. The only study published shows many flaws.		Not recommended until more credible results to be published.

*Results are from a study conducted with a prototype lens very close to the final design, not the Zeiss CARE lens, for which data are unavailable. Results may vary with the lens designs as marketed. More data are needed from the manufacturer.

lenses and/or concentrating the myopic defocus in an area as close to the fovea as possible (10° to 20°). A higher dose is required for fast progressors (usually younger patients eight to 12 years old) and higher myopes.

5. Choose a strategy that meets the patient’s needs, but more importantly, one that is supported by evidence-based results from state-of-the-art, long-term randomized clinical trials. Be critical when reading articles or reports about the effectiveness of the product.

6. Ophthalmic lenses or pharmaceutical agents should be fitted and centered, or prescribed, according to the manufacturer’s recommendations.

7. Recommend a wear schedule for prescribed ophthalmic lenses.

8. Re-evaluate treatment periodically.

Tools in our Hands

These will vary depending on where you practice. As most of this publica-

tion’s readership is based in the US, you unfortunately do not yet have access to some interventions, most notably spectacle lenses designed for myopia control.

The remainder of this article will delve into the nuts and bolts of using various optical and pharmaceutical interventions.

Spectacles

Anti-myopia spectacle lenses are undoubtedly the simplest way to equip

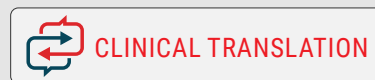a patient for myopia control. Several designs have been introduced to the market (four or five in Europe and Canada, and more than 20 to 30 in Asia), and their effectiveness is generally equivalent to that of other strategies, at least if the following elements are respected:²⁷

- The frame chosen allows the eye to be well centered, in the middle, leaving sufficient room for defocus to hit the eye from all quadrants.

Myth No. 4: Glasses are less effective than contact lenses.

Based on the available literature, some anti-myopia spectacle designs are as effective as soft lenses in the same category or ortho-K. And that’s assuming compliance, meaning the frame is well chosen and stable, and the lenses are worn at least 10 to 12 hours a day, every day.

The analysis also allows us to see that certain designs (Care, MDPL, perifocal) are being left as second-tier by those that are now becoming gold standards (DIMS, HALT). Others fall in between as a still valuable option (DOT) without standing out. In this case, the DOT design represents another type of strategy based on contrast sensitivity and not defocus. In some patients, it may represent a better alternative.



THE DANGER CAN BE HARD TO SEE. LOOK CLOSER.

For patients with Graves' disease (GD), Thyroid Eye Disease (TED) may be hiding in plain sight.^{1,2}

Up to 50% of patients with GD may develop TED, a separate and distinct disease which can progress if left untreated. Look out for the early signs and symptoms³⁻⁶:

- Proptosis
- Sensitivity to light
- Diplopia
- Grittiness
- Dry eyes
- Pain or pressure behind the eyes

If you identify new or changing signs or symptoms, consult with an eye doctor who specializes in TED right away.^{1,7}



Visit [TEDImpact.com](https://www.tedimpact.com) to find a TED Specialist

References: 1. Barrio-Barrio J, Sabater AL, Bonet-Farriol E, Velázquez-Villoria Á, Galofré JC. Graves' ophthalmopathy: VISA versus EUGOGO classification, assessment, and management. *J Ophthalmol.* 2015;2015:249125. 2. Bothun ED, Scheurer RA, Harrison AR, Lee MS. Update on thyroid eye disease and management. *Clin Ophthalmol.* 2009;3:543-551. 3. Bahn RS. Graves' ophthalmopathy. *N Engl J Med.* 2010;362(8):726-738. 4. Bartalena L, Krassas GE, Wiersinga W, et al. Efficacy and safety of three different cumulative doses of intravenous methylprednisolone for moderate to severe and active Graves' orbitopathy. *J Clin Endocrinol Metab.* 2012;97(12):4454-4463. 5. Patel A, Yang H, Douglas RS. A new era in the treatment of thyroid eye disease. *Am J Ophthalmol.* 2019;208:281-288. 6. Ponto KA, Pitz S, Pfeiffer N, Hommel G, Weber MM, Kahaly GJ. Quality of life and occupational disability in endocrine orbitopathy. *Dtsch Arztebl Int.* 2009;106(17):283-289. 7. Ross DS, Burch HB, Cooper DS, et al. 2016 American Thyroid Association guidelines for diagnosis and management of hyperthyroidism and other causes of thyrotoxicosis. *Thyroid.* 2016;26(10):1343-1421.

- The frame must be stable and not slip. If necessary, frames with nose pads and/or temples that can be easily adjusted to follow the curve of the ear are preferred.

- Spectacles should be worn for 12 to 14 hours, *i.e.*, full time. This is undoubtedly the greatest challenge, and compliance can be sorely tested. Children wearing anti-myopia spectacles should not remove them when doing near work.

Table 1 shows differences between major products available in the market (outside US).

Contact Lenses

There are several contact lens options that can both correct and control myopic progression (Table 2). Remember that a sufficient dose of optical aberrations (defocus) must be generated to influence retinal response, while

maintaining clear central vision. In general, these objectives can be achieved with multifocal lenses or by remodeling the cornea with corneal lenses.³⁴ Let's concentrate on soft multifocal lenses.

Preferred soft lens designs are generally distance-centered multifocals, assuming that placing the convex profile (add power) in the periphery will make it easier to influence peripheral retinal response.

Table 3 describes the clinical population of several soft lenses studied in cohorts of young myopic patients.³⁷⁻⁴² The populations among these studies are quite similar, with the exception of the Diaz-Gomez study of the Mylo EDOF lens, showing a slightly older and more myopic cohort at baseline. Table 4 summarizes the clinical performance of the various contact lenses.

Without a doubt, CooperVision's MiSight 1 Day lens is the most studied

and recognized anti-myopia contact lens in every region around the world. Its solid performance makes it the standard by which all others are measured. We only have short-term data on the other lenses, so comparison is difficult. At six months, Abiliti performs equally well to MiSight, but we cannot yet make a strong recommendation toward that product pending longer term results. At one year of wear, NaturalVue shows similarly good results. But again, longer term data will be needed to really compare all three products. Knowing that the best performance is always in the first year, it will be interesting to see if this favorable result continues over time.

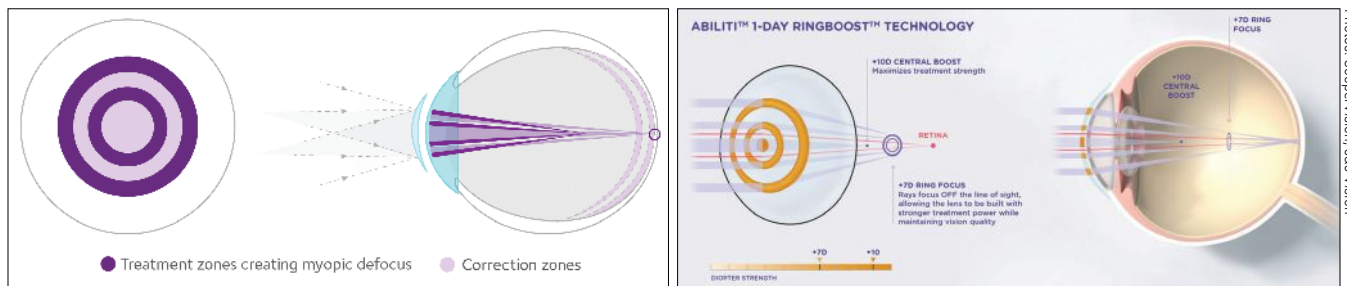
Extended depth-of-focus (EDOF) designs, in some cases, may seem to be less efficient compared to other soft lens designs and best anti-myopia glasses.⁴⁰ For example, after 36 months, EDOF lens wearers gained 0.55mm

TABLE 2. MULTIFOCAL CONTACT LENS OPTIONS FOR MYOPIA MANAGEMENT

Lens Type	Manufacturer	Material	Parameters	Design
MiSight	Cooper Vision	Omafilcon A	<ul style="list-style-type: none"> • BC 8.7 • Diameter 14.2 • Power range -0.50 to -7.00 	Dual-focus lens: correction in the center zone surrounded by the first annular treatment ring (treatment zone), a 2nd annular distance zone and finally a 2nd annular treatment zone with corresponding diameters of approximately 3.40, 4.80, 6.80 and 8.80mm, respectively
Abiliti 1 Day	Johnson & Johnson Vision	Senofilcon A	<ul style="list-style-type: none"> • BC 7.9 • Diameter 13.8 • Power range -0.25 to -8.00 	Novel ring focus soft contact lens containing a myopia correction zone and annular treatment zones producing a +7.00D non-coaxial plus power and a +10.00D zone (0.79mm) coaxially.
NaturalVue	VTI Technologies	Etafilcon A	<ul style="list-style-type: none"> • BC 8.3 • Diameter 14.5 • Power range +4.00 to -12.25 	Non-monotonic design is based on catenary optics. It generates an increase in plus power almost immediately (<0.5µm) from the lens center until reaching maximum measured at a radius of 2.6mm (3.31D ± 0.36D). This creates a virtual pinhole effect. From there, the plus power decreased and is after maintained from 3mm to the end of the optic zone. Looking at the power profile of this lens, we cannot describe it as a true EDOF design.
Biofinity Multifocal (D design)	CooperVision	Comfilcon A	<ul style="list-style-type: none"> • BC 8.6 • Diameter 14.0 • Power range +6.00 to -8.00 (D Design: +1.50 to +2.50) 	A central optic zone of 1.5mm radius and then an increase in plus power of around 1.25-1.50D from the 1.5mm to 2mm radius. This more convex power was then maintained out to a radius of about 3.8mm for lower minus lenses and decreased until reaching the edge of the optic zone. One of the few off-label options for young adults who need myopia management. Important note: The labelled distance power does not match the power profile of the lens (diff. +0.50D in general). Consequently, the final prescribed power to get clear distance vision must often be overminused.
EDOF	Various distributors (Seed, Menicon; Mylo, Markenovsky)	SiHy (Mylo); Zwittertronic SIB (Seed)	<ul style="list-style-type: none"> • BC 8.4 • Diameter 14.2 • Power range: +5.00 to -12.00 • low, med, high EDOF (add) 	This design is based on a manipulation of spherical and higher-order aberrations to create a specific optical effect and image profile. This contributes to extend the depth of focus (DOF)—the range of clear vision along the visual axis over which an image may be focused and perceived as clear. To compare, single vision has a short DOF, single point multifocals have short DOF with two focal points. With EDOF lenses, the visual signals alternate in front and behind the retina, which may explain the relatively less efficient outcomes.

TABLE 3. SIGNIFICANT STUDIES OF CONTACT LENS OUTCOMES IN MYOPIA MANAGEMENT³⁷⁻⁴²

Study	n	Test Results					Control Results				
		Age	D	AL	% Asian	% Female	Age	D	AL	% Asian	% Female
Acuvue Abiliti	101	10.0 ± 1.6	-2.50 ± 0.95	24.65 ± 0.78	54	48	9.9 ± 1.6	-2.43 ± 1.00	24.43 ± 0.79	47	49
Mylo (EDOF) S. Diaz	90	10.9 ± 1.6	-2.80 ± 1.80	24.62 ± 0.99	0	56	11.2 ± 1.1	-2.69 ± 0.99	25.62 ± 0.87	0	58
MiSight	144	10.1 ± 1.3	-2.02 ± 0.77	24.42 ± 0.66	46	46	10.1 ± 1.4	-2.19 ± 0.81	24.46 ± 0.70	44	50
Natural Vue (Protect)	145	9.8 ± 1.5	-2.43 ± 1.03	24.53 ± 0.80	69	52	10.0 ± 1.4	-2.39 ± 1.13	24.57 ± 0.94	73	50
Sankaridurg (EDOF)	95	10.4 ± 1.3	-2.41 ± 0.82	24.50 ± 0.70	0	57	10.5 ± 1.3	-2.29 ± 0.75	24.70 ± 0.80	0	43
Blink (Walline)	196	10.2	-2.28 ± 0.90	24.43 ± 0.74	9	65	10.5	-2.46 ± 0.97	24.45 ± 0.83	9	65



Both the MiSight and the Acuvue Abiliti lenses seem to use the same alternating zones approach but, in fact, there are differences in the way they generate, and the level of, their respective myopic defocus (coaxial power and ring boost).

in axial length while MiSight wearers grew by 0.30mm during the same time. This is hard to explain, especially because the clinical population of EDOF is all Caucasian while the ethnic makeup is 50-50 Caucasian-

Asian for studies of MiSight. If Asian myopic patients are progressing more, they must be increasing the rate rather than decreasing it. The EDOF study population is also older, so their rate of progression should be slower.

The numbers here are puzzling. Their control group shows a higher evolution vs. MiSight (0.97mm vs. 0.62mm). These suspect data echo the fact that the EDOF study reported an improvement in lens performance after the first

TABLE 4. CLINICAL PERFORMANCE OF SOFT CONTACT LENSES IN MYOPIA MANAGEMENT³⁷⁻⁴²

Lens/Design Studied	Duration (in months)	AL Variation (mm)			Cyclorefraction (D)			Efficacy of Intervention (AL)
		Test	Control	Saved	Test	Control	Saved	
Acuvue Abiliti	6	0.08	0.19	-0.11	-0.12	-0.35	-0.13	high
Mylo (EDOF)/S. Diaz	6	0.11	0.17	-0.06	-0.13	-0.29	-0.16	low
Sankaridurg (EDOF)	6	0.12	0.19	-0.07	-0.27	-0.39	-0.12	low
MiSight	12	0.09	0.24	-0.15	-0.18	-0.58	-0.40	high
Natural Vue (Protect)	12	0.12	0.29	-0.17	-0.18	-0.59	-0.41	high
Sankaridurg (EDOF)	12	0.24	0.33	-0.09	-0.53	-0.66	-0.13	low
Mylo (EDOF) S. Diaz	12	0.19	0.34	-0.15	-0.34	-0.57	-0.23	low
Mylo (EDOF)	24	0.37	0.66	-0.29	-0.62	-1.13	-0.51	low
BLINK (Biofinity D) Walline	36	0.42	0.66	-0.24	-0.60	-1.05	-0.55	low
Diaz-Gomez (EDOF)	36	0.55	0.97	-0.42	-0.90	-1.64	-0.54	low
MiSight	36	0.30	0.62	-0.32	-0.50	-1.25	-0.75	moderate

Legend: Efficacy rating based on AL and refraction saved vs. control. High: >55% saved; Moderate: 45-55% saved; Low: <45% saved

Photo: Harrow Health



Harrow Health offers three concentrations of atropine, although use of these (or other) formulations for myopia remains off-label at present in the United States. Vyluma continues to pursue FDA approval of its low-dose atropine product, code named NVK-002.

year of wear, which is highly unusual in myopia studies. For all of these reasons, and given the significant difference from the early EDOF studies, the latest data must be interpreted with caution and the lens performance must be considered at least questionable.

Practitioners should also keep in mind the impact on a child's life. Not only are contact lenses an effective means of correcting and controlling myopia, but fitting a child with contact lenses also boosts self-esteem and has been associated with psychological benefits.⁴¹ However, with contact lenses—as with anti-myopia spectacles—compliance is critical, both in terms of wearing days/hours to ensure a sufficient “dose” of control, and in terms of cleaning and disinfection, especially if ortho-K is recommended.

Atropine

Since the ATOM1 study, atropine has attracted considerable interest as a treatment for myopia. This study compared different concentrations of atropine administered monocularly over a two-year period in a cohort of young myopes. The results were surprising: The highest concentration (1%) was highly effective but associated with an equally high rebound effect, which was not expected. In contrast, the lowest concentration was surprisingly effective

in controlling refraction to almost the same degree, while eliminating the rebound effect and significantly reducing the troublesome symptoms of light sensitivity and loss of accommodation.

This was enough for the authors to repeat a second study, called ATOM2, this time with lower concentrations only.⁴³ They confirmed the relevance of considering atropine as a monotherapy in myopia control, at least for its effect on refraction.

But nobody noticed at that time the very negligible effect of the 0.01% concentration on axial length, which continued to progress as much as the control group.

It should be noted that the authors of the ATOM studies revisited their patients 20 years later.⁴⁴ They found that the treated patients had developed in the same way as the control group.

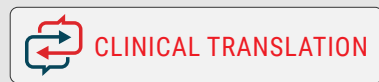Their treatment had no long-term effect. It has to be said that the ATOM participants were only treated for two years, while they were still young or teenagers and still evolving rapidly. That's like treating a glaucoma patient for only two years and then looking at their eye health 20 years later, when they would have stopped treatment altogether. The damage to the optic nerve would be obvious.

Following ATOM, the LAMP study was initiated, again in Asia. This time, researchers compared reduced doses of atropine (0.05% vs. 0.02% and 0.01%). This study has just published its five-year results.⁴⁵ The results are as follows:

- The study confirms a dose-response mechanism: the 0.05% concentration controls myopia better than the others.
- The 0.05% concentration may not be sufficient for some children, especially those progressing rapidly or under the age of 10. In these cases, a higher concentration is required.
- Brief discontinuation of the medication does not result in a significant loss of efficacy.

Myth No. 5: Center-near multifocals are not efficient to control myopia.

This is a somewhat simplistic view that relies on the impact of direct light rays, whereas light includes oblique beams that can also contribute to the desired optical effects. In theory, a near-centered multifocal lens may also be considered.³⁵ However, this option is not supported by a lot of literature and or the habits of many practitioners. The limited amount of research carried out in this field means that this option cannot be totally ruled out. As Dr. Tom Aller regularly says: Bring in any plus, anywhere, and you'll have some control over myopia.



Myth No. 6: Only FDA-approved products must be prescribed.

Only one soft contact lens is FDA-approved, while other jurisdictions have also applied the myopia control label to other products. However, this does not mean that other products that are considered “off-label” cannot be recommended.³⁶ As with anti-myopia spectacles, the first requirement is that the product has been the subject of a serious randomized trial, ideally over more than one year. Second, the use of the product must be sufficiently widespread among eyecare practitioners to be considered standard practice. It should be noted that in some jurisdictions, the prescription of off-label products must be disclosed to patients in order for them to give informed consent.

Myth No. 7: All designs are the same. They all produce the same clinical outcome.

Not surprisingly, as with eyeglasses some contact lenses are at the top of their class, others are in the middle of the pack, and it would be difficult to recommend the use of certain lenses that are disappointing in performance compared to others. This may be due to the difference in designs.



Changing SIGHT Overnight.

Overnight Orthokeratology

1.

NCLE certified consultation experts to guide you through the entire fitting process

2.

Highly adjustable parameters with an online lens design calculator

3.

Dynamic Edge Profile™ delivers remarkable comfort

4.

Diameter & optic zone options allow the doctor to customize the lens to the patient



Scan to learn more about REMLens® and get certified today.



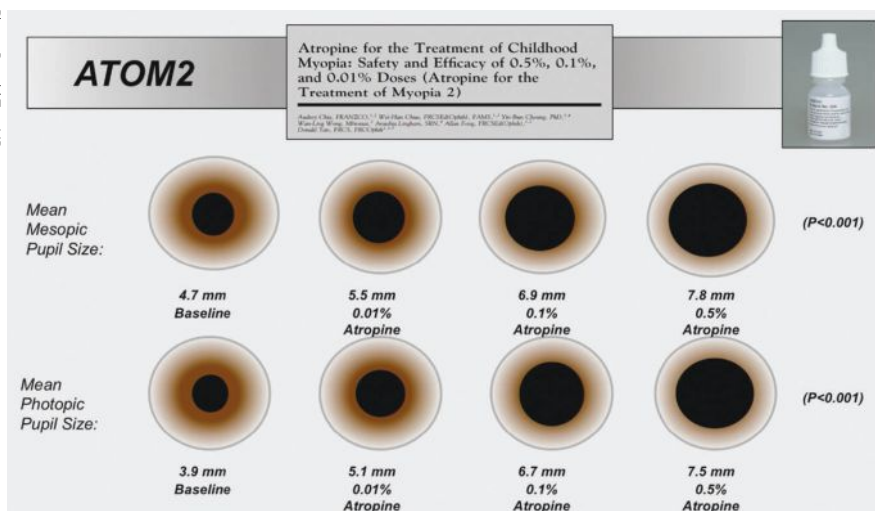
X-CEL
SPECIALTY CONTACTS

800.241.9312
xcelspecialtycontacts.com/remlens

Vision Shaping
Treatment VST™

MADE EXCLUSIVELY WITH
BOSTON® EQUALENS® II
LENS MATERIALS

Photo: Donald Tan, MD



ATOM2 used lower concentrations of atropine to minimize side effects, including pupil dilation and associated photophobia, while maintaining effective control of myopic progression. This graph illustrates the expected variation in pupil size with different concentrations. It should be noted that there is a dose-response effect, both for pupil variation and for efficacy on axial length.

In cases where the concentration is not sufficient, the Netherlands method should be used.⁴⁶ This approach, which originated in Rotterdam, uses percentile growth charts as a starting point. Any patient above the 75th percentile is given a 0.5% dose of atropine. Of course, side effects must be compensated for by wearing progressive (add +1.75D) and photochromic glasses. This dose is maintained until the age of 16 years or earlier if stability is achieved (<0.05mm axial length progression per year for two consecutive years). At this concentration, the dose should then be tapered by halving the concentration every two to three months until discontinued. If axial length increases again, repeat the dose until it stabilizes. For patients below the 75th percentile, a dose of 0.05% is recommended. Again, treatment is continued until stabilization. Although not mandatory, it is recommended to taper the drug after discontinuation. This is consistent with a recent study that reported a potential rebound effect even with a reduced dose of 0.01%.

Other recent studies have examined the efficacy of the 0.01% concentration as monotherapy. These studies are almost unanimous in demonstrating the ineffectiveness of this dose, particularly in younger myopes who progress more rapidly.⁴⁷⁻⁴⁹ There are few excep-

tions like the CHAMP study, which compared 0.02% and 0.01% concentrations.⁵⁰ The products used are standardized and not compounded preparations. This ensures product stability and the certainty of a constant dose. Surprisingly, the 0.01% concentration proved to be more effective than the 0.02% concentration in both aspects studied, *i.e.*, refractive component and axial length.

These findings raise several questions. The authors continue to analyze their data to find a logical explanation for the fact that their study contradicts the now well-established dose-response with atropine. Several factors could explain these outlier results. The com-

position of the two cohorts studied is a first variable. Adherence to treatment must undoubtedly be closely monitored, especially since a large part of the study was conducted during the COVID-19 pandemic and the participants could therefore not be monitored as rigorously as in a study conducted in normal times. For the time being, therefore, we must reserve judgment on this study until further details are available.

Finally, the 0.01% concentration was also studied in combination with an anti-myopia ophthalmic lenses.⁵¹ With both anti-myopia spectacle lenses and OK lenses, the addition of low-dose atropine improved control in myopic subjects.⁵²⁻⁵³ The only exception was the combination of atropine with multifocal soft lenses, where no improvement was seen with the addition of the drug.⁵⁴

Little is known about the mechanism of action of atropine in myopia control. Certainly, its antimuscarinic action cannot be considered; other agents in this family have failed to control axial length progression or myopia. It has been speculated that an effect on ganglion cells and the on/off pathway may be involved.⁵⁵ This remains to be proven in humans.

It is also interesting to note that pupil size increases with atropine. This increases the area of impact of myopic defocus and consequently the dose reaching the retina. This increase in dose may be related to the improved clinical results obtained with the addition of low-dose atropine.

Myth No. 8: There is no rebound effect with the use of low-dose atropine.

From the LAMP study, it is known that the concept of dose response applies to atropine, as it applies to outdoors exposure and defocus induced lenses. A higher concentration of the medication is associated with better control. The same concept applies to the rebound effect. The rebound effect is also greater with higher doses (ATOM1). That said, this does not necessarily mean that there is no rebound effect with the use of low concentrations, as has recently been demonstrated.⁵⁶

Professionals should therefore be aware of the following when considering prescribing atropine for myopia control:

- Treatment must be established on a long-term basis—until the myopic condition has stabilized. As ATOM and LAMP have shown, medication applied for only one or two years has little long-term impact on myopia evolution.
- It's safer to taper in any prescribed dose of atropine at treatment cessation. The withdrawal period is obviously shorter with lower doses.



Takeaways

There is only one conclusion to this article. Myopia control is not optional, but rather a new standard of practice to prevent pathologies that can lead to visual handicap and long-term risks to eye health. The use of single-vision optical devices should be considered the exception rather than the rule. The methods used to control myopia have never been so abundant as they are now, and the pipeline is full of new products that will add to this armamentarium. Strategies and products must be tailored to the individual characteristics of the myopic patient (one child at a time) and be maintained until the condition has stabilized, which obviously requires regular follow-up over time.

Myopia is no longer a simple refractive error. It is, for the patient and for us, a rewarding journey. ■

Note: A future article by Dr. Michaud will complement this one by exploring orthokeratology in detail.

- Di Marco, A. Chow A. ACS M et al. Myopia in Practice (MIP) Study. American Academy Optom. 2023. Poster no 235334.
- Wolffsohn JS, Whayeb Y, Logan NS, Weng R. IMI - global trends in myopia management attitudes and strategies in clinical practice - 2022 Update. Invest Ophthalmol Vis Sci. 2023;64(6):6.
- Flitcroft DJ, He M, Jonas JB, et al. IMI - Defining and classifying myopia: a proposed set of standards for clinical and epidemiologic studies. Invest Ophthalmol Vis Sci. 2019;60(3):M20-30.
- Wallman J, Winawer J. Homeostasis of eye growth and the question of myopia. Neuron. 2004;43(4):447-68.
- Chakraborty R, Read SA, Vincent SJ. Understanding Myopia: Pathogenesis and Mechanisms. In: Ang, M., Wong, T. (eds) Updates on Myopia. Springer, Singapore. 2019;65-94.
- Smith III EL, Arumugam B, Hung LF, et al. Eccentricity-dependent effects of simultaneous competing defocus on emmetropization in infant rhesus monkeys. Vision Res. 2020;177:32-40.
- Remington LA. Retina. In: Clinical Anatomy and Physiology of the Visual System (Third Edition), Butterworth-Heinemann. 2012;61-92..
- Wandell, BA. Foundations of Vision. Sinauer Associates, Sunderland, Mass. 1995
- Ehsaei A, Chisholm CM, Pacey IE, Mallen EA. Off-axis partial coherence interferometry in myopes and emmetropes. Ophthalmic Physiol Opt. 2013;33(1):26-34.
- Erdinest N, London N, Lavy I, et al. Peripheral defocus and myopia management: a mini-review. Korean J Ophthalmol. 2023;37(1):70-81.
- Hiraoka T, Okamoto C, Ishii Y, et al. Contrast sensitivity function and ocular higher-order aberrations following overnight orthokeratology. Invest Ophthalmol Vis Sci. 2007;48(2):550-6.
- Rozema JJ. Refractive development I: Biometric changes during emmetropisation. Ophthalmic Physiol Opt. 2023;43(3):347-67.
- Yang J, Ouyang X, Fu H, et al. Advances in biomedical study of the myopia-related signaling pathways and mechanisms. Biomed Pharmacother. 2022;145:112472
- Brown DM, Mazade R, Clarkson-Townsend D, et al. Candidate pathways for retina to scleral signaling in refractive eye growth. Exp Eye Res. 2022;219:109071.
- Stone RA, Lin T, Laties AM, Iuvone PM. Retinal dopamine and form-deprivation myopia. Proc Natl Acad Sci US A. 1989;86(2):704-6.
- Tepelus TC, Schaeffel F. Individual set-point and gain of emmetropization in chickens. Vision Res. 2010;50(1):57-64.
- Wildsoet CF, Chia A, Cho P, et al. IMI - Interventions Myopia Institute: Interventions for controlling myopia onset and progression report. Invest Ophthalmol Vis Sci. 2019;60(3):M106-31.
- Wolffsohn JS, Calossi A, Cho P, et al. Global trends in myopia management attitudes and strategies in clinical practice - 2019 Update. Cont Lens Anterior Eye. 2020;43(1):9-17.
- Cherng-Hui Yip, V. Chen-Wei Pan, Xiao-Yu Lin, et al. The relationship between growth spurts and myopia in Singapore children. Invest Ophthalmol Vis Sci. 2012;53(13):7961-6.
- Yip FS. Emmetropic eye growth in East Asians and non-East Asians. Ophthalmic Physiol Opt. 2023;43(6):1412-8.
- Bullimore MA, Ritchey ER, Shah S, et al. The risks and benefits of myopia control. Ophthalmology. 2021;128(11):1561-79.
- Cruikshank FE, Logan NS. Optical 'dampening' of the refractive error to axial length ratio: implications for outcome measures in myopia control studies. Ophthalmic Physiol Opt. 2018;38(3):290-7.
- Chua WH, Balakrishnan V, Chan YH, et al. Atropine for the treatment of childhood myopia. Ophthalmology. 2006;113:2285-91
- Anhchuong Le, Bickel N. Mukesh, et al. Risk Factors Associated with the Incidence of Open-Angle Glaucoma: The Visual Impairment Project. Invest Ophthalmol Vis Sci. 2003;44(9):3783-9.
- Tideman JWL, Polling JR, Vingerling JR, et al. Axial length growth and the risk of developing myopia in European children. Acta Ophthalmol. 2018;96(3):301-9.
- Sanz Diez P, Yang LH, Lu MX, et al. Growth curves of myopia-related parameters to clinically monitor the refractive development in Chinese schoolchildren. Graefes Arch Clin Exp Ophthalmol. 2019;257(5):1045-53.
- Lanca C, Pang CP, Grzybowski A. Effectiveness of myopia control interventions: A systematic review of 12 randomized control trials published between 2019 and 2021. Front Public Health. 2023;11:1125000.
- Lam CSY, Tang WC, Zhang HY, et al. Long-term myopia control effect and safety in children wearing DIMS spectacle lenses for six years. Sci Rep 13, 5475 (2023).
- Li X, Huang Y, Yin Z, et al. Myopia control efficacy of spectacle lenses with aspherical lenslets: results of a three-year follow-up study. Am J Ophthalmol. 2023;253:160-8.
- Chalberg T, Laughton D, Hill J, et al. Control of Myopia Using Diffusion Optics Spectacle Lenses: Efficacy and Safety Study (CYPRESS) 42-month results. ARVO 2023 Annual Meeting. Invest Ophthalmol Vis Sci. 2023;64(5092).
- Liu X, Wang P, Xie Z, et al. One-year myopia control efficacy of cylindrical annular refractive element spectacle lenses. Acta Ophthalmol. 2023;101(6):651-7.
- Sánchez-Tena MÁ, Cleva JM, Villa-Collar C, et al. Effectiveness of a spectacle lens with a specific asymmetric myopic peripheral defocus: 12-month results in a Spanish population. Children (Basel). 2024;11(2):177.
- Tarutta EP, Proskurina OV, Tarasova NA, et al. Long-term results of perifocal defocus spectacle lens correction in children with progressive myopia. Vestn Oftalmol. 2019;135(5):46-53.
- Gregory, Hannah R. Nti, Augustine N. et al. Visual performance of center-distance multifocal contact lenses fit using a myopia control paradigm. Optom Vis Sci. 2021;98(3):272-9.
- Singh S, Tian E. Comparing distance-center and near-center multifocal soft contact lenses for myopia control. Invest Ophthalmol Vis Sci. 2022;63(7):260-A0114.
- Jones L, Drobe B, González-Méjome JM, et al. IMI - Industry guidelines and ethical considerations for myopia control report. Invest Ophthalmol Vis Sci. 2019;60(3):M161-83.
- Cheng X, Xu J, Brennan NA. Randomized trial of soft contact lenses with novel ring focus for controlling myopia progression. Ophthalmol Sci. 2022;3(1):100232.
- Díaz-Gómez S, Burgos-Martínez M, Sankaridurg P, et al. Two-year myopia management efficacy of extended depth of focus soft contact lenses (MYLO) in Caucasian children. Am J Ophthalmol. 2024;260:122-31.
- Chamberlain P, Peixoto-de-Matos SC, Logan NS, et al. A three-year randomized clinical trial of MiSight lenses for myopia control. Optom Vis Sci. 2019;96(8):556-67.
- <https://reviewofnm.com/vti-shares-one-year-data-from-protect-trial-at-aao-2023>. Tuan, KA. O'connor B. et al Poster GSLs 2024.
- Sankaridurg P, Bakaraju RC, Naduvilath T, et al. Myopia control with novel central and peripheral plus contact lenses and extended depth of focus contact lenses: two-year results from a randomized clinical trial. Ophthalmic Physiol Opt. 2019;39(4):294-307.
- Walline JJ, Walker MK, Mutti DO, et al. BLINK Study Group. Effect of high add power, medium add power or single-vision contact lenses on myopia progression in children: The BLINK Randomized Clinical Trial. JAMA. 2020;324(6):571-80.
- Chia A, Chua WH, Cheung YB, et al. Atropine for the Treatment of Childhood Myopia: Safety and Efficacy of 0.5%, 0.1%, and 0.01% Doses (Atropine for the Treatment of Myopia 2). Ophthalmology. 2012;119(2):347-354.
- Li Y, Yip M, Ning Y, et al. Topical Atropine for childhood Myopia Control: The Atropine Treatment Long-Term Assessment Study. JAMA Ophthalmol. 2024;142(1):15-23.
- Zhang XJ, Zhang Y, Yip BHK, et al. Five-Year Clinical Trial of the Low-Concentration Atropine for Myopia Progression (LAMP) Study: Phase 4 Report. Ophthalmology. 2024:S0161-6420(24)00190-8.
- Klaver C, Polling JR; Erasmus Myopia Research Group. Myopia management in the Netherlands. Ophthalmic Physiol Opt. 2020;40(2):230-40.
- Repka MX, Weise KK, Chandler DL, et al. Pediatric Eye Disease Investigator Group. Low-dose 0.01% Atropine eye drops vs. placebo for myopia control: a randomized clinical trial. JAMA Ophthalmol. 2023;141(8):756-65.
- Ha A, Kim SJ, Shim SR, et al. Efficacy and safety of eight Atropine concentrations for myopia control in children: a network meta-analysis. Ophthalmology. 2022;129(3):322-3.
- Jeon GS, Hong IH, Lee JH, et al. Analysis of treatment response about low-dose (0.01%) atropine eye-drops in myopic children. Eur J Ophthalmol. 2022;32(4):2011-7.
- Zadnik K, Schulman E, Flitcroft I, et al. CHAMP Trial Group Investigators. Efficacy and safety of 0.01% and 0.02% Atropine for the treatment of pediatric myopia progression over three years: a randomized clinical trial. JAMA Ophthalmol. 2023;141(10):990-9.
- Pucker A. Stating the facts about combination myopia management treatments. Optometry Times. <https://www.optometrytimes.com/view/stating-the-facts-about-combination-myopia-management-treatments>. May 24, 2023. Accessed May 26, 2024.
- Nucci P, Lembo A, Schiavetti I, et al. A comparison of myopia control in European children and adolescents with defocus incorporated multiple segments (DIMS) spectacles, atropine and combined DIMS/atropine. PLoS One. 2023;18(2):e0281816.
- Wang Z, Wang P, Jiang B, et al. The efficacy and safety of 0.01% atropine alone or combined with orthokeratology for children with myopia: A meta-analysis. PLoS One. 2023;18(7):e0282286.
- Jones JH, Mutti DO, Jones-Jordan LA, Walline JJ. Effect of combining 0.01% Atropine with soft multifocal contact lenses on myopia progression in children. Optom Vis Sci. 2022;99(5):434-42.
- Wang Q, Banerjee S, So C, et al. The effect of low-dose Atropine on alpha ganglion cell signaling in the mouse retina. Front Cell Neurosci. 2021;15:664491.
- Yam J, Li FF, Zhang X, et al. Low concentration atropine for myopia progression (LAMP) Phase 3: efficacy of 0.05%, 0.025%, and 0.01% atropine eye drops over three years and the rebound phenomenon after cessation of treatment. ARVO 2020. Abstract 1133.

tyrvaya[®]
(varenicline solution)
nasal spray 0.03 mg

FOR THE SIGNS
& SYMPTOMS OF
DRY EYE DISEASE

SHE'S LOOKING TO YOU FOR A
DIFFERENT APPROACH WHEN
ARTIFICIAL TEARS ARE NOT ENOUGH.¹

BEFORE ANOTHER DROP

ACTIVATE REAL TEARS

WITH THE FIRST AND ONLY NASAL
SPRAY FOR DRY EYE²



Tyrvaya[®] is not another drop

It's an **ocular surface-sparing** nasal spray.²



Activates real, basal tears

Tyrvaya[®] is believed to work by activating the trigeminal parasympathetic pathway resulting in **basal tear production**.^{2*}



Real tears, real fast

In 2 clinical trials with **mild, moderate, and severe** dry eye disease patients, Tyrvaya increased tear production from baseline by **≥10 mm in Schirmer's Test Score (STS) in nearly 50% of patients at week 4**, with increased tears seen as early as the first dose and over 12 weeks.^{2-8†}

SEE WHAT
TYRVAYA
CAN DO



*The exact mechanism of action is unknown.

†Tyrvaya was evaluated across 3 randomized, vehicle-controlled, double-masked studies in which adults aged ≥22 years diagnosed with dry eye disease received 1 spray of either active drug or vehicle in each nostril twice daily. Primary endpoint: % of patients with mean change from baseline in STS of ≥10 mm at week 4 in ONSET-1: 52% with Tyrvaya (n=48) vs 14% with vehicle (n=43) and in ONSET-2: 47% with Tyrvaya (n=260) vs 28% with vehicle (n=252). Onset of action: mean change from baseline in STS ~5 minutes after first dose (not a prespecified endpoint) in ONSET-1 was 17.2 mm with Tyrvaya (n=48) vs 4.0 mm with vehicle (n=43) and in ONSET-2 was 16.5 mm with Tyrvaya (n=260) vs 6.9 mm with vehicle (n=251). Observed data. On Day 1 in clinical studies, a baseline anesthetized Schirmer's test was performed. Tyrvaya was then administered concurrently with Schirmer's test. Schirmer's test results were measured at ~5 minutes. Mean change from baseline in STS at week 12 in the MYSTIC study was 10.8 mm with Tyrvaya vs 6.0 mm with vehicle. Limitations: Ex-US, single-center study. All subjects were Hispanic or Latino. Tyrvaya group mean baseline STS 5.5 mm (n=41); vehicle group mean baseline STS 5.3 mm (n=41). All randomized and treated patients were included in the analysis and missing data were imputed using last-available data.²⁻⁸
See references on next page.

Indication

Tyrvaya[®] (varenicline solution) nasal spray is indicated for the treatment of the signs and symptoms of dry eye disease.

Important Safety Information

The most common adverse reaction reported in 82% of patients was sneezing. Events that were reported in 5-16% of patients were cough, throat irritation, and instillation-site (nose) irritation.

Please see Brief Summary of Prescribing Information on the next page and the full Prescribing Information at Tyrvaya-pro.com.

BRIEF SUMMARY: Consult the full Prescribing Information for complete product information available at www.tyrvaya-pro.com.

INDICATIONS AND USAGE

TYRVAYA® (varenicline solution) nasal spray is a cholinergic agonist indicated for the treatment of the signs and symptoms of dry eye disease.

ADVERSE REACTIONS

Clinical Trials Experience: Because clinical trials are conducted under widely varying conditions, adverse reaction rates observed in the clinical trials of a drug cannot be directly compared to rates in the clinical trials of another drug and may not reflect the rates observed in practice.

In three clinical trials of dry eye disease conducted with varenicline solution nasal spray, 349 patients received at least 1 dose of TYRVAYA. The majority of patients had 31 days of treatment exposure, with a maximum exposure of 105 days.

The most common adverse reactions reported in 82% of TYRVAYA treated patients was sneezing. Other common adverse reactions that were reported in >5% of patients include cough (16%), throat irritation (13%), and instillation-site (nose) irritation (8%).

USE IN SPECIFIC POPULATIONS

Pregnancy: Risk Summary: There are no available data on TYRVAYA use in pregnant women to inform any drug associated risks. In animal reproduction studies, varenicline did not produce malformations at clinically relevant doses.

All pregnancies have a risk of birth defect, loss, or other adverse outcomes. In the US general population, the estimated background risk of

major birth defects and miscarriage in clinically recognized pregnancies is 2% to 4% and 15% to 20%, respectively.

Data: Animal Data: Pregnant rats and rabbits received varenicline succinate during organogenesis at oral doses up to 15 and 30 mg/kg/day, respectively. While no fetal structural abnormalities occurred in either species, maternal toxicity, characterized by reduced body weight gain, and reduced fetal weights occurred in rabbits at the highest dose (4864 times the MRHD on a mg/m² basis).

In a pre- and postnatal development study, pregnant rats received up to 15 mg/kg/day of oral varenicline succinate from organogenesis through lactation. Maternal toxicity, characterized by a decrease in body weight gain, was observed at 15 mg/kg/day (1216 times the MRHD on a mg/m² basis). Decreased fertility and increased auditory startle response occurred in offspring at the highest maternal dose of 15 mg/kg/day.

Lactation: Risk summary: There are no data on the presence of varenicline in human milk, the effects on the breastfed infant, or the effects on milk production. In animal studies varenicline was present in milk of lactating rats. However, due to species-specific differences in lactation physiology, animal data may not reliably predict drug levels in human milk.

The lack of clinical data during lactation precludes a clear determination of the risk of TYRVAYA to an infant during lactation; however, the developmental and health benefits of breastfeeding should be considered along with the mother's clinical need for TYRVAYA and any potential adverse effects on the breastfed child from TYRVAYA.

Pediatric Use: Safety and efficacy of TYRVAYA in pediatric patients have not been established.

Geriatric Use: No overall differences in safety or effectiveness have been observed between elderly and younger adult patients.

References: 1. Jones L, Downie LE, Korb D, et al. *Ocul Surf.* 2017;15(3):575-628. 2. Tyrvaya. Prescribing Information. Oyster Point Pharma; 2021. 3. Oyster Point Pharma. Data on file. OPP-002 (ONSET-1) Clinical Study Report. August 4, 2019. 4. Oyster Point Pharma. Data on file. OPP-101 (ONSET-2) Interim Clinical Study Report. October 13, 2020. 5. Quiroz-Mercado H, Hernandez-Quintela E, Chiu KH, Henry E, Nau JA. *Ocul Surf.* 2022;24:15-21. 6. Wirta D, Torkildsen GL, Boehmer B, et al. *Cornea.* 2022;4(10):1207-1216. 7. Wirta D, Vollmer P, Paauw J, et al. *Ophthalmology.* 2021;0(0):379-387. 8. Oyster Point Pharma. Data on file. OPP-004 (MYSTIC) Clinical Study Report. March 19, 2020.

Manufactured for Oyster Point Pharma, Inc. 202 Carnegie Center, Suite 106, Princeton NJ 08540. For more information, visit www.tyrvaya-pro.com. To report an adverse event, contact 1-877-EYE-0123.

AMD STAGING: MORE THAN WET VS. DRY

Various imaging biomarkers can help you get a truer sense of disease status and predict a patient's risk of progression. Here's what to look out for.



BY STEVEN FERRUCCI, OD, AND
MOHAMMAD RAFIEETARY, OD
NORTH HILLS, CA; GERMANTOWN, TN

In the past, the primary question eyecare clinicians sought to answer when evaluating a patient with age-related macular degeneration (AMD) was, “Is it dry or wet?” When using OCT to assess patients back then, we were mostly focused on detecting subretinal or intraretinal fluid—the telltale sign that a patient converted from dry to wet AMD—which would necessitate an urgent referral to a retina specialist for treatment with intravitreal anti-VEGF. However, with advancements in OCT, as well as increased knowledge about the natural history of AMD and geographic atrophy (GA), we now know of other, more subtle findings on OCT that can help us characterize a patient's risk of progressing to advanced AMD. Furthermore, the “dry vs. wet” conceptualization is overly simplistic and should be replaced by a more nuanced understanding of AMD.

In screening for this disease, we also must consider that GA (advanced dry

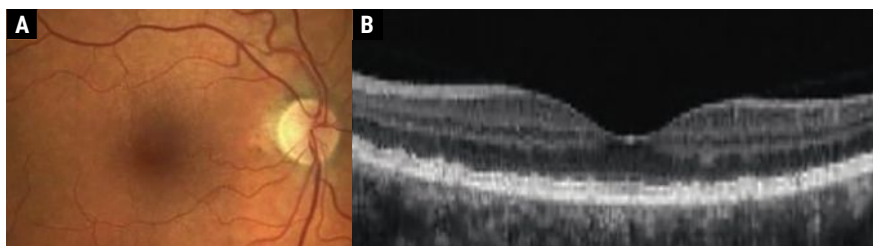


Fig. 1a-b. Early AMD characterized by medium-sized drusen (63µm to 125µm).

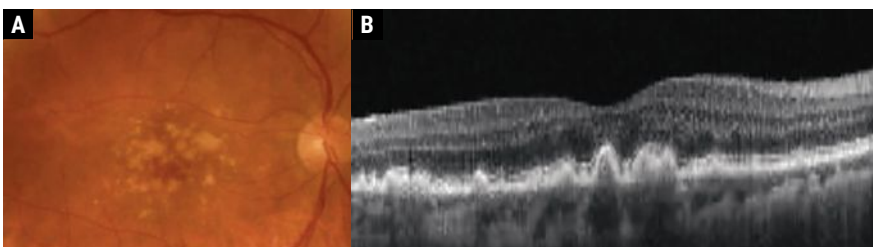


Fig. 2a-b. Intermediate AMD demonstrating large-sized drusen (>125µm).

AMD) and macular neovascularization (MNV; neovascular AMD) can coexist. This has shown to be more evident in histologic vs. clinical examination.¹ One study using histological examination found that 22 eyes of 63 patients with clinical bilateral choroidal neovascularization (CNV) also had areas of retinal pigment epithelium (RPE) atrophy (GA), and another found that 86 eyes

of 760 with a pre-mortem diagnosis of AMD demonstrated both CNV and RPE atrophy.^{2,3} These studies verify that coexistence of MNV and GA is not uncommon in eyes with AMD, which may require a shift in the management approach.

In this article, we will discuss how to properly stage macular degeneration and identify biomarkers for dry AMD

About the authors

Dr. Ferrucci is currently chief of optometry at the Sepulveda VA Ambulatory Care Center and Nursing Home in North Hills, CA. He is also a professor at the Southern California College of Optometry at Marshall B. Ketchum University. Dr. Ferrucci is a fellow of the American Academy of Optometry (AAO), as well as a fellow and past president of the Optometric Retina Society (ORS). He serves on the advisory board and/or speakers bureau for Apellis, Astellas, I-Care, LKC Technologies, Science Based Health and Visible Genomics. **Dr. Rafieetary** is a consultative optometric physician at the Charles Retina Institute in Germantown, TN. He is also a fellow of the AAO and ORS. Dr. Rafieetary is on advisory boards for Heidelberg Engineering, Optos, Regeneron, Notal Vision and Cardinal Health.

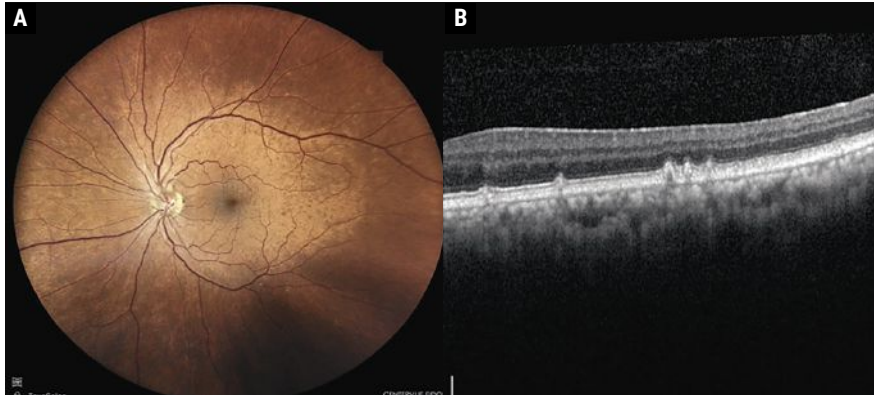


Fig. 3a-b. Fundus photo and OCT demonstrating cuticular drusen.

on OCT. Additionally, we also highlight some new findings in neovascular AMD that may hold predictive value.

AMD Grading Scales

Taking it back to the basics, the hallmark sign of AMD is drusen, which are yellow-white deposits of extracellular debris between the basal lamina of the RPE and Bruch's membrane. Drusen size was used in the original AREDS study to stage AMD into one of four categories (*Figures 1a, 1b, 2a and 2b*):⁴

- Category 1: Early AMD characterized by fewer than five small drusen, each below 63µm in size.

- Category 2: Mild AMD defined as multiple small drusen, a single intermediate-sized drusen from 63µm to 124µm or RPE changes.

- Category 3: Moderate AMD characterized by one large drusen greater

than 125µm, extensive intermediate drusen or GA non-centrally.

- Category 4: Advanced AMD defined as more than one large drusen or GA centrally.

An AREDS simplified scale is also in wide clinical use. In this system, each eye is assigned one risk factor for the presence of one or more large drusen and one risk factor for the presence of any pigment abnormality. Risk factors are added up for both eyes and graded on a five-step scale (0-4). The advantage of this system is that the five-year risk of developing advanced AMD in at least one eye correlates with an easily remembered sequence (*Table 1*): zero factors, 0.5%; one factor, 3%; two factors, 12%; three factors, 25%; and four factors, 50%.⁵

Many eyecare providers prefer the Beckman Classification System,

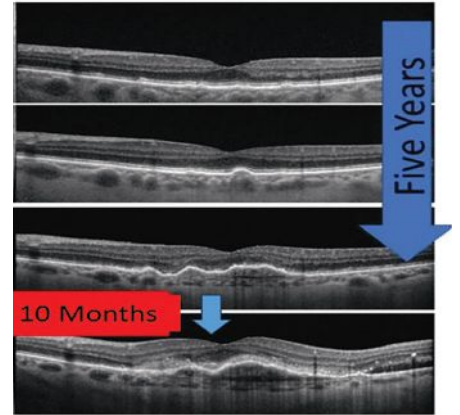


Fig. 4. This series of OCT images demonstrates slow progression of AMD from early to intermediate over five years; however, with increased drusen volume and development of pigment epithelial detachments, the patient converted from dry to neovascular AMD in less than a year.

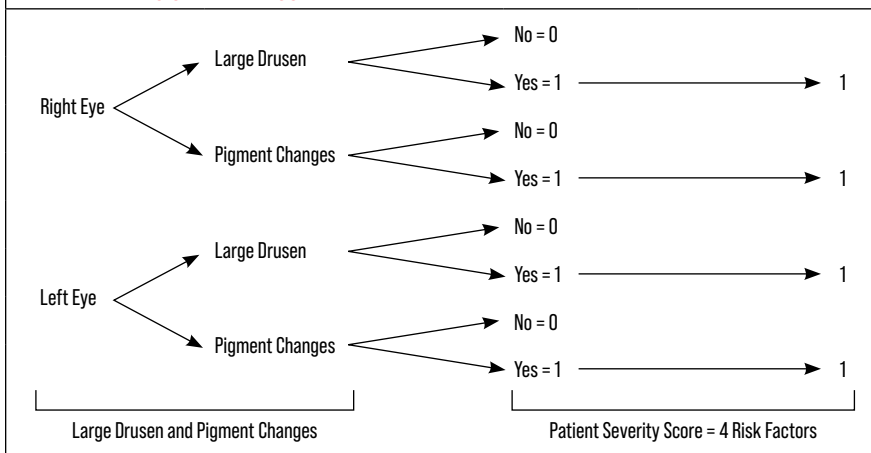
developed in 2013, which requires only a clinical examination or color fundus images to classify AMD. This system has five stages, ranging from no apparent aging changes to late AMD, based primarily on drusen size and pigmentary changes (*Table 2*).⁶

Drusen

There are several different types of drusen defined within the literature. Hard drusen appear as round, discrete, yellow-white spots, typically measure less than 63µm and are present in approximately 80% of the population, thought to be a physiological sign of aging. Soft drusen appear more ill-defined with non-discrete borders and typically measure greater than 63µm. Studies show soft drusen affect approximately 26% of people over the age of 70. Cuticular drusen are small in diameter (typically 50µm to 75µm), yellow, triangular deposits below the RPE, often with a saw-tooth appearance (*Figures 3a and 3b*).^{7,8}

Early studies evaluating color fundus photos of drusen have given some insight into important risk factors for progression to advanced AMD. These studies concluded that large, soft confluent drusen as well as pigmentary abnormalities relay higher risk. Fellow

TABLE 1. AREDS SIMPLIFIED SCALE⁵



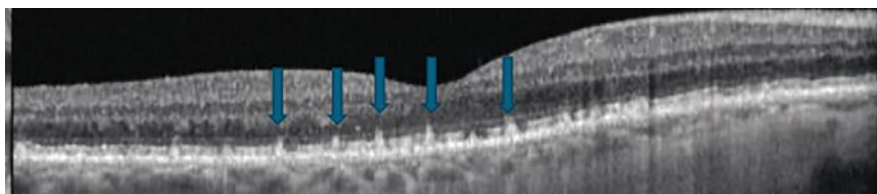


Fig. 5. OCT showing subretinal drusenoid deposits, also known as reticular pseudodrusen.

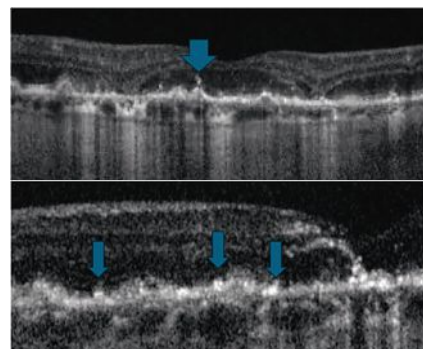


Fig. 6. Hyperreflective foci on OCT.

TABLE 2. BECKMAN CLASSIFICATION OF AMD⁶

No apparent aging changes	<ul style="list-style-type: none"> • No drusen • No AMD pigment abnormalities
Normal aging changes	<ul style="list-style-type: none"> • Small drusen <63µm • No AMD pigment abnormalities
Early AMD	<ul style="list-style-type: none"> • Medium drusen >63µm to <125µm • No AMD pigment abnormalities
Intermediate AMD	<ul style="list-style-type: none"> • Large drusen >125µm and/or AMD pigment abnormalities
Late AMD	<ul style="list-style-type: none"> • Neovascular AMD and/or GA

eye status to predict risk in the second eye is also important. Therefore, early risk calculators have used drusen size, the presence or absence of pigment abnormalities, as well as fellow eye status to convey risk of progression to advanced disease.⁵

Newer studies have evaluated several additional drusen characteristics associated with increased risk. Drusen volume/area, drusen height and drusen length have all been associated with increased risk of progression to advanced AMD. Increased drusen volume has been associated with increased risk to either neovascular AMD or GA, while increase in drusen height has

been associated with progression to atrophic AMD. Lastly, drusen length appears to have a positive correlation with increased risk of conversion to neovascular AMD.⁹⁻¹¹ Although in early AMD these changes may be slow, once drusen volume reaches 0.03mm³ the risk of developing late AMD is four-times higher when compared to those with smaller drusen (Figure 4).¹²

Drusen regression—that is, the disappearance of drusen—is also a risk factor for progression to advanced disease. The AREDS study reported that 82% of eyes that developed significant atrophic changes had preceding drusen regression. Other studies revealed that in patients with early to intermediate disease, drusen regression occurred in 44% of eyes and preceded advanced AMD, including both GA and neovascular AMD.¹³

Reticular Pseudodrusen

Also called subretinal drusenoid deposits, reticular pseudodrusen (RPD) are subretinal, granular, hyperreflective material above the RPE. They are often located in the superior macula or close to the superotemporal arcades. On OCT, they have a specific growth pattern characterized by invasion into the

ellipsoid zone followed by regression. RPD are best appreciated on infrared reflectance or spectral domain OCT and perhaps worst visualized with color fundus photography (Figure 5).¹⁴

RPD are found to be present in higher numbers in patients with AMD, present in 4.6% of eyes with no AMD, 13.0% in early AMD, 62.6% with intermediate AMD, 34.6% with atrophic AMD and 8.1% with wet AMD. Further, these studies reveal that presence of RPD is associated with an additional two- to sixfold increased risk of progression to neovascular AMD or central GA, with the risk even higher for RPD located outside the macula.¹⁵

Hyperreflective Foci

These appear as well-defined lesions within the neurosensory retina on OCT. They can appear as solitary lesions approximately 20µm to 40µm in diameter or in clusters. Their exact pathogenesis is somewhat debatable, although most researchers now believe they represent anteriorly migrating RPE cells as well as possible disaggregated photoreceptors (Figure 6).¹⁶⁻¹⁸

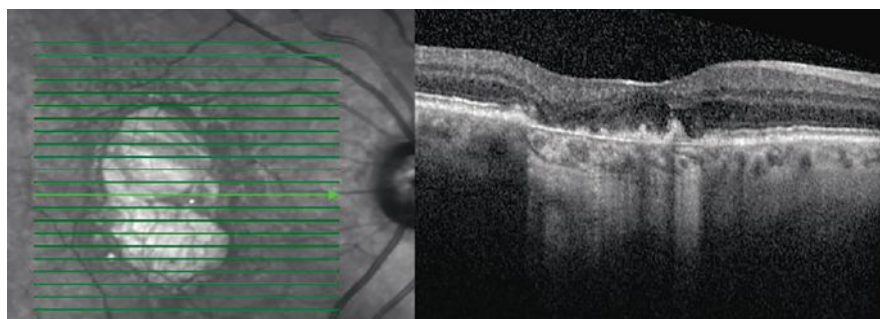


Fig. 7. Hyper-transmission defect on OCT.

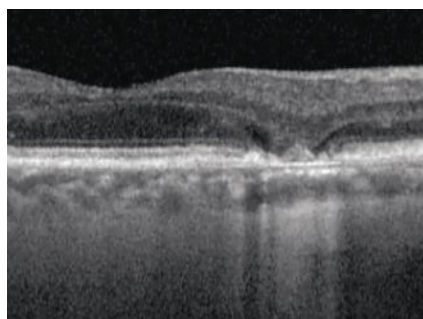


Fig. 8. Subsidence from collapsed drusen.

Look for choroidal hypertransmission, a marker of Geographic Atrophy (GA) on OCT^{1*}

- While BCVA is poorly correlated to lesion size, visual function continues to decline as lesions grow^{2,3}
- It is critical to recognize GA and refer patients in a timely manner, as disease progression is relentless and irreversible^{1,3-7}

Learn more about identifying GA
at RecognizeAndReferGA.com



**RECOGNIZE
AND REFER**

*GA is defined by atrophic lesions, resulting from loss of photoreceptors, RPE, and underlying choriocapillaris. This results in a choroidal hypertransmission defect on OCT.^{1,4,9}
BCVA=best-corrected visual acuity; OCT=optical coherence tomography; RPE=retinal pigment epithelium.

References: 1. Fleckenstein M, Mitchell P, Freund KB, et al. The progression of geographic atrophy secondary to age-related macular degeneration. *Ophthalmology*. 2018;125(3):369-390. doi:10.1016/j.ophtha.2017.08.038. 2. Heier JS, Pieramici D, Chakravarthy U, et al. Visual function decline resulting from geographic atrophy: results from the chroma and spectri phase 3 trials. *Ophthalmol Retina*. 2020;4(7):673-688. doi:10.1016/j.oret.2020.01.019. 3. Sunness JS, Margalit E, Srikumaran D, et al. The long-term natural history of geographic atrophy from age-related macular degeneration: enlargement of atrophy and implications for interventional clinical trials. *Ophthalmology*. 2007;114(2):271-277. 4. Boyer DS, Schmidt-Erfurth U, van Lookeren Campagne M, Henry EC, Brittain C. The pathophysiology of geographic atrophy secondary to age-related macular degeneration and the complement pathway as a therapeutic target. *Retina*. 2017;37(5):819-835. doi:10.1097/iae.0000000000001392. 5. American Optometric Association. AOA Comprehensive adult eye and vision examination. *Quick Reference Guide: Evidence-Based Clinical Practice Guideline*. 1st ed. Accessed July 13, 2023. https://www.aoa.org/documents/EBO/Comprehensive_Adult_Eye_and_Vision_%20QRG.pdf. 6. Holz FG, Strauss EC, Schmitz-Valckenberg S, van Lookeren Campagne M. Geographic atrophy: clinical features and potential therapeutic approaches. *Ophthalmology*. 2014;121(5):1079-1091. doi:10.1016/j.ophtha.2013.11.023. 7. Lindblad AS, Lloyd PC, Clemons TE, et al; Age-Related Eye Disease Study Research Group. Change in area of geographic atrophy in the age-related eye disease study: AREDS report number 26. *Arch Ophthalmol*. 2009;127(9):1168-1174. doi:10.1001/archophthalmol.2009.198. 8. van Lookeren Campagne M, LeCouter J, Yaspan BL, Ye W. Mechanisms of age-related macular degeneration and therapeutic opportunities. *J Pathol*. 2014;232(2):151-164. doi:10.1002/path.4266. 9. Chakravarthy U, Bailey CC, Scanlon PH, et al. Progression from early/intermediate to advanced forms of age-related macular degeneration in a large UK cohort: rates and risk factors. *Ophthalmol Retina*. 2020;4(7):662-672.

Apellis

The APPELLIS® name and logo is a registered trademark of Apellis Pharmaceuticals, Inc.
©2023 Apellis Pharmaceuticals, Inc. 8/23 US-GA-2300089 v1.0

Whatever their exact pathogenesis, hyperreflective foci are considered a strong predictor of AMD progression. The AREDS 2 study revealed that patients with hyperreflective foci at baseline have a fivefold increased risk of progression to GA at two years compared with controls. Correlation with neovascular AMD is not as well demonstrated.¹⁹

Hyperreflective foci within drusen may also increase the risk for atrophy. It is theorized that this represents increased heterogeneity of the internal drusen structure and may represent softening of the drusen. This internal softening may lead to a greater likelihood of collapse and progression to atrophy.²⁰

Hyper-transmission Defects

GA is an advanced form of dry AMD that results in progressive and irreversible loss of all retinal tissues, including the photoreceptors, RPE and choriocapillaris. An OCT feature that is seen in patients with GA is hyper-transmission defects. These defects appear as bright regions in the choroid due to increased penetrance of light secondary to missing RPE and other retinal layers. Other terms for these defects—including waterfall, barcode or sub-RPE illumination—have fallen out of favor due to the preferred term of hyper-transmission. Researchers have found that these defects are seen as patients progress from intermediate to late-stage GA (Figure 7).²¹

Based on OCT findings, GA can be classified as either incomplete RPE and outer retinal atrophy (iRORA), which describes partial atrophic loss of the ellipsoid and interdigitation zones as well as the RPE monolayer, or complete RPE and outer retinal atrophy (cRORA), describing a total loss of photoreceptors and the RPE.²²

Subsidence

Another feature that may predict advancing GA is subsidence of the inner nuclear layer and outer plexiform layer, with or without a hyporeflexive wedge within the outer plexiform layer. Both these signs indicate a loss of the precep-

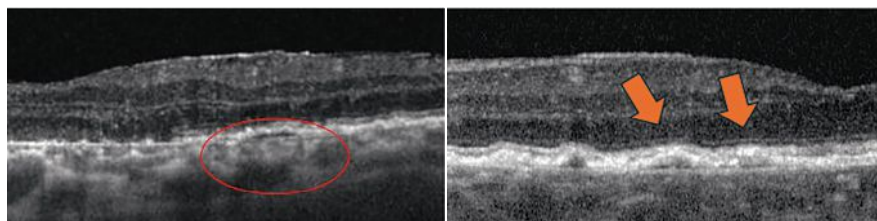


Fig. 9. Double-layer sign is seen within the circle and marked by arrows in these two OCT cross-sections.

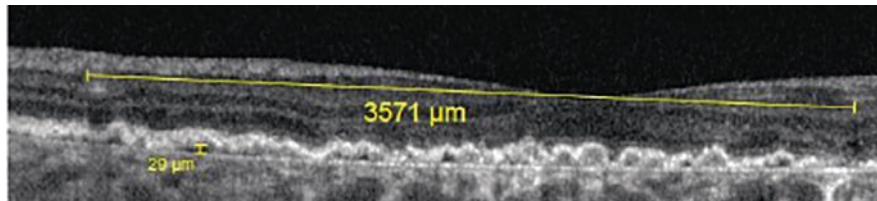


Fig. 10. This shallow irregular RPE elevation was more than 3,500μm in length and only 29μm in height.

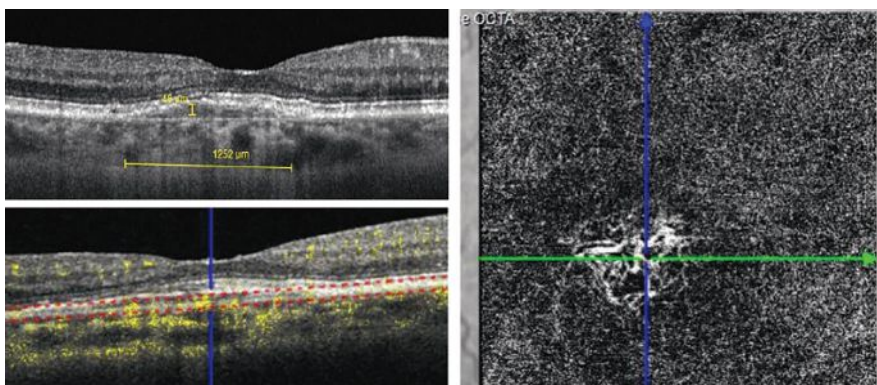


Fig. 11. Comparison of a shallow irregular RPE elevation with OCT B-scan to OCT-A, which reveals nonexudative MNV.

tor layers and precede the development of frank GA (Figure 8).²³

Fundus Autofluorescence (FAF)

This noninvasive imaging technique has been shown to be helpful in the diagnosis and management of a myriad of retinal diseases, most notably GA. FAF uses a series of various filters and wavelengths to look for lipofuscin, a byproduct of retinal cell death that is found in many age-related eye diseases, such as GA.²⁴ This provides a very useful tool to look for areas of atrophy, which will appear hypofluorescent or dark, as well as hyperfluorescent areas, typically on the border of the GA lesion, which indicates an active lesion that may be more likely to progress. Therefore, lesions of atrophy surrounded by a ring of hyperfluorescence should be monitored more closely for

lesion growth or referred for treatment with the newer complement inhibitor drugs for GA. New studies are also evaluating different patterns of FAF to see if they hold prognostic value for lesions more likely to progress.²⁵

MNV

This finding is associated with neovascular AMD and used to be commonly referred to as CNV. However, since choroidal neovascular membranes may develop in locations other than the macula, such as in the peripapillary area or peripheral retina, macular neovascular membrane or MNV are more descriptive terms for CNV associated with neovascular AMD. This terminology is also more appropriate in neovascular AMD since the neovascularization does not always originate from the choroid.²⁶

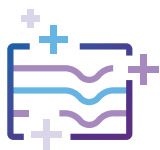FULLY-FEATURED OCT WITH ONE-TOUCH ACQUISITION

Maestro2

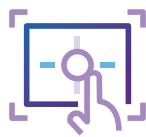The fast, affordable,
automated OCT and
fundus camera.



KEY FEATURES



High Quality Imaging
Clear, detailed OCT and
true color fundus images



Single-Touch automatic
alignment, focus,
optimizing and capturing



**The Hood Report for
Glaucoma** enables you to
make a quick visual field
assessment for your patients.



Connect with your EMR
to create patient worklists
conveniently in one
centralized place.

OVER 20,000 MAESTRO UNITS SOLD WORLDWIDE



[Scan Here To Learn More](#)

 **TOPCON** Healthcare

©2023 Topcon Healthcare | [topconhealthcare.com](https://www.topconhealthcare.com)

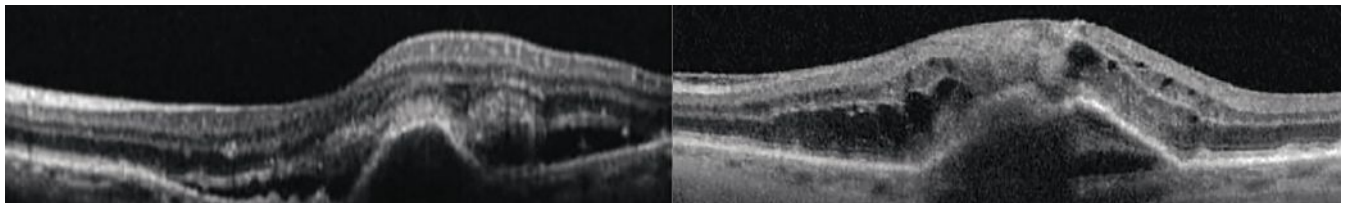


Fig. 12. Two case examples of type 1 MNV showing a pigment epithelial detachment and sub- and intraretinal fluid.

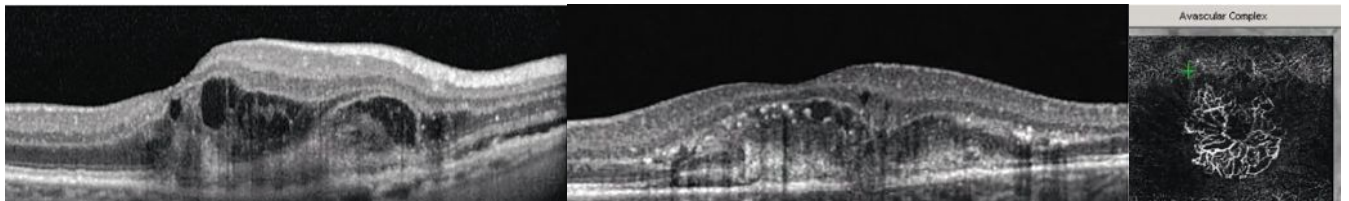


Fig. 13. These two examples of type 2 MNV show lesions that penetrated Bruch's membrane and are invading the subretinal space. The OCT-A on the right shows the abnormal vessel growth causing the morphological damage seen in the corresponding OCT cross-section.

In addition to increased drusen volume as previously mentioned, there are other predictive and diagnostic biomarkers for neovascular AMD on OCT B-scan. Double-layer sign is an OCT cross-sectional finding reported as small, shallow and irregular elevation of the RPE from Bruch's membrane that is associated with AMD and pachychoroid spectrum (Figure 9).²⁷ When these lesions are >1,000µm in length and <100µm in height, they are referred to as shallow irregular RPE elevation, or SIRE (Figure 10).²⁷

Double-layer sign and SIRE are considered highly predictive of presence or progression of exudative as well as non-exudative MNV.^{28,29} In the presence of double-layer sign and SIRE—and the absence of typical biomarkers of exudative MNV such as sub- or intraretinal fluid—OCT angiography is useful to rule out nonexudative MNV (Figure 11).³⁰

OCT also is crucial in the detection of nonexudative MNV. This condition can be broken down into the following three types:

- Type 1: The growth of vessels initiates from the choriocapillaris advancing in the sub-RPE space detected by varying form of pigment epithelial detachments (Figure 12).³¹
- Type 2: Abnormal vessels begin in the choroid and progress into the subretinal space by breaking through Bruch's membrane.³¹ Subretinal lesions of various sizes can be detected with possible presence of retinal hemorrhages, sub- and/or intraretinal fluid or exudates (Figure 13).³⁰
- Type 3 (retinal angiomatous proliferation): Neovascularization begins in the retinal circulation, often from the deep capillary plexus advancing to the outer retina (Figure 14).^{26,31}

Takeaways

All these advancements in imaging increase our knowledge of AMD, help convey risk for progression and help identify those patients in need of earlier referral for treatment. These advances may also help develop more targeted treatments based on certain morphologic factors discovered through imaging. AI tools are currently being developed that hopefully will aid the ability to screen for certain factors and help develop models for disease progression, aiding with clinical decision-making. Until then, it behooves the clinician to spend extra time studying images for these more subtle biomarkers of AMD progression and realize there are more questions to answer than merely, “Is it dry or wet?” ■

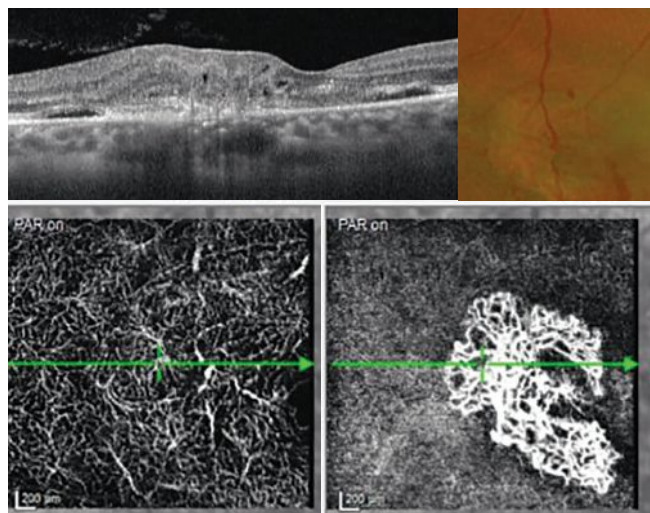


Fig. 14. These images demonstrate a type 3 MNV or a retinal angiomatous proliferation lesion on OCT. In the color fundus photograph (top right), the collateral retinal vessels are seen in the center on the neovascular lesion. The OCT-A images show capillary telangiectasia in the deep vascular plexus and the large MNV at the avascular level (bottom right).

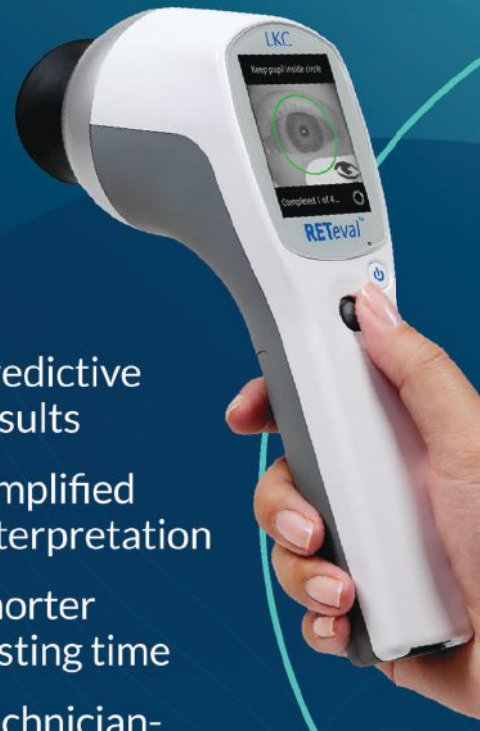1. Kaszubski P, Ami TB, Saade C, Smith RT. Geographic atrophy and choroidal neovascularization in the same eye: a review. *Ophthalmic Res.* 2016;55(4):185-93.
2. Green WR, Key SN 3rd. Senile macular degeneration: a histopathologic study. *Trans Am Ophthalmol Soc.* 1977;75:180-254.
3. Green WR, Enger C. Age-related macular degeneration histopathologic studies. The 1992 Lorenz E. Zimmerman Lecture. *Ophthalmology.* 1993;100(10):1519-35.
4. Age-Related Eye Disease Study Research Group. The AREDS system for classifying age-related macular degeneration from stereoscopic color fundus photographs: the Age-Related Eye Disease Study Report Number 6. *Am J Ophthalmol.* 2001;132(5):668-81.
5. Ferris FL, Davis MD, Clemons TE, et al; Age-Related Eye Disease Study (AREDS) Research Group. A simplified severity scale for age-related macular degeneration: AREDS Report No. 18. *Arch Ophthalmol.* 2005;123(11):1570-4.

6. Ferris FL 3rd, Wilkinson CP, Bird A, et al. Clinical classification of age-related macular degeneration. *Ophthalmology*. 2013;120(4):844-51.
7. Spaide RF, Curcio CA. Drusen characterization with multimodal imaging. *Retina*. 2010;30:1441-54.
8. Chan H, Cougnard-Grégoire A, Delyfer MN, et al. Multimodal imaging of reticular pseudodrusen in a population-based setting: The Alienor Study. *Invest Ophthalmol Vis Sci*. 2016;57(7):3058-65.
9. de Sisternes L, Simon N, Tibshirani R, Leng T, Rubin DL. Quantitative SD-OCT imaging biomarkers as indicators of age-related macular degeneration progression. *Invest Ophthalmol Vis Sci*. 2014;55(11):7093-103.
10. Nathoo NA, Or C, Young M, et al. Optical coherence tomography-based measurement of drusen load predicts development of advanced age-related macular degeneration. *Am J Ophthalmol*. 2014;158(4):757-61.
11. Dieaconescu DA, Dieaconescu IM, Williams MA, Hogg RE, Chakravarthy U. Drusen height and width are highly predictive markers for progression to neovascular AMD. *Invest Ophthalmol Vis Sci*. 2012;53:2910.
12. Adbelfattah N, Zhang H, Boyer D, et al. Drusen volume as a predictor of disease progression in patients with late age-related macular degeneration in the fellow eye. *Invest Ophthalmol Vis Sci*. 2016;57:1839-46.
13. Klein ML, Francis PJ, Ferris FL 3rd, Hamon SC, Clemons TE. Risk assessment model for development of advanced age-related macular degeneration. *Arch Ophthalmol*. 2011;129:1543-50.
14. Xu X, Liu X, Wang X, et al. Retinal pigment epithelium degeneration associated with subretinal drusenoid deposits in age-related macular degeneration. *Am J Ophthalmol*. 2017;175:87-9.
15. Zweifel SA, Imamura Y, Spaide TC, Fujiwara T, Spaide RF. Prevalence and significance of subretinal drusenoid deposits (reticular pseudodrusen) in age-related macular degeneration. *Ophthalmology*. 2010;117:1775-81.
16. Khanifar AF, Koreishi JAI, Toth CA. Drusen ultrastructure imaging with spectral domain optical coherence tomography in age-related macular degeneration. *Ophthalmology*. 2008;115(11):1883-90.
17. Schuman SG, Koreishi AF, Farsiu S, et al. Photoreceptor layer thinning over drusen in eyes with age-related macular degeneration imaged in vivo with spectral-domain optical coherence tomography. *Ophthalmology*. 2009;116(3):488-96.
18. Folgar FA, Chow JH, Farsiu S, et al. Spatial correlation between hyperpigmentary changes on color fundus photography and hyperreflective foci on SD-OCT in intermediate AMD. *Invest Ophthalmol Vis Sci*. 2012;53(8):4626-33.
19. Christenbury JG, Folgar FA, O'Connell RV, et al. Age-related eye disease study 2 ancillary spectral domain optical coherence tomography study group. Progression of intermediate age-related macular degeneration with proliferation and inner retinal migration of hyperreflective foci. *Ophthalmology*. 2013;120:1038-45.
20. Ouyang Y, Heussen FM, Hariri A, et al. Optical coherence tomography-based observation of the natural history of drusenoid lesion in eyes with dry age-related macular degeneration. *Ophthalmology*. 2013;120:2656-65.
21. Shi Y, Yang J, Feuer W, Gregori G, Rosenfeld PJ. Persistent hypertransmission defects on en face OCT imaging as a stand-alone precursor for the future formation of geographic atrophy. *Ophthalmol Retina*. 2021;5(12):1214-25.
22. Guymer RH, Rosenfeld PJ, Curcio CA, et al. Incomplete retinal pigment epithelial and outer retinal atrophy in age-related macular degeneration: classification of atrophy meeting report 4. *Ophthalmology*. 2020;127(3):394-409.
23. Wu Z, Luu CD, Ayton LN, et al. Optical coherence tomography-defined changes preceding the development of drusen-associated atrophy in age-related macular degeneration. *Ophthalmology*. 2014;121(12):2415-22.
24. Sepah YJ, Akhtar A, Sadiq MA, et al. Fundus autofluorescence imaging: fundamentals and clinical relevance. *Saudi J Ophthalmol*. 2014;28(2):111-6.
25. Biarnés M, Arias L, Alonso J, et al. Increased fundus autofluorescence and progression of geographic atrophy secondary to age-related macular degeneration. *The GAIN study*. *Am J Ophthalmol*. 2015;160(2):345-53.
26. Spaide RF, Jaffe GJ, Sarraf D, et al. Consensus nomenclature for reporting neovascular age-related macular degeneration data: consensus on Neovascular Age-Related Macular Degeneration Nomenclature Study Group. *Ophthalmology*. 2020;127(5):616-36.
27. Sheth J, Anantharaman G, Chandra S, Sivaprasad S. Double-layer sign on spectral domain optical coherence tomography in pachychoroid spectrum disease. *Indian J Ophthalmol*. 2018;66(12):1796-1801.
28. Csincsik L, Muldrew KA, Bettiol A, et al. The double layer sign is highly predictive of progression to exudation in age-related macular degeneration. *Ophthalmol Retina*. 2024;8(3):234-45.
29. Csincsik L, Muldrew A, Sproule A, et al. The predictive value of double layer sign and shallow irregular RPE elevation: results from a systemic study. *Invest Ophthalmol Vis Sci*. 2023;64(8):2179.
30. Metrangolo C, Donati S, Mazzola M, et al. OCT biomarkers in neovascular age-related macular degeneration: a narrative review. *J Ophthalmol*. 2021;9994098.
31. Tsai ASH, Cheung N, Gan ATL, et al. Retinal angiomatous proliferation. *Surv Ophthalmol*. 2017;62(4):462-92.

RETeval[®]

ERG SIMPLIFIED

THINK YOU KNOW ERG?



- ✓ Predictive results
- ✓ Simplified interpretation
- ✓ Shorter testing time
- ✓ Technician-friendly
- ✓ Affordable & reimbursable



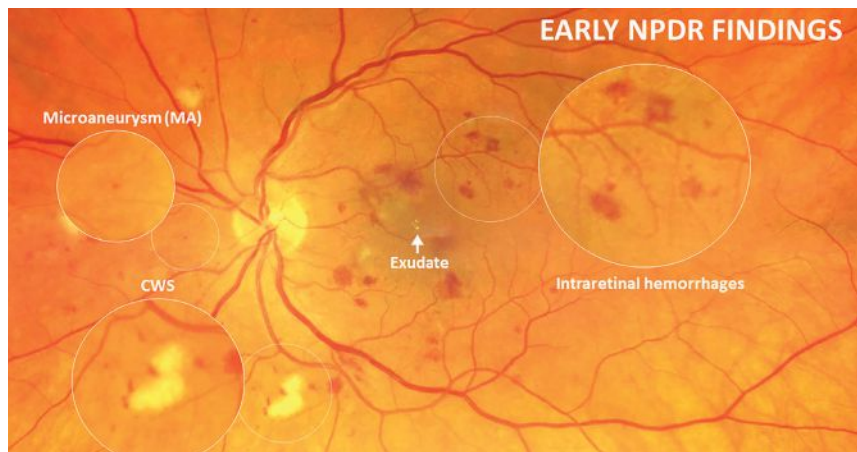
DIABETIC EYE DISEASE: A Comprehensive Look at the Optometrist's Role

Learn what to pay attention to and when to take charge.



BY JESSICA TARKA, OD, AND
CAROLYN MAJCHER, OD
TAHLEQUAH, OK

In recent decades, rates of diabetes have climbed to epidemic levels. The most current report from the CDC released in 2021 states that 38.4 million individuals in the US have diabetes, accounting for nearly 12% of the total population.¹ Diabetic retinopathy (DR) is a common complication of diabetes mellitus (DM), affecting approximately 30% of adults with diabetes, and is the leading cause of blindness in working-aged Americans.² As primary eyecare providers, the role of optometric physicians is more important than ever to prevent devastating vision loss amongst our growing diabetic population. This article will review the most recent literature—as well as provide anecdotal insights from our hands-on experience with thousands of cases—on causes, presentations and diagnostic techniques in diabetic eye disease.



With the updated ICDR guidelines, mild retinopathy is classified as microaneurysms only and the presence of intraretinal hemorrhages is indicative of at least moderate NPDR stage.

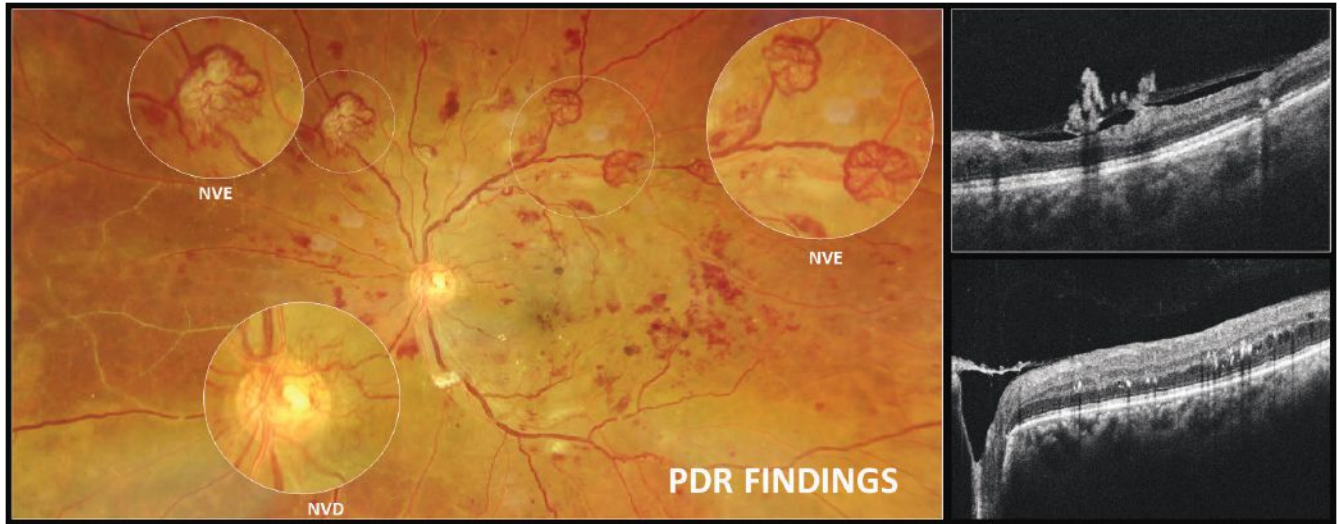Pathogenesis and Clinical Findings

Inner retinal microvascular changes due to prolonged hyperglycemia can be visualized in the retina as microaneurysms, hemorrhaging, leakage and exudation and nonperfusion. These findings fall into the category of nonproliferative changes. More advanced features of nonproliferative disease include venous beading,

intraretinal microvascular abnormalities (IRMA) that represent dilated telangiectatic capillaries still confined intraretinally and vascular sheathing. As DR continues to advance, mounting retinal ischemia prompts vascular endothelial growth factor (VEGF) release, fueling preretinal neovascular growth that characterizes the proliferative retinopathy stage (PDR).

About the authors

Dr. Tarka is a resident at the Oklahoma College of Optometry at Northeastern State University. **Dr. Majcher** is a professor and the director of residency programs at the Oklahoma College of Optometry at Northeastern State University. She is a fellow of the American Association of Optometry and the Optometric Retina Society. She is a paid speaker and consultant for Regeneron Pharmaceuticals and Carl Zeiss Meditec. She is also a paid consultant for Topcon as well as Ocuterra and has received non-financial support from Roche.



Neovascularization in PDR is preretinal and located on top of the retina. It can be classified as neovascularization of the disc (NVD, on or within one disc diameter from the disc margin) or neovascularization of the retina elsewhere (NVE).

Neovascularization typically begins within the retina and on the optic nerve head but can eventually infiltrate the iris and angle. Tractional retinal detachment (TRD) and neovascular glaucoma are the most advanced complications and can cause severe, irreversible vision loss.

Diabetic macular edema (DME) is characterized by vascular leakage that results in intraretinal fluid cysts and retinal thickening that may be accompanied by spillover of subfoveal fluid in severe cases. This occurs as increased vasopermeability leads to breakdown of the inner blood-retinal barrier and exudation.³ While it is more likely as DR severity progresses, DME can occur at any stage of retinopathy and is the most common cause of reduced vision in diabetes.⁴

An Update on DR Staging

Nonproliferative diabetic retinopathy (NPDR) and PDR are divided into stages based upon evidence of progressing severity to provide risk assessment and guidance on clinical management. These grading scales have changed over time to reflect advances in knowledge and understanding of diabetic eye disease.

The Early Treatment of Diabetic Retinopathy Study (ETDRS) provided the most widely accepted classification system for many years.⁵ However, this dates back to 1991 and its applicability today suffers as a result. In

2019, the American Academy of Ophthalmology (AAOph) adjusted its Diabetic Retinopathy Preferred Practice Pattern to follow guidelines of another commonly used classification system, the International Clinical Diabetic Retinopathy (ICDR) Severity Scale.⁶ Although these grading scales have significant areas of overlap, there are some notable distinctions. The most significant difference between the two is the differentiation between mild vs. moderate NPDR.

Using the ETDRS classification, mild NPDR was characterized by microaneurysms and hemorrhaging less than that in that study's Standard Photo 2A—a 30° color fundus photo can be used for DR comparison. With the updated ICDR guidelines, mild retinopathy is classified by microaneurysms only, and the presence of intraretinal hemorrhages is indicative of at least moderate NPDR stage. Severe NPDR continues to be defined by one factor of the 4-2-1 rule: four quadrants of severe intraretinal hemorrhaging (approximately 20 hemorrhages per quadrant), at least two quadrants of definite venous beading and at least one quadrant of IRMA. Very severe NPDR is associated with a higher risk of proliferative conversion and is defined as the presence of two or more factors of the 4-2-1 rule. Amongst eyes with severe and very severe NPDR, the risk for conversion to PDR

within one year's time is 50% and 75%, respectively.^{7,8}

PDR is defined by the presence of new vessels with or without hemorrhaging into the vitreous or preretinal/subhyaloid space. Neovascularization in PDR is preretinal and located on top of the retina. It can be classified as neovascularization of the disc (NVD, on or within one disc diameter from the disc margin) or neovascularization of the retina elsewhere (NVE). These are weak and fragile vessels that often grow on the posterior hyaloid membrane, much like ivy grows on the side of a house.

PDR can be divided into active and inactive forms. Preretinal tissue in active PDR is still vascularized and blood can be seen within the small, fine vessels of the membrane, while the preretinal tissue of inactive PDR is mostly fibrotic, avascular and opaque in appearance.

With OCT angiography (OCT-A) there is regression of the lacy, looping capillaries on the fringe of the membrane as neovascularization becomes inactive; however, if the membrane is sizeable, the clinician may observe that larger, mature, feeder-looking vessels remain despite adequate treatment.

Active PDR can then further be subclassified as high risk or low risk. High-risk PDR is defined by the presence of NVD larger than one-fourth disc area, a smaller area of NVD accompanied

TABLE 1. DIABETIC RETINOPATHY STAGING PER AMERICAN ACADEMY OF OPHTHALMOLOGY⁶

Disease Severity Level	Findings Observable upon Dilated Ophthalmoscopy
No apparent retinopathy	No abnormalities
Mild NPDR	Microaneurysms only
Severe NPDR (international definition) · Any patient with two or more of the characteristics of severe NPDR is considered to have very severe NPDR.	Any of the following and no signs of PDR: · More than 20 intraretinal hemorrhages in each of four quadrants · Definite venous beading in two or more quadrants · Prominent IRMA in one or more quadrants
PDR	One or both of the following: · Neovascularization · Vitreous/preretinal hemorrhage

by vitreous or preretinal hemorrhage or NVE at least one-half disc area in size with vitreous or preretinal hemorrhage.^{6,8} Although any degree of PDR should be referred to a specialist and is usually treated, distinguishing high from low risk is important for two main reasons: (1) the 2019 American Optometric Association (AOA) Clinical Practice Guidelines recommend more urgent referral of high-risk PDR (within 24 to 48 hours vs. two to four weeks for low-risk) and (2) treatment, usually panretinal laser photocoagulation (PRP), is recommended for high-risk PDR since the Diabetic Retinopathy Study (DRS) found that there was an approximate 50% risk of severe vision loss within five years if high-risk PDR was left untreated.^{6,9,10}

Additionally, anti-VEGF therapy to slow progression of PDR has recently

gained traction and can decrease risk of complications from PDR such as TRDs and development of new macular edema. Further, the use of intravitreal anti-VEGF before or in addition to PRP has been demonstrated to be more effective than just PRP alone in high-risk PDR patients.^{11,12}

Although the AAOph has adopted the ICDR system, it has not updated its practice guidelines similarly; the 2019 AOA Clinical Practice Guidelines continue to refer to the ETDRS scale DR grading criteria.⁹ These inconsistencies may lead to confusion if the grading scale used is not explicitly defined.

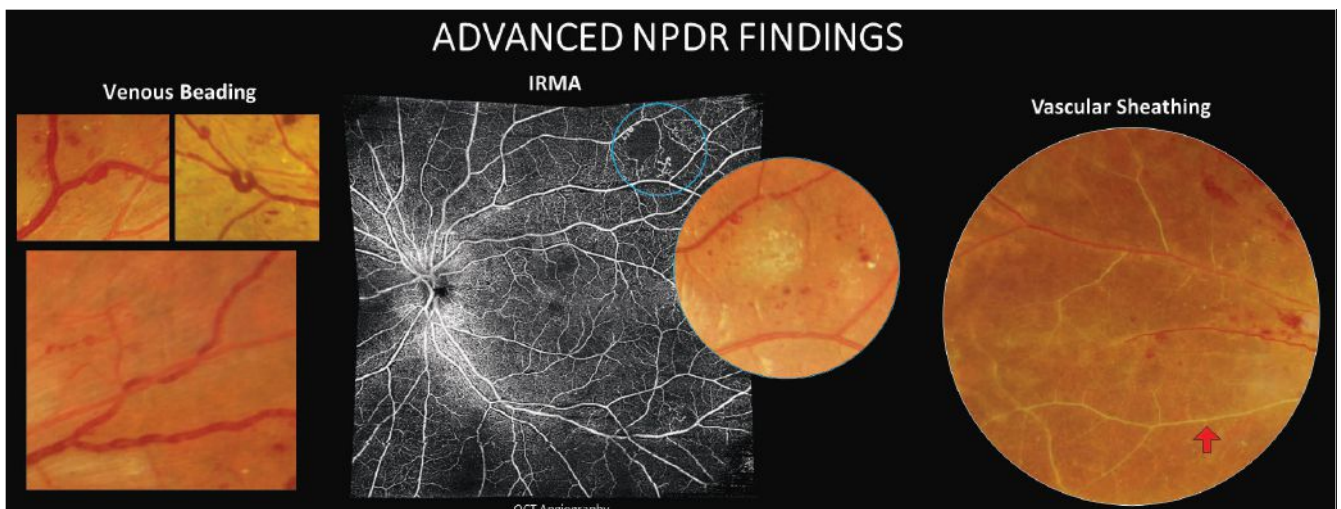
Historically, the ETDRS also coined the term “clinically significant macular edema” (CSME). This was defined as either retinal thickening within the central 500µm of the macula, hard exu-

dates within 500µm of the center of the macula with adjacent thickening or zones of retinal thickening one disc diameter or larger within one disc diameter of the fovea.^{5,9} With the advent of OCT, DME is now more commonly described as either center involved (CI-DME) or non-center involved (NCI-DME). CI-DME is defined as thickening within the central 1mm diameter or “center subfield zone.”⁶ Staging retinopathy and DME offers an organized approach for management based upon risk of progression and ultimately, risk of vision loss.

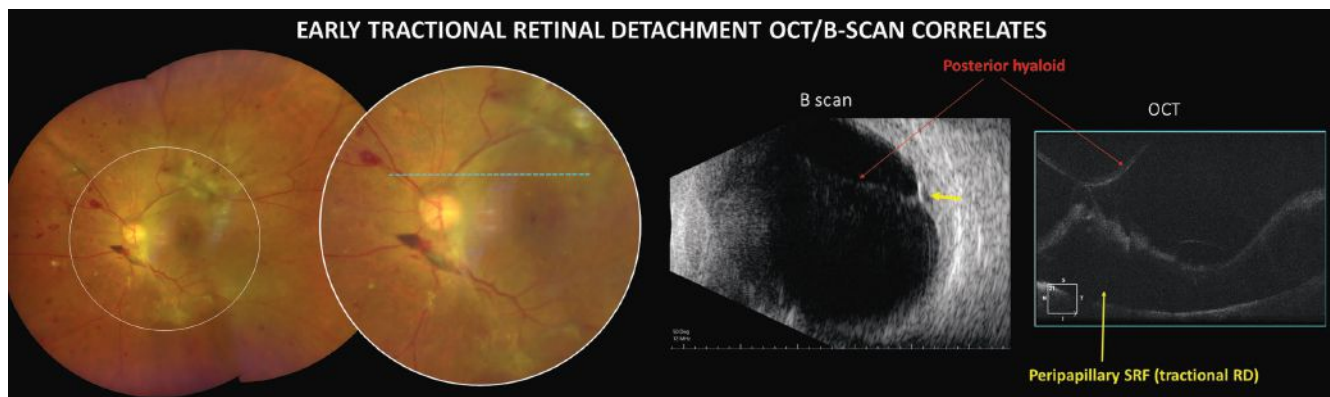
The OD’s Role

Proper management of patients with diabetes requires a multidisciplinary approach. With DR being the most common microvascular complication of the disease, optometric physicians play an integral part on this team.¹³

The American Diabetes Association (ADA) and AOA recommend a baseline comprehensive eye exam and follow-up examinations for patients with type 1 diabetes. The first follow-up should not exceed three to five years after diagnosis, and patients should be followed at least annually thereafter.⁹ Those with type 2 diabetes should be evaluated at time of diagnosis since diabetes may have gone undetected for years prior, making it challenging to determine the exact duration of the disease.⁹ Follow-up interval depends upon the level of retinopathy present and analysis of other risk factors



More severe NPDR findings that increase the risk for future conversion to PDR.



TRD in PDR is an advanced complication that can cause severe, irreversible vision loss.

for progression, such as degree of glyce- mic control and duration of the disease. Those without retinopathy or those with only mild retinopathy can be monitored annually assuming no DME is present.

There can be significant variability of presentation within the category of moderate NPDR, especially with the shift to the ICDR classification system. Milder cases of moderate NPDR with minimal retinopathy lesions can be monitored every nine to 12 months. However, as signs approach the more severe end of the moderate NPDR spectrum, a six-month follow-up interval may be more appropriate. Referral to a retina specialist should be considered for patients with severe NPDR even in the absence of DME, and patients should be monitored closely, every three to four months.^{6,9} When considering whether or not to refer a patient with severe NPDR, factors favoring referral include noncompliance, documented rapid progression, absence of complete posterior vitreous detachment (PVD), monocular status and presence of concurrent DME or multiple risk factors for progression such as poor glycemic control. Provider comfort level and in-office imaging availability also should be contemplated.

Electrophysiology, specifically electro- retinogram (ERG) testing, is an addition- al tool that can aid in risk analysis for DR progression. ERG can provide a quantita- tive functional assessment of the retina that can uncover deficits before they become structurally evident. Patients with abnormal functional testing on ERG generally require earlier intervention than those with low-risk ERG results. In some

cases, functional deficits can precede visible structural changes and may lead to closer monitoring and earlier referral.¹⁴

Observation is the current standard of care for cases of severe NPDR; however, some studies support beneficial outcomes of treatment at this stage, especially for those meeting the criteria of very severe NPDR.^{5,15,16} A referral to a retina special- ist is also warranted for cases of active and previously untreated proliferative disease. As previously mentioned, the 2019 AOA Clinical Practice Guidelines recommend more urgent referral of high-risk PDR (24 to 48 hours for high-risk vs. two to four weeks for low-risk).⁹ Although treat- ment of low-risk PDR may or may not be immediately initiated (deferred until it reaches high risk), care with ophthal- mology should be established. Due to the high risk for severe vision loss, the AAOPh recommends treatment, usually PRP, in cases of active high-risk PDR.⁶

The presence of DME can have a significant impact on referral timeline. As a general rule, the optometric physician should consider referring DME at any stage, especially if it is center involved, causing reduced best-corrected visual acuity (BCVA) or is progressing. The 2019 AOA Clinical Practice Guidelines recommends consultation within two to four weeks when CI-DME is pres- ent.⁹ Of note, the results of the Diabetic Retinopathy Clinical Research (DRCR) Network Protocol V suggested that close observation until acuity declines or DME worsens may be a reasonable management option for eyes with CI-DME and BCVA of 20/25 or better.¹⁷ This study found that vision at two

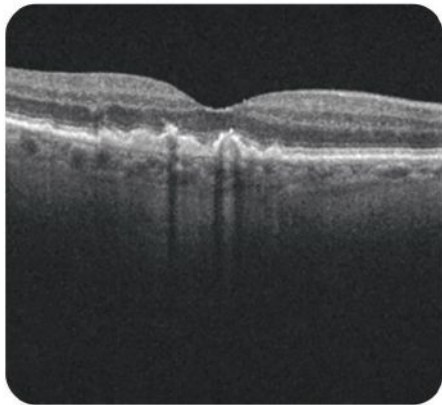
years was no different whether eyes with CI-DME and good acuity were imme- diately treated with aflibercept, macular laser or if treatment was withheld until acuity worsened.¹⁷ Patients with DME should be followed every two to four months.^{6,9,18}

Refer patients with anterior segment neovascularization urgently, as prompt treatment prior to formation of complete synechial angle closure may spare an eye from surgical glaucoma procedures. Lastly, it may be beneficial to obtain con- sultation when the stage of retinopathy is uncertain due to media opacity or poor patient cooperation.

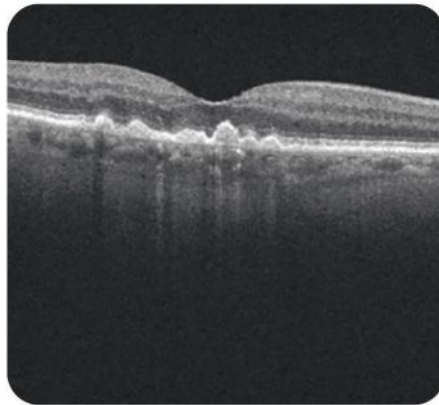
When patients with diabetes are ex- amined, results should be communicated to the physician managing the diabetes (e.g., primary care physician, endocrinolo- gist). This written communication should include the stage of retinopathy as well as the presence/absence of DME, encour- age individualized glycemic control and other comorbid systemic risk factors such as hypertension/serum lipids and state the recommended follow-up.^{6,9,19} Recent evidence suggests that episodes of hy- poglycemia can contribute to worsening diabetic eye disease via upregulation of VEGF. Take care to avoid even transient periods of low blood sugar.²⁰

Eyecare providers have an obligation to the public to provide access to care for all patients—even those in rural areas—and education efforts should be made to ensure that the public is aware that dia- betes can affect the eyes, emphasizing the importance of at least yearly eye exami- nations and that vision loss is preventable with early detection.²¹

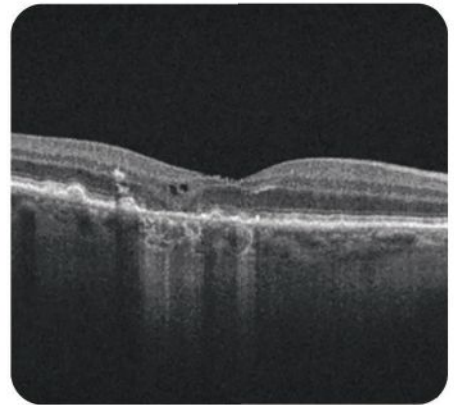
GEOGRAPHIC ATROPHY (GA) CAN PROGRESS FASTER THAN YOU THINK¹



Baseline



Month 3



Month 6

1. Boyer D, Schmidt-Erfurth U, van Lookeren Campagne M, et al. The pathophysiology of geographic atrophy secondary to age-related macular degeneration and the complement pathway as a therapeutic target. *Retina*. 2017;37(5);819-835.

INDICATION

IZERVAY™ (avacincaptad pegol intravitreal solution) is indicated for the treatment of geographic atrophy (GA) secondary to age-related macular degeneration (AMD)

IMPORTANT SAFETY INFORMATION

CONTRAINDICATIONS

IZERVAY is contraindicated in patients with ocular or periocular infections and in patients with active intraocular inflammation.

WARNINGS AND PRECAUTIONS

Endophthalmitis and Retinal Detachments

Intravitreal injections, including those with IZERVAY, may be associated with endophthalmitis and retinal detachments. Proper aseptic injection technique must always be used when administering IZERVAY in order to minimize the risk of endophthalmitis. Patients should be instructed to report any symptoms suggestive of endophthalmitis or retinal detachment without delay and should be managed appropriately.

EVERY MONTH MATTERS WHEN TREATING GA


izervay[™]
(avacincaptad pegol
intravitreal solution) 2 mg



Learn more at
[IZERVAYecp.com](https://www.izervayecp.com)

Neovascular AMD

In clinical trials, use of IZERVAY was associated with increased rates of neovascular (wet) AMD or choroidal neovascularization (7% when administered monthly and 4% in the sham group) by Month 12. Patients receiving IZERVAY should be monitored for signs of neovascular AMD.

Increase in Intraocular Pressure

Transient increases in intraocular pressure (IOP) may occur after any intravitreal injection, including with IZERVAY. Perfusion of the optic nerve head should be monitored following the injection and managed appropriately.

ADVERSE REACTIONS

Most common adverse reactions (incidence $\geq 5\%$) reported in patients receiving IZERVAY were conjunctival hemorrhage, increased IOP, blurred vision, and neovascular age-related macular degeneration.

Please see full Prescribing Information for more information.

Copyright © 2024 Astellas Pharma Inc. or its affiliates.
All trademarks are the property of their respective owners.
US-AP-2300334 V1 03/24



IZERVAY™ (avacincaptad pegol intravitreal solution)

Rx only

Brief Summary: This information is not comprehensive. Visit IZERVAYecp.com to obtain the FDA-approved product labeling or call 609-474-6755.

1 INDICATIONS AND USAGE

IZERVAY is indicated for the treatment of geographic atrophy (GA) secondary to age-related macular degeneration (AMD).

2 DOSAGE AND ADMINISTRATION

2.1 General Dosing Information

IZERVAY must be administered by a qualified physician.

2.2 Recommended Dosage

The recommended dose for IZERVAY is 2 mg (0.1 mL of 20 mg/mL solution) administered by intravitreal injection to each affected eye once monthly (approximately every 28 ± 7 days) for up to 12 months.

2.4 Injection Procedure

Only 0.1 mL (2 mg) should be administered to deliver a single dose. Any excess volume should be disposed.

Prior to the intravitreal injection, patients should be monitored for elevated intraocular pressure (IOP) using tonometry. If necessary, ocular hypotensive medication can be given to lower the IOP.

The intravitreal injection procedure must be carried out under controlled aseptic conditions, which includes the use of surgical hand disinfection, sterile gloves, a sterile drape, and a sterile eyelid speculum (or equivalent). Adequate anesthesia

and a broad-spectrum topical microbicide should be given prior to the injection.

Inject slowly until the rubber stopper reaches the end of the syringe to deliver the volume of 0.1 mL. Confirm delivery of the full dose by checking that the rubber stopper has reached the end of the syringe barrel.

Immediately following the intravitreal injection, patients should be monitored for elevation in intraocular pressure (IOP). Appropriate monitoring may consist of a check for perfusion of the optic nerve head or tonometry.

Following intravitreal injection, patients should be instructed to report any symptoms suggestive of endophthalmitis (e.g., eye pain, redness of the eye, photophobia, blurring of vision) without delay.

Each vial and syringe should only be used for the treatment of a single eye. If the contralateral eye requires treatment, a new vial and syringe should be used and the sterile field, syringe, gloves, drapes, eyelid speculum, filter needle, and injection needle should be changed before IZERVAY is administered to the other eye. Repeat the same procedure steps as above.

Any unused medicinal product or waste material should be disposed of in accordance with local regulations.

3 DOSAGE FORMS AND STRENGTHS

Intravitreal solution: 20 mg/mL clear to slightly opalescent, colorless to slightly yellow solution in a single-dose vial.

4 CONTRAINDICATIONS

4.1 Ocular or Periocular Infections

IZERVAY is contraindicated in patients with ocular or periocular infections.

4.2 Active Intraocular Inflammation

IZERVAY is contraindicated in patients with active intraocular inflammation.

5 WARNINGS AND PRECAUTIONS

5.1 Endophthalmitis and Retinal Detachments

Intravitreal injections may be associated with endophthalmitis and retinal detachments. Proper aseptic injection techniques must always be used when administering IZERVAY in order to minimize the risk of endophthalmitis. Patients should be instructed to report any symptoms suggestive of endophthalmitis or retinal detachment without delay, to permit prompt and appropriate management.

5.2 Neovascular AMD

In clinical trials, use of IZERVAY was associated with increased rates of neovascular (wet) AMD or choroidal neovascularization (7% when administered monthly and 4% in the sham group) by Month 12. Patients receiving IZERVAY should be monitored for signs of neovascular AMD.

5.3 Increase in Intraocular Pressure

Transient increases in intraocular pressure (IOP) have been observed after an intravitreal injection, including with IZERVAY. Perfusion of the optic nerve head should be monitored following the injection and managed as needed.

6 ADVERSE REACTIONS

The following potentially serious adverse reactions are described elsewhere in the labeling:

- Ocular and periocular infections
- Neovascular AMD
- Active intraocular inflammation
- Increase in intraocular pressure
- Endophthalmitis and retinal detachments

6.1 Clinical Trials Experience

Because clinical trials are conducted under widely varying conditions, adverse reaction rates observed in the clinical trials of a drug cannot be directly compared to rates in the clinical trials of another drug and may not reflect the rates observed in practice.

The safety of avacincaptad pegol was evaluated in 733 patients with AMD in two sham-

controlled studies (GATHER1 and GATHER2). Of these patients, 292 were treated with intravitreal IZERVAY 2 mg (0.1 mL of 20 mg/mL solution). Three hundred thirty-two (332) patients were assigned to sham.

Adverse reactions reported in ≥2% of patients who received treatment with IZERVAY pooled across GATHER1 and GATHER2, are listed below in Table 1.

Table 1: Common Ocular Adverse Reactions (≥2%) and greater than Sham in Study Eye

Adverse Drug Reactions	IZERVAY N = 292	Sham N = 332
Conjunctival hemorrhage	13%	9%
Increased IOP	9%	1%
Choroidal neovascularization	7%	4%
Blurred vision*	8%	5%
Eye pain	4%	3%
Vitreous floaters	2%	<1%
Blepharitis	2%	<1%

* Blurred vision includes visual impairment, vision blurred, visual acuity reduced, visual acuity reduced transiently.

8 USE IN SPECIFIC POPULATIONS

8.1 Pregnancy

Risk Summary

There are no adequate and well-controlled studies of IZERVAY administration in pregnant women. The use of IZERVAY may be considered following an assessment of the risks and benefits.

Administration of avacincaptad pegol to pregnant rats and rabbits throughout the period of organogenesis resulted in no evidence of adverse effects to the fetus or pregnant female at intravenous (IV) doses 5.1 times and 3.2 times the human exposure (based on AUC) at the maximum recommended human dose (MRHD) of 2 mg once monthly, respectively.

In the U.S. general population, the estimated background risks of major birth defects and miscarriage in clinically recognized pregnancies is 2-4% and 15%-20%, respectively.

Animal Data

An embryo fetal developmental toxicity study was conducted with pregnant rats. Pregnant rats received daily intravenous (IV) injections of avacincaptad pegol from day 6 to day 17 of gestation at 0.1, 0.4, 1.2 mg/kg/day. No maternal or embryofetal adverse effects were observed at any dose evaluated. An increase in the incidence of a non-adverse skeletal variation, described as short thoracolumbar (ossification site without distal cartilage) supernumerary ribs, was observed at all doses evaluated. The clinical relevance of this finding is unknown. Plasma exposures at the high dose were 5.1 times the MRHD, based on Area Under the Curve (AUC).

An embryo fetal developmental toxicity study was conducted with pregnant rabbits. Pregnant rabbits received daily IV injections of avacincaptad pegol from day 7 to day 19 of gestation at 0.12, 0.4, 1.2 mg/kg/day. No maternal or embryofetal adverse effects were observed at any dose evaluated. Plasma exposure in pregnant rabbits at the highest dose of 1.2 mg/kg/day was 3.2 times the human exposure at the MRHD, based on AUC.

8.2 Lactation

There is no information regarding the presence of avacincaptad pegol in human milk, the effects of the drug on the breastfed infant or on milk production.

The developmental and health benefits of breastfeeding should be considered along with the mother's clinical need for IZERVAY and any potential adverse effects on the breastfed infant from IZERVAY.

8.4 Pediatric Use

Safety and effectiveness of IZERVAY in pediatric patients have not been established.

8.5 Geriatric Use

Of the total number of patients who received IZERVAY in the two clinical trials, 90% (263/292) were ≥65 years and 61% (178/292) were ≥75 years of age. No significant differences in efficacy or safety of avacincaptad pegol were seen with increasing age in these studies. No dose adjustment is required in patients 65 years and above.

17 PATIENT COUNSELING INFORMATION

Advise patients that following IZERVAY administration, patients are at risk of developing neovascular AMD, endophthalmitis, elevated intraocular pressure and retinal detachments. If the eye becomes red, sensitive to light, painful, or if a patient develops a change in vision, instruct the patient to seek immediate care from an ophthalmologist.

Patients may experience temporary visual disturbances and blurring after an intravitreal injection with IZERVAY and the associated eye examinations. Advise patients not to drive or use machinery until visual function has recovered sufficiently.

Manufactured by:

IVERIC bio, Inc., An Astellas Company. Parsippany, NJ 07054

©2023 IVERIC bio, Inc., An Astellas Company. IZERVAY is a trademark of IVERIC bio, Inc., An Astellas Company.

Examination Essentials

Exams for patients with diabetes should be multifaceted and emphasize certain aspects. First, a careful history should be acquired. Document duration of DM, some indication of glycemic control (HbA1c and/or fasting blood glucose level, glucose time in range) and medications. Visual acuity, entrance test, slit lamp exam and intraocular pressure (IOP) should be obtained, as in a standard eye exam. A magnified slit lamp examination of the entire iris (lids retracted as needed) should be done prior to dilation. If any neovascularization of the iris is present or IOP is elevated, perform gonioscopy to inspect for neovascularization of the angle.

After dilation, perform a thorough funduscopic exam of the posterior pole and the periphery. Vitreous and preretinal hemorrhages may be subtle in PDR, and it is important to always examine the inferior peripheral fundus carefully to look for subtle vitreous blood that has settled with gravity.

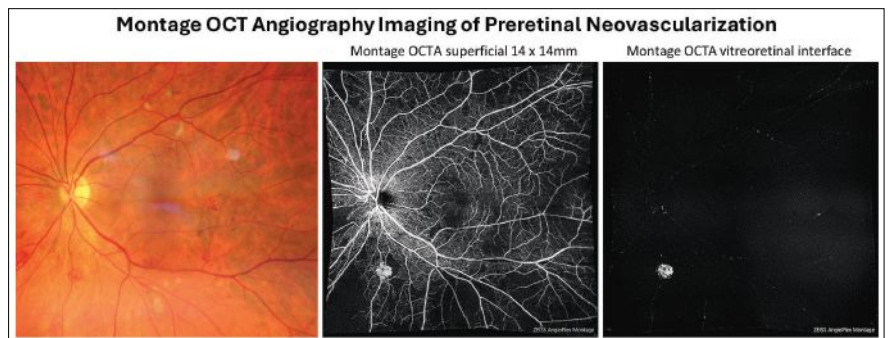
Although not required, certain ancillary tests provide great benefit in diagnosis and management. Multimodal imaging technologies often help highlight subtle vascular abnormalities and results in more accurate retinopathy staging and increased exam efficiency. There is significant debate regarding the use of fundus photography as a replacement for traditional dilated eye exams. Multiple studies have shown that inspection of fundus photos may actually be superior to ophthalmoscopy for identification of some lesions such as microaneurysms, small intraretinal hemorrhages, IRMA and subtle neovascularization.^{22,23} However, at this point in time, imaging is less than a perfect science. The presence of artifacts, lack of stereopsis and poor identification of peripheral lesions are just some reasons why imaging, including ultra-widefield techniques, is often not an adequate replacement for clinical examination.²⁴ A traditional dilated fundus exam is still the standard of care for diabetes from a legal perspective, and examination of the retina via imaging alone is inadequate. Rather than substituting photography for comprehensive clinical examination of di-

abetic patients, use fundus imaging as an adjunctive tool in addition to traditional ophthalmoscopy.

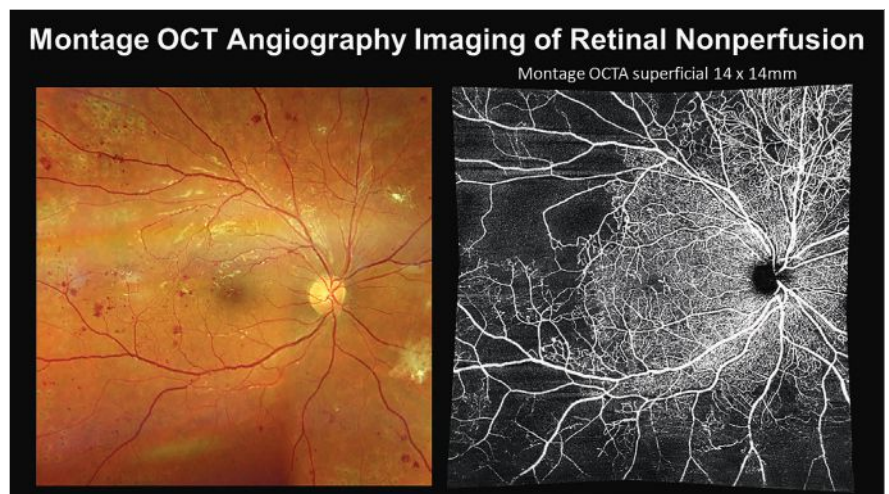
One of the most heavily used ancillary instruments in these eye exams is OCT. It has proven incredibly valuable in the diagnosis and management of DME, as it can quantify central macular thickness, identify anatomical location of fluid (including subclinical DME), closely monitor changes in macular edema and rule in or out other causes of reduced vision in patients with diabetes. Additionally, OCT is routinely used to monitor DME treatment efficacy. OCT, and especially OCT-A or fluorescein angiography, can also be used to confirm or deny the presence of neovascularization that can be difficult to differentiate from IRMA or other anomalous appearing vessels. Even structural OCT alone is an excellent tool that can identify preretinal tissue or vitreoretinal traction and monitor TRD.

In recent years, development of OCT-A has provided a noninvasive method for optometric physicians to assess capillary nonperfusion, macular ischemia and neovascularization in-office. Previously, these findings could only be directly visualized via fluorescein angiography, requiring an ophthalmology referral in most states. Smaller scan sizes that maximize resolution, such as 3mm by 3mm, should be used to evaluate macular ischemia while wider field montage imaging, such as 14mm by 14mm, should be employed for estimating the degree of retinal nonperfusion and screening for proliferation. Neovascularization often occurs adjacent to areas of capillary nonperfusion. Incorporating imaging technologies allows for the earliest detection of even subclinical PDR.

B-scan ultrasonography may not be a heavily used tool in many optometry



Preretinal neovascularization can be isolated out using the vitreous or vitreoretinal interface preset en-face display of OCT-A. This allows for the earliest detection of even subclinical PDR.



Incorporating montage OCT-A enables visualization of retinal nonperfusion that may be nearly invisible with ophthalmoscopy or color photography alone.

TABLE 1. AMERICAN ACADEMY OF OPHTHALMOLOGY INITIAL MANAGEMENT RECOMMENDATIONS FOR DIABETES/DR PATIENTS⁶

Severity of Retinopathy	Macular Edema	Follow-up (Months)	PRP	Focal and/or Grid Laser	Intravitreal Anti-VEGF Therapy
Normal or minimal NPDR	No	12	No	No	No
	NCI-DME	3-6	No	Sometimes	No
	CI-DME	1	No	Rarely	Usually
Mild NPDR	No	12	No	No	No
	NCI-DME	3-6	No	Sometimes	Rarely
	CI-DME	1	No	Rarely	Usually
Moderate NPDR	No	6-12	No	No	No
	NCI-DME	3-6	No	Sometimes	Rarely
	CI-DME	1	No	Rarely	Usually
Severe NPDR	No	3-4	Sometimes	No	Sometimes
	NCI-DME	2-4	Sometimes	Sometimes	Sometimes
	CI-DME	1	Sometimes	Rarely	Usually
Non-high risk NPDR	No	3-4	Sometimes	No	Sometimes
	NCI-DME	2-4	Sometimes	Sometimes	Sometimes
	CI-DME	1	Sometimes	Sometimes	Usually
High-risk NPDR	No	2-4	Recommended	No	Sometimes
	NCI-DME	2-4	Recommended	Sometimes	Sometimes
	CI-DME	1	Recommended	Sometimes	Usually

practices; however, its utility in cases of dense vitreous hemorrhage is unmatched. As previously discussed, DR with any vitreous or preretinal hemorrhage must be referred to a retina specialist for treatment. However, the presence of a TRD observed with B-scan increases the urgency of referral.

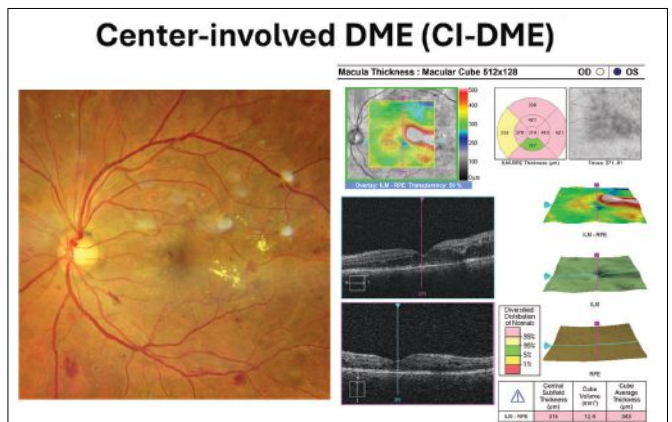
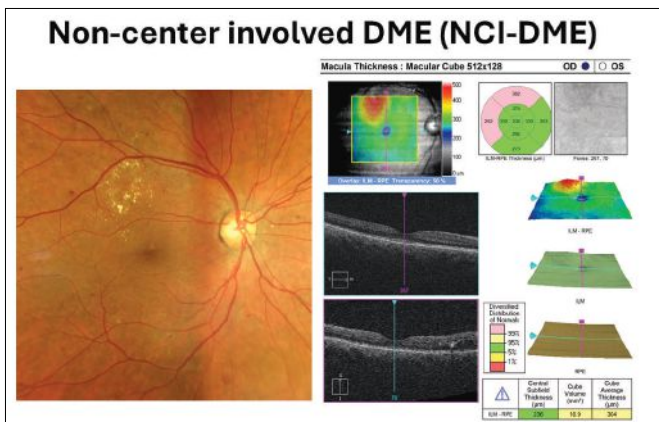
Patient Education

It is essential that patients are informed that at least annual eye exams are necessary even if they are asymp-

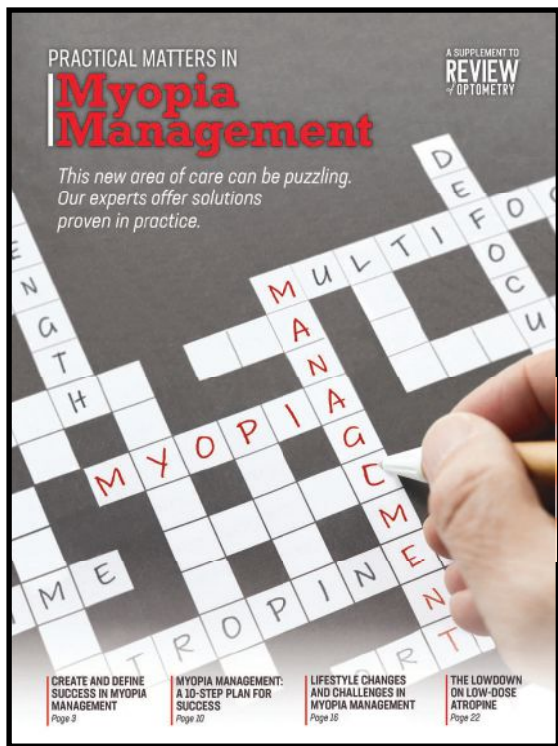
tomatic. It must be conveyed that early detection and timely treatment of DR are essential for best visual outcomes and prevention of sight-threatening complications. Especially in those with severe NPDR or PDR, optometrists should emphasize specific symptoms of vitreous hemorrhage and retinal detachment so that patients are aware they need to be seen as soon as possible upon onset.

To adequately educate their patients, optometrists should be aware of risk

factors for progression of retinopathy. Disease duration is a well-known risk factor for DR development and progression. This is especially true for those with type 1 diabetes. After 15 years of disease duration, 80% of patients with type 1 DM will have some degree of retinopathy.²⁵ Intuitively, elevated blood glucose levels and HbA1c values, as well as less glucose time in range assessed by continuous glucose monitoring devices, are also associated with higher rates of retinopathy.



Staging of retinopathy and DME offers an organized approach for management based upon risk of progression and ultimately, risk of vision loss. CI-DME is defined as thickening within the central subfield zone (1mm in diameter).



THIRD ANNUAL

PRACTICAL MATTERS IN MYOPIA MANAGEMENT

Proven strategies from experts to help you build confidence and improve your success rate.

As optometrists continue to embrace myopia interventions, they need concrete guidance on best practices for this new area of care. Questions of patient selection, treatment efficacy, parent “buy-in” and the practice’s equipment needs can be a deterrent to enthusiasm among ODs. This supplement will guide optometrists through many of the practical challenges that might otherwise prevent them from pursuing myopia management.

TOPICS:

- **A CHECKLIST FOR STARTING A MYOPIA MANAGEMENT PRACTICE**

Equipment to buy, skills to develop, staff training, pricing, logistics, patient education resources.

- **HOW TO CREATE EFFECTIVE PROTOCOLS FOR MYOPIA MANAGEMENT**

There are three main options on the market now— atropine, multifocal contacts and ortho-K. Which do you start with and when do you add another or switch to something else? Once spectacle lens options or red light therapy get approved, how will they fit in?

- **ELECTRONICS & EYE HEALTH: CONSEQUENCES FOR MYOPIA PROGRESSION**

The latest on screen time, near vision tasks, consequences for sleep, mood and eye health.

- **HOW WOULD YOU HANDLE THESE CHALLENGING MYOPIA MANAGEMENT CASES?**

Real-world scenarios in which we explore all of the topics outlined in the previous three articles.



POLYBAGGED WITH ISSUE



41,276* CIRCULATION



WEBSITE ARCHIVE

*Source: BPA circ. statements for the 6-month period ending January 2024

SPACE CLOSE: 7/12

MATERIALS DUE: 7/19

For advertising opportunities, contact your *Review* representative today:

Michele Barrett

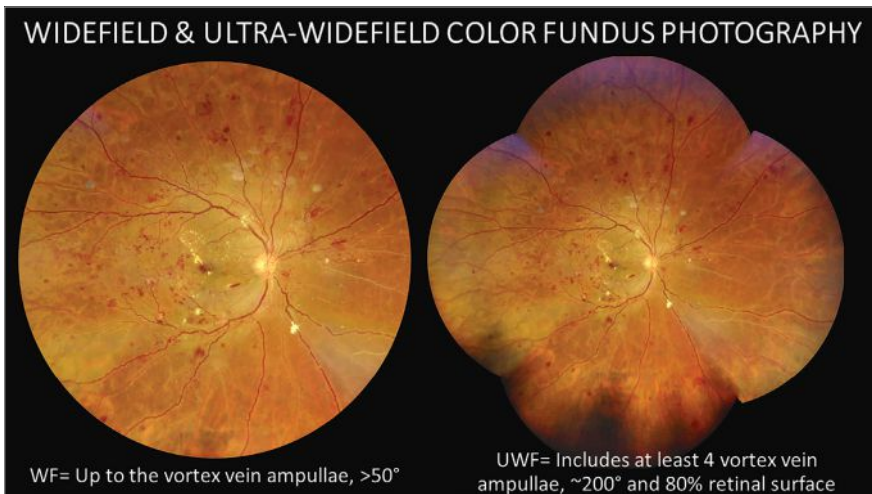
(215) 519-1414
mbarrett@jobson.com

Jon Dardine

(610) 492-1030
jdardine@jobson.com

Michael Hoster

(610) 492-1028
mhoster@jobson.com



A traditional dilated fundus exam is still the standard of care for diabetes retinal assessment from a legal perspective, but widefield imaging is a highly valuable adjunctive tool.

An HbA1c $\leq 7\%$ is recommended for most patients, depending on expected lifespan, comorbidities and cognitive status.²⁶ Control of blood pressure, lipids and management of comorbidities, such as sleep apnea, all reduce risk of progression.²⁷ Additionally, awareness of high-risk demographics is valuable for adequate patient education. Notably, rates of diabetes are significantly higher among Native American, Hispanic and African American populations, and these patients have higher risk of vision loss.⁶

Outline the risk of rapid progression carefully for women with diabetes who become pregnant. Changes in metabolic control during pregnancy are thought to contribute to increased risk of progression to severe retinopathy.²⁸ The AOA recommends a comprehensive eye exam prior to pregnancy, during the first trimester and more often thereafter as indicated by severity of retinopathy. Interestingly, there does not appear to be a significantly increased risk of retinopathy for those who develop gestational diabetes.²⁹

DR in the Ozempic Era

Glucagon-like peptide-1 (GLP-1) receptor analogs are a newer, highly effective category of medication for diabetes management, recently skyrocketing in popularity. GLP-1 drugs such as semaglutide (Ozempic and Wegovy, both Novo Nordisk), as well as tirzepatide (Mounjaro, Eli Lilly), have risen

to popularity because of their efficacy for glycemic control and weight loss promotion. With an increasing number of diabetic patients being prescribed these drugs, it is important that eyecare providers understand the implications.

Although improved glycemic control is encouraged for promotion of long-term positive outcomes, a transient worsening of retinopathy may be seen initially. The pathophysiology of this phenomenon is not well understood but is likely related to VEGF expression, reactive oxygen species production and breakdown of the blood-retinal barrier.³⁰

A post-hoc review of the Semaglutide Unabated Sustainability in Treatment of Type 2 Diabetes 6 (SUSTAIN 6) clinical trial compared DR in patients treated with semaglutide vs. placebo.³¹ In general, patients treated with semaglutide had a higher incidence of DR progression compared with the placebo group. It is presumed that this is due to the rapid decrease in HbA1c during the first 16 weeks of treatment.³² This study found the highest rates of DR complications in those with an A1c reduction of 1.5%.³³ Interestingly, there was no difference between the treated and placebo groups in those without retinopathy at baseline. Rather, progression was primarily observed in patients with NPDR and PDR upon initiation of treatment. Those with pre-existing retinopathy who were using insulin were at significantly higher

risk of developing worsening retinopathy. However, it is not clear if this is due to interaction with insulin or because these patients generally have had a longer duration of diabetes and higher baseline A1c.

As more patients are started on GLP-1 analogs, optometrists should be aware of the frequency of paradoxical worsening of retinopathy that occurs with rapidly improved glycemic control. Some sources suggest a baseline exam prior to initiation of treatment.³³ Additionally, more frequent follow-up of high-risk patients, such as those with existing severe retinopathy and insulin use, may be indicated during the first few months of treatment until glucose levels have stabilized.

Management Considerations

At each stage of DR, there are many findings and options to discuss with patients.

NPDR. Oral fenofibrate and vitamin supplementation may be considered in certain patients with mild to moderate NPDR in an effort to slow progression and improve visual function.

Fenofibrate is an older dyslipidemia medication that is a safe and inexpensive fibric acid derivative. It is considered off-label for treating DR in the US but is approved for this purpose in Australia and Singapore.³⁴ The typical dose when treating DR is 160mg per day; however, caution should be exercised in patients with kidney disease and a lower dose of approximately 54mg should be used.^{35,36}

Two very large randomized controlled trials (FIELD and ACCORD) have shown that fenofibrate, when used as an adjunctive treatment to standard of care DR therapies, can slow progression of pre-existing DR and reduce the need for treatment of DME and proliferative DR in patients with type 2 diabetes.³⁷⁻³⁹ The DRCR Network is currently recruiting for Protocol AF (Fenofibrate for Prevention of DR Worsening), which is enrolling patients with mild to moderately severe NPDR and no CI-DME at baseline. Results are expected in 2029.³⁶

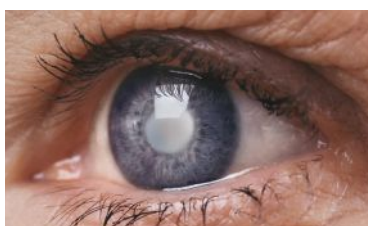In clinical practice, fenofibrate should be considered in patients with type 2 diabetes, mild to moderate NPDR and normal kidney function.^{34,35,40} It may be

Medscape **LIVE!** PRESENTS

2024 CE CONFERENCES

IN-PERSON 

CULAR SURFACE SYMPOSIUM

**SEPTEMBER 8, 2024**RENAISSANCE CHICAGO DOWNTOWN HOTEL
CHICAGO, ILLINOISwww.reviewedu.com/ossNEW
TECHNOLOGIES
& TREATMENTS IN
EYE CARE  Intrepid**NOVEMBER 15–17, 2024**GRAND HYATT NASHVILLE
NASHVILLE, TENNESSEEwww.reviewedu.com/ntt_ies_fall WEST COAST
OPTOMETRIC GLAUCOMA
SYMPOSIUM**DECEMBER 6–7, 2024**THE WESTIN CARLSBAD
CARLSBAD, CALIFORNIAwww.reviewedu.com/wcogs

THE OPTOMETRIC RETINA SOCIETY AND REVIEW EDUCATION GROUP PRESENT

RETINAUPDATE2024

**DECEMBER 7–8, 2024**THE WESTIN CARLSBAD
CARLSBAD, CALIFORNIAwww.reviewedu.com/orsretupdate

For a full list of Review Education Group CE events,
scan the QR code or visit: www.reviewedu.com/events

Postgraduate Institute
for Medicine**REVIEW**
Education GROUP

particularly beneficial among those with moderate to very high cardiovascular risk factors (hypertension, dyslipidemia, previous history of cardiovascular events) and at high risk for DR progression.³⁵

Another strategy aimed at DR prevention is nutritional supplementation and medical food therapies. We know that many patients with DR have concurrent vitamin and mineral deficiencies that fuel retinal microvascular damage and inflammation.⁴¹ Similar to use of fenofibrate, supplementation with vitamins, minerals and nutraceuticals is intended to complement current standard of care treatments, not replace them. The goals of supplementation in DR are to decrease inflammatory mediators, reduce oxidative stress, support retinal metabolism and promote microvascular health.⁴¹

Supplement components of interest include lutein and zeaxanthin, L-methylfolate, N-acetylcysteine, vitamin E, vitamin D, vitamin C, vitamins B1, B2, B6 and B12 (methylcobalamin) and alpha-lipoic acid.⁴¹ One study demonstrated that carotenoid containing nutritional supplementation in diabetic rats helped prevent capillary cell apoptosis and maintain normal retinal function.⁴² Furthermore, the Diabetes Visual Function Supplement Study (DiVFuSS) evaluated the effectiveness of a commercially available vitamin supplement (EyePromise DVS) on functional vision

aspects in 67 patients with diabetes and either no or mild-moderate stage nonproliferative DR.⁴³ Patients were randomized to either six months of DVS supplementation or placebo. Subjects on DVS had significantly better visual function performance on contrast sensitivity, color discrimination and 5-2 macular threshold perimetry testing.⁴³ Another commercially available medical food, Ocufofin (Global Healthcare Focus), has demonstrated an improvement in retinal microcirculation in eyes with mild DR among patients with methylenetetrahydrofolate reductase polymorphisms.⁴⁴

Early intravitreal anti-VEGF therapy may be considered in eyes with moderately severe to severe NPDR in an effort to improve retinopathy stage and/or prevent vision threatening complications, although practice patterns and sentiments in this regard vary greatly amongst retinal specialists.^{15,16} The DRCR Network Protocol W study set out to evaluate the potential benefits of periodic anti-VEGF therapy in preventing vision-threatening complications such as PDR and CI-DME.¹⁶ This study included eyes with moderate to severe NPDR lacking CI-DME and randomized them to either immediate periodic aflibercept injections or observation until CI-DME or high-risk PDR developed. The four-year results showed that while early anti-VEGF therapy did reduce the risk of developing

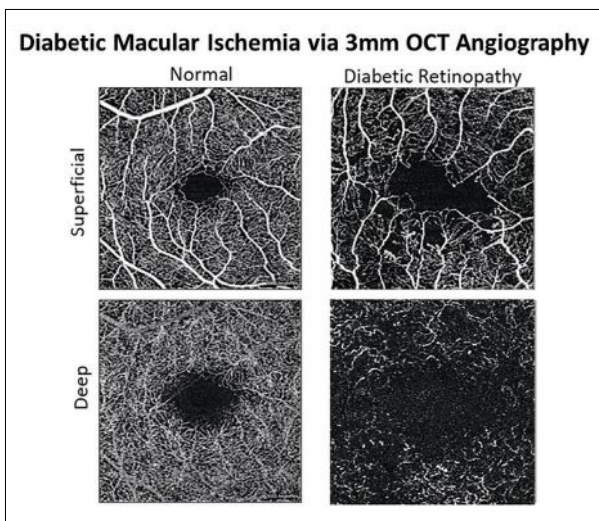
resulted in non-inferior acuity outcomes, less peripheral field loss and lower rates of vision-impairing DME development when compared with PRP, it is important to remember that anti-VEGF effects are temporary.⁴⁵ Long-term studies demonstrate that poor follow-up compliance amongst PDR patients treated with anti-VEGF alone can result in visually devastating outcomes, and follow-up compliance can be a challenge in patients with diabetes who need to see multiple specialty providers of various disciplines and may be hospitalized more frequently.⁴⁶ PRP may also be favored over anti-VEGF therapy in eyes with significant vitreoretinal traction since rapid neovascular regression may exacerbate this and promote TRD development/progression.⁴⁷

If concurrent high-risk PDR and CI-DME are present, treatment usually begins with anti-VEGF and then delayed PRP is performed, since PRP may initially worsen DME.⁶ Regression of neovascularization following PRP alone should begin within four to six weeks and supplemental PRP, anti-VEGF therapy or vitrectomy may be management options should PRP result in inadequate neovascular involution.⁶

Vitreous hemorrhage and TRD.

Vitreous hemorrhage may be initially observed when PRP has already been performed and B-scan ultrasonography confirms no TRD is present. Intravitreal anti-VEGF may speed resolution of vitreous hemorrhage and is often used when vitreoretinal traction is limited. Educate patients to limit physical activity, especially heavy lifting and Valsalva maneuvers, sleep upright if possible and avoid bending the head below the waist. Vitrectomy may be considered in cases of macular-threatening or -involving TRD, non-clearing or recurrent vitreous hemorrhage, dense preretinal hemorrhage or fibrotic tissue covers the macula, florid PDR with very large areas of neovascularization is present or DME with a vitreous tractional component exists.⁶

DME. First-line therapy for CI-DME involves anti-VEGF therapy, and newer generation agents such as faricimab and



Development of OCT-A has provided a noninvasive method for optometrists to assess capillary nonperfusion, macular ischemia and neovascularization in-office.

CI-DME and PDR significantly, change in visual acuity did not differ between the two groups.¹⁶ Therefore, the role of anti-VEGF therapy in severe NPDR management and its potential benefits continues to be debated.

PDR. Both PRP and anti-VEGF may be used to treat PDR; however, PRP is generally recommended in high-risk PDR.⁶ Although the DRCR Network Protocol S demonstrated that periodic ranibizumab therapy for PDR

Imaging Applications in DR

This is not an exhaustive list, but we do find these three tools ideally suited to each of the following responsibilities.

OCT

- Detect, classify and monitor DME.
- Determine PVD status.
- Detect preretinal tissue suggestive of non-vascularization.
- Detect and monitor vitreal retinal traction/TRD.

OCT-A

- Detection of subclinical DR.
- Highlight vascular abnormalities = more accurate staging.
- Detection and quantification of nonperfusion (both peripheral and macular).
- Early detection of PDR.
- Monitor PDR regression with treatment.

Widefield Imaging

- Detection/documentation of predominantly peripheral DR (increased risk for DR progression and proliferation).
- More accurate and efficient staging of DR.

high-dose 8mg aflibercept may provide extended duration of action allowing for less frequent injections and reduced treatment burden.^{6,9,47-49} Macular photocoagulation remains a viable treatment option for non-center-involved DME, especially when focal areas of noncentral leakage are present.⁶ Intravitreal corticosteroid injections and sustained-release implants may be employed when DME is diffuse or unresponsive to anti-VEGF therapies, especially in pseudophakic eyes.⁵⁰

Takeaways

With rates of diabetes skyrocketing, optometrists are and will continue to be a valuable asset to the multidisciplinary diabetes care team. As our understanding of DR deepens, our care must reflect these changes and advances. By staying up to date on guidelines, diagnostics aids, risk factors and management standards, optometrists can continue to offer quality care to patients with diabetes. ■

1. Bryan S, Afful J, Carroll M, et al. NHRS 158 national health and nutrition examination survey 2017–March 2020 pre-pandemic data files. National Health Statistics Reports. stacks.cdc.gov/view/cdc/106273. June 14, 2021. Accessed April 23, 2024.

2. Tan TE, Wong TY. Diabetic retinopathy: looking forward to 2030. *Front Endocrinol (Lausanne)*. 2023;13:1077669.

3. Romero-Aroca P, Baget-Bernaldiz M, Pareja-Rios A, et al. Diabetic macular edema pathophysiology: vasogenic vs. inflammatory. *J Diabetes Res*. 2016;2016:2156273.

4. Musat O, Cernat C, Labib M, et al. Diabetic macular edema. *Rom J Ophthalmol*. 2015;59(3):133-6.

5. Early Treatment Diabetic Retinopathy Study Research Group. Early photocoagulation for diabetic retinopathy. ETDRS report number 9. *Ophthalmology*. 1991;98(5 Suppl):766-85.

6. Flaxel CJ, Adelman RA, Bailey ST, et al. Diabetic retinopathy preferred practice pattern. *Ophthalmology* 2020;127(1):P66-145.

7. Early Treatment Diabetic Retinopathy Study Research Group. Fundus photographic risk factors for progression of diabetic retinopathy: ETDRS report number 12. *Ophthalmology*. 1991;98(5):823-33.

8. Perais J, Agarwal R, Evans JR, et al. Prognostic factors for the development and progression of proliferative diabetic retinopathy in people with diabetic retinopathy. *Cochrane Database Syst Rev*. 2023 Feb 22;(2):CD013775.

9. American Optometric Association. Evidence-based clinical practice guideline: eye care of the patient with diabetes mellitus. 2nd ed. www.aoa.org/practice/clinical-guidelines/clinical-practice-guidelines?ss=0-y. Accessed April 23, 2024.

10. The Diabetic Retinopathy Study Research Group. Photocoagulation treatment of proliferative diabetic retinopathy. Clinical application of Diabetic Retinopathy Study (DRS) findings, DRS Report Number 8. *Ophthalmology*. 1981;88(7):583-600.

11. Bahr TA, Bakri, SJ. Update on the management of diabetic retinopathy: anti-VEGF agents for the prevention of complications and progression of nonproliferative and proliferative retinopathy. *Life*. 2023;13(5):1098.

12. Osaadon P, Fagan XJ, Lifshitz T, et al. A review of anti-VEGF agents for proliferative diabetic retinopathy. *Eye*. 2014;28(5):510-20.

13. Shukla UV, Tripathy K. Diabetic retinopathy. *StatPearls*. Treasure Island (FL): StatPearls Publishing. www.ncbi.nlm.nih.gov/books/NBK560805/. Last updated August 25, 2023. Accessed April 23, 2024.

14. Brigell MG, Chiang B, Maa AY, Davis CQ. Enhancing risk assessment in patients with diabetic retinopathy by combining measures of retinal function and structure. *Transl Vis Sci Technol*. 2020;9(9):40.

15. Brown DM, Wyckoff CC, Boyer D, et al. Evaluation of intravitreal aflibercept for the treatment of severe nonproliferative diabetic retinopathy. *JAMA Ophthalmol*. 2021;139(9):946-55.

16. Maturi RK, Glassman AR, Josic K, et al. Four-year visual outcomes in the Protocol W randomized trial of intravitreal aflibercept for prevention of vision-threatening complications of diabetic retinopathy. *JAMA*. 2023;329(5):376-85.

17. Baker CW, Glassman AR, Beaulieu WT, et al; DRCR Retina Network. Effect of initial management with aflibercept vs. laser photocoagulation vs. observation on vision loss among patients with diabetic macular edema involving the center of the macula and good visual acuity: a randomized clinical trial. *JAMA*. 2019;321(19):1880-94.

18. Al Qassimi N, Kozak I, Al Karam M, et al. Management of diabetic macular edema: guidelines from the Emirates Society of Ophthalmology. *Ophthalmol Ther*. 2022;11(5):1937-50.

19. Storey PP, Murchison AP, Pizzi LT, et al. Impact of physician communication on diabetic eye examination adherence: Results from a retrospective cohort analysis. *Retina*. 2016;36(1):20-7.

20. Drinkwater JJ, Davis TME, Turner AW, et al. Incidence and determinants of intraocular lens implantation in type 2 diabetes: the Fremantle Diabetes Study Phase II. *Diabetes Care*. 2019;42(2):288-96.

21. Piyasena MMPN, Murthy GVS, Yip JLY, et al. Systematic review on barriers and enablers for access to diabetic retinopathy screening services in different income settings. *PLoS One*. 2019;14(4):e0198979.

22. Brown K, Sewell JM, Trempe C, et al. Comparison of image-assisted vs. traditional fundus examination. *Eye Brain*. 2013;5:1-8.

23. Cavallerano JD, Aiello LP, Cavallerano AA, et al. Nonmydriatic digital imaging alternative for annual retinal examination in persons with previously documented no or mild diabetic retinopathy. *Am J Ophthalmol*. 2005;140(4):667-73.

24. Kornberg DL, Klufas MA, Yannuzzi NA, et al. Clinical utility of ultra-widefield imaging with the optos optomap compared with indirect ophthalmoscopy in the setting of non-traumatic rhegmatogenous retinal detachment. *Semin Ophthalmol*. 2016;31(5):505-12.

25. Klein R, Klein BE, Moss SE, Davis MD, DeMets DL. The Wisconsin epidemiologic study of diabetic retinopathy II. Prevalence and risk of diabetic retinopathy when age at diagnosis

is less than 30 years. *Arch Ophthalmol*. 1984;102(4):520-6.

26. Solomon SD, Chew E, Duh EJ, et al. Diabetic retinopathy: a position statement by the American Diabetes Association. *Diabetes Care*. 2017;40(3):412-8.

27. Simonson M, Li Y, Zhu B, et al. Multidimensional sleep health and diabetic retinopathy: systematic review and meta-analysis. *Sleep Med Rev*. 2024;74:101891.

28. Chew EY, Mills JL, Metzger BE, et al. Metabolic control and progression of retinopathy: the diabetes in early pregnancy study. *Diabetes Care*. 1995;18(5):631-7.

29. Chandrasekaran P, Madanagopalan V, Narayanan R. Diabetic retinopathy in pregnancy - a review. *Indian J Ophthalmol*. 2021;69(11):3015-25.

30. Bain SC, Klufas MA, Ho A, Matthews DR. Worsening of diabetic retinopathy with rapid improvement in systemic glucose control: a review. *Diabetes Obes Metab*. 2018;21(30):454-66.

31. Vilsbøll T, Bain SC, Leiter LA, et al. Semaglutide, reduction in glycated haemoglobin and the risk of diabetic retinopathy. *Diabetes Obes Metab*. 2018;20(4):889-97.

32. Marso SP, Bain SC, Consoli A, et al. Semaglutide and cardiovascular outcomes in patients with type 2 diabetes. *N Engl J Med*. 2016;375(19):1834-44.

33. Berkovic MC, Strollo F. Semaglutide-eye-catching results. *World J Diabetes*. 2023;14(4):424-34.

34. Stewart S. Fenofibrate for diabetic retinopathy. *Asia Pac J Ophthalmol (Phila)*. 2018;7(6):422-6.

35. Ngah NF, Muhamad NA, Abdul Aziz RA, et al. Fenofibrate for the prevention of progression of non-proliferative diabetic retinopathy: review, consensus recommendations and guidance for clinical practice. *Int J Ophthalmol*. 2022;15(12):2001-8.

36. NCT04661358. Fenofibrate for prevention of DR worsening (Protocol AF). clinicaltrials.gov/study/NCT04661358. Last updated March 27, 2024. Accessed April 23, 2024.

37. Keech A, Simes RJ, Barter P, et al.; FIELD study investigators. Effects of long-term fenofibrate therapy on cardiovascular events in 9,795 people with type 2 diabetes mellitus (the FIELD study): randomised controlled trial. *Lancet*. 2005;366(9500):1849-61.

38. Keech AC, Mitchell P, Summanen PA, et al.; FIELD study investigators. Effect of fenofibrate on the need for laser treatment for diabetic retinopathy (FIELD study): a randomised controlled trial. *Lancet*. 2007;370(9600):1687-97.

39. Chew EY, Davis MD, Danis RP, et al. The effects of medical management on the progression of diabetic retinopathy in persons with type 2 diabetes: the Action to Control Cardiovascular Risk in Diabetes (ACCORD) Eye Study. *Ophthalmology*. 2014;121(12):2443-51.

40. Wong TY, Simó R, Mitchell P. Fenofibrate - a potential systemic treatment for diabetic retinopathy? *Am J Ophthalmol*. 2012;154(1):6-12.

41. Shi C, Wang P, Airen S, et al. Nutritional and medical food therapies for diabetic retinopathy. *Eye Vis (Lond)*. 2020;7:33.

42. Kowluru RA, Zhong Q, Santos JM, et al. Beneficial effects of the nutritional supplements on the development of diabetic retinopathy. *Nutr Metab (Lond)*. 2014;11(1):8.

43. Chous AP, Richer SP, Gerson JD, Kowluru RA. The Diabetes Visual Function Supplement Study (DiFuSS). *Br J Ophthalmol*. 2016;100(2):227-34.

44. Liu Z, Jiang H, Townsend JH, Wang J. Improved retinal microcirculation in mild diabetic retinopathy patients carrying MTHFR polymorphisms who received the medical food, Ocufolin. *Clin Ophthalmol*. 2022;16:1497-504.

45. Gross JG, Glassman AR, Liu D, et al.; Diabetic Retinopathy Clinical Research Network. Five-year outcomes of panretinal photocoagulation vs. intravitreal ranibizumab for proliferative diabetic retinopathy: a randomized clinical trial. *JAMA Ophthalmol*. 2018;136(10):1138-48.

46. Obeid A, Su D, Patel SN, et al. Outcomes of eyes lost to follow-up with proliferative diabetic retinopathy that received panretinal photocoagulation vs. intravitreal anti-vascular endothelial growth factor. *Ophthalmology*. 2019;126(3):407-13.

47. Wyckoff CC, Abreu F, Adams AP, et al. YOSEMITE and RHINE Investigators. Efficacy, durability and safety of intravitreal faricimab with extended dosing up to every 16 weeks in patients with diabetic macular oedema (YOSEMITE and RHINE): two randomized, double-masked, Phase III trials. *Lancet*. 2022;399(10326):741-55.

48. DME: extended dosing. eyeahcp.us/s/eyeahd/dme-extended-dosing. Accessed April 23, 2024.

49. DME: vision outcomes. eyeahcp.us/s/eyeahd/dme-vision-outcomes. Accessed April 23, 2024.

50. Chawan-Saad J, Wu M, Wu A, Wu L. Corticosteroids for diabetic macular edema. *Taiwan J Ophthalmol*. 2019;9(4):233-242.

UNDERSTANDING UVEITIS: CAUSES AND CLINICAL CLUES

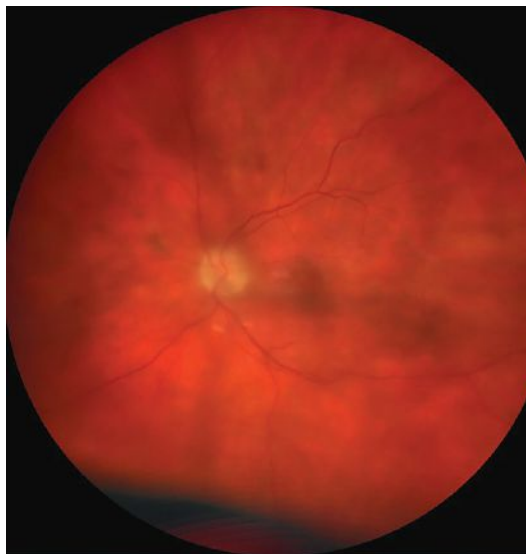We dive into common and uncommon etiologies for this condition and give advice on how to come up with a proper differential diagnosis for each patient.



BY TUNDE TRENNEPOHL, OD,
WILLIAM HILEMAN, OD, AND
DANIEL GRANGAARD, OD
CHILLICOTHE, OH

Uveitis is the most common cause of ocular inflammation but also one of the most mysterious, given the wide range of both potential inciting factors and ocular structures involved. Depending on the affected anatomical site, uveitis is divided into four subcategories: anterior, intermediate, posterior and panuveitis.¹ Anterior and intermediate uveitis refer specifically to the anterior chamber/iris and the vitreous/peripheral retina, respectively. In similar fashion, posterior uveitis refers to inflammation of the choroid. Panuveitis is a term used to describe simultaneous inflammation of the entire uveal tract, affecting the anterior chamber, vitreous and choroid.¹

An estimated 15% to 30% of uveitis cases are of the posterior variety, making it the second most common form behind anterior uveitis. Following that, panuveitis is the third most common form of uveitis in western countries.²



Patient with panuveitis demonstrating significant vitreal haze.

The prevalence of uveitis has been estimated as high as 714 cases per 100,000 people.² Uveitis, specifically posterior and panuveitis, can be visually debilitating, as it causes 10% to 15% of blindness in the world and is one of the leading causes of blindness in the

United States.³ Panuveitis in particular has been correlated with a poorer visual prognosis. Given the prevalence of uveitis and the potential visual impact of posterior uveitis and panuveitis, it is important to understand characteristic presentations and etiologies for accurate diagnosis, which we will discuss extensively below.²

Creating an Accurate Differential Diagnosis

Forming an accurate differential list for posterior uveitis can be challenging. The most important step is taking a good history, as this condition can be caused by many dif-

ferent etiologies. Items to include are a complete medical history—including present and past personal medical history—surgeries, history of trauma, medicines and family history, along with demographics—age, sex and ethnicity. Other history items are arthritis,

About the authors

Dr. Trennepohl graduated from the Ohio State University College of Optometry and completed an ocular disease residency at the Chillicothe and Columbus VA. She is a staff optometrist at the Chillicothe VA Medical Center and at the Lancaster VA community-based outreach clinic. **Dr. Hileman** graduated from Illinois College of Optometry and completed his ocular disease residency at the Chillicothe and Columbus VA. He is the Chief of the Optometry Service at the Chillicothe VA Medical Center and is board-certified by the ABCMO. **Dr. Grangaard** graduated from the Ohio State University College of Optometry and completed his ocular disease residency at the Chillicothe and Columbus VA. He serves as the co-residency director at the Chillicothe VA Medical Center, is a fellow of the American Academy of Optometry and is board-certified in medical optometry. They have no financial disclosures.

rashes, shortness of breath, swollen lymph nodes, recent headaches, hearing difficulties, hair loss, pigment changes in the skin, a history of ocular trauma, recent insect bites, sexually transmitted diseases, tuberculosis exposure, blood in stools and recent travel. It's also important to include current history of present illness including onset, duration, laterality, course, associations and modifying factors.⁴

Some patients have no symptoms with posterior uveitis; others present with acute floaters, loss of vision, photopsia and rarely pain. For panuveitis, floaters, loss of vision and photopsia can occur, along with symptoms of anterior uveitis including pain, hyperemia and light sensitivity.^{4,5}

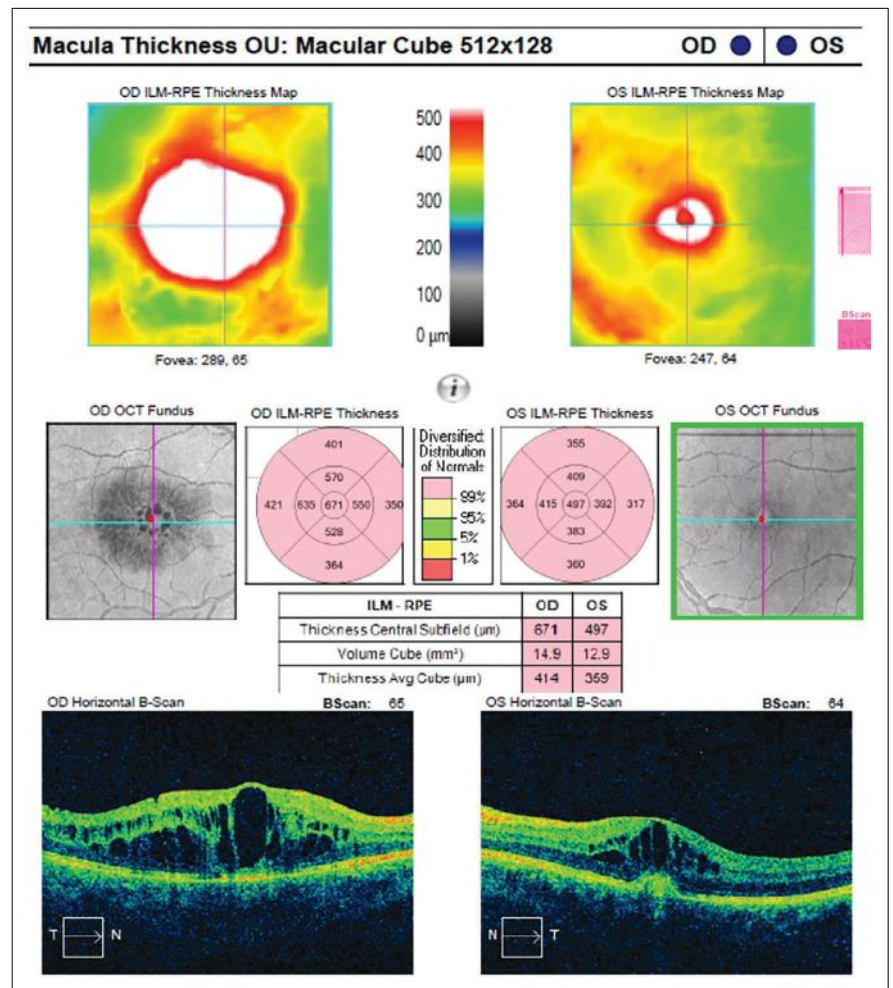
A thorough examination is also essential to forming differentials, including visual acuity, pupil testing, extraocular muscles, intraocular pressure, slit lamp examination and biomicroscopy. Determining which parts of the uveal tract have inflammation will also aid in the determination of your differential. Some disease processes will affect just the choroid (posterior uveitis) and others will affect the iris, ciliary body and choroid (panuveitis).⁵

Posterior uveitis presents with a myriad of potential clinical signs to identify: vitreal cells, flare and opacities, retinitis, vasculitis, peripheral periphlebitis, edema of the retina, macular or optic disc, retinal hemorrhages and vitreal hemorrhage. Complications of the inflammatory response include choroidal neovascular membranes, retinal detachment, retinal vascular occlusions, ischemia and retinal necrosis.

Panuveitis has similar signs and complications in the posterior aspect of the eye, but also affects the intermediate and anterior uveal tract. These signs include pars planitis, cells and flare in the anterior chamber and circumlimbal hyperemia.³⁻⁵

Many times, the signs you see during examination will guide your differentials. Consider the following questions:

1. Is it posterior uveitis only or is it part of a panuveitis?



Significant bilateral macular edema secondary to bilateral panuveitis.

2. Is it choroiditis, retinitis, chorioretinitis or retinochoroiditis?

3. Is there associated involvement of the optic nerve head and/or the retinal vessels?

4. Does the clinical feature fit into any known infective or non-infective entity?

5. Is there associated anterior segment inflammation, vitritis or complications?

6. Is it associated with other systemic features?

7. Is it recurrent? If so, how has it responded to previous therapy?

8. Is it associated with an immunocompromised state?

9. Is it a masquerade syndrome?⁶

Ancillary testing can also aid in the differential diagnosis of posterior uveitis. Fundus photography can be used

to identify the extent of the inflammation and retinal changes. Fundus autofluorescence (FAF) can be useful in many cases of posterior uveitis, especially when evaluating white dot syndromes.

FAF patterns will vary depending on the type of white dot syndrome. Serpiginous choroidopathy shows large areas of hypoautofluorescence emanating from the optic nerve that are associated with atrophy in inactive lesions, whereas new lesions are associated with hyperautofluorescence. Another example of a unique pattern is found in acute zonal occult outer retinopathy with peripapillary hypoautofluorescence and a granular mixture of hyper- and hypoautofluorescence associated with active extension into the arcades.^{7,8}

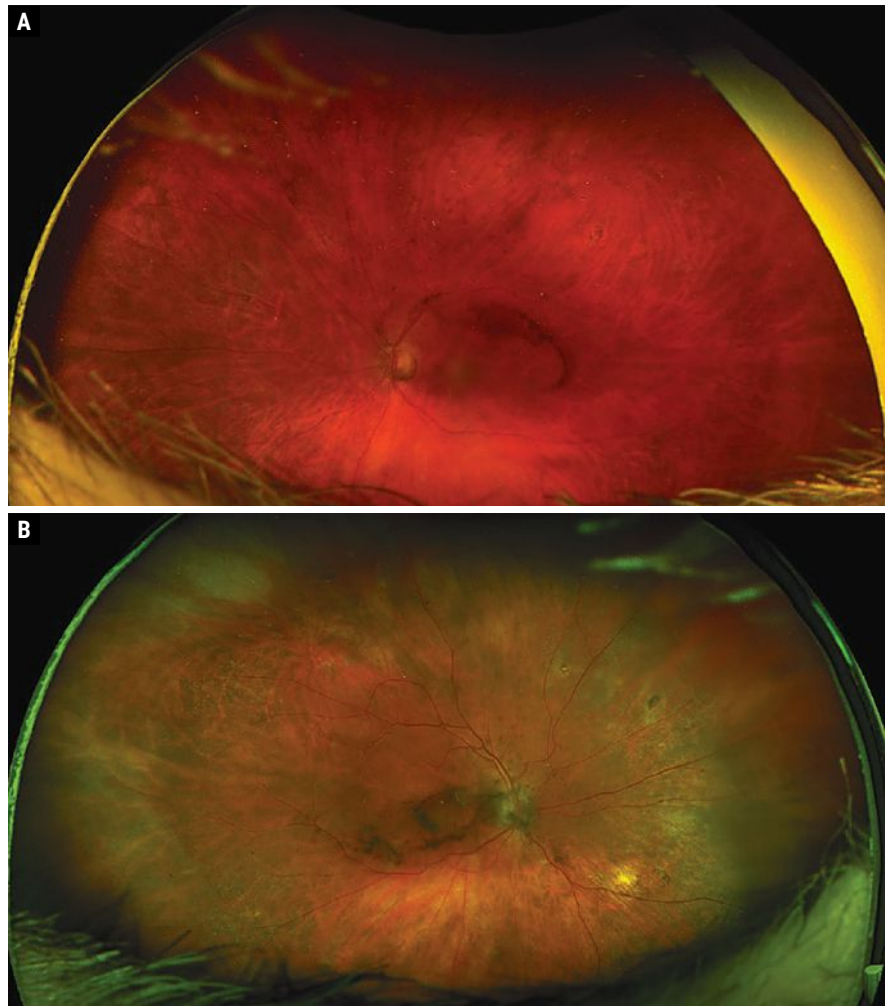
OCT is commonly used to identify changes in the posterior segment, including retinal, macular and optic disc edema, retinal atrophy, choroidal thickening and other changes.^{8,9} OCT-A can further help identify changes in blood vessel density and detection of choroidal neovascular membranes.⁹ Fluorescein angiography is used to detect and evaluate extent of retinal vasculitis, macular edema, papillitis and capillary nonperfusion. Ultrasounds are most useful when visualization of the fundus is obscured from vitritis as well as evaluating extent of exudative retinal and/or choroidal detachments when present. Indocyanine green angiography is an important imaging modality for disease that have a predominance for the choroid (*e.g.*, Vogt-Koyanagi-Harada disease, bird-shot chorioretinopathy).

Other systemic testing can be useful when identifying the cause of posterior uveitis, such as a chest X-ray, which should be considered when suspecting sarcoidosis or tuberculosis. If it's sarcoidosis, bilateral hilar lymphadenopathy will show up and tuberculosis commonly shows lymphadenopathy, pleural effusion and caseating granulomas.^{10,11} MRIs can sometimes be useful when diagnosing neurosyphilis, as they will detect vasculitis of the small and middle cerebral arteries, infarction and hemorrhaging, although findings are not highly specific.¹²

Etiologies

It is important to understand the underlying etiology of the disease process to guide treatment and referrals that may be necessary. There are specific and non-specific labs that should be considered when determining a diagnosis, and a proper examination will help narrow down the labs that should be ordered. In many cases, lab work will assist in confirming a diagnosis or ruling out important differential diagnoses.

While uveitis can be idiopathic, posterior uveitis has a higher likelihood of a concomitant systemic medical condition. In over 75% of posterior uveitis



Bilateral posterior uveitis secondary to sarcoidosis.

cases, a specific diagnosis was found.¹³ Posterior and panuveitis have many different etiologies, the most common being infectious and inflammatory. They are usually associated with systemic medical conditions but can also be linked to primary ocular conditions. The most common etiologies and their typical presentations are divided into three general categories: infectious, inflammatory and ocular syndromes. We will cover the two most common categories, infectious and inflammatory, in more detail:

Infectious

It is always important to rule out infectious etiologies for posterior uveitis, and to know which infections to consider can help guide you in making an accurate diagnosis. A helpful mne-

monic when coming up with differentials for infectious posterior uveitis is "STTEEVE":¹⁴

- S – Syphilis
- T – Tuberculosis (TB)
- T – Toxoplasmosis
- E – Endogenous
- E – Endophthalmitis
- V – Viral (herpes simplex, herpes zoster, cytomegalovirus)
- E – Etc. (*e.g.*, *Bartonella*, toxocariasis)

Several bacterial infections cause posterior or panuveitis, but the most common are syphilis and TB. Syphilis is the result of an infection with the spirochete *Treponema pallidum* and can result in many systemic and/or ocular manifestations.^{15,16} Posterior uveitis presents in several different ways, including localized chorioretinitis or retinitis, which can be non-specific

and mimic other diseases and is why syphilis is often called the “great masquerader.” Chorioretinal lesions are typically multifocal and bilateral and are associated with vitritis and/or exudative retinal detachment. Retinitis has been described as having a “ground glass” appearance and may be associated with vasculitis as well.^{15,16} Acute syphilitic posterior placoid chorioretinopathy is a more specific presentation of syphilitic posterior uveitis that appears most commonly as pale yellow, gray or white placoid lesions in the outer retina of varying size within the posterior pole.¹⁷ This lesion can best be visualized through FAF on which the placoid lesions hyperautofluoresce.¹⁷

TB is a chronic bacterial infection caused by *Mycobacterium tuberculosis*. While acute infection is uncommon, many people can have latent TB and ocular TB can manifest without any systemic symptoms.¹⁸ Any part of the eye can be involved; however, uveitis is the most common ocular manifestation and occurs as either anterior, intermediate or posterior.¹⁸ Posterior uveitis in TB can have a wide range of manifestations, including retinitis, choroidal granulomas (e.g., tubercles and tuberculomas) and serpiginous choroiditis.^{14,18} Tubercles are the most recognizable ocular sign and appear as unilateral or bilateral, multiple (less than five), small, grayish white or yellow elevated lesions of the posterior pole with indistinct margins, lying deep within the choroid.¹⁸ Tuberculomas are larger and more often solitary with overlying hemorrhages and a more characteristic tumor-like appearance.^{14,18}

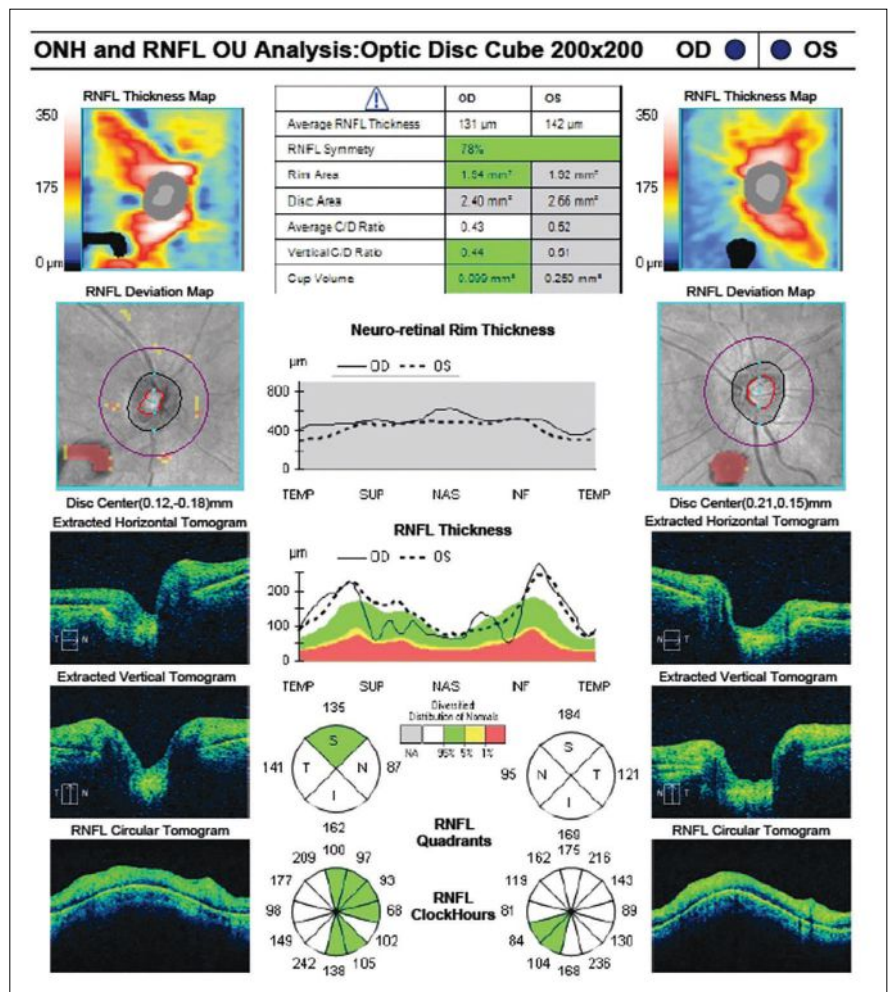
Multifocal serpiginous choroiditis or serpiginous-like choroiditis, more common in TB endemic countries, present as multifocal lesions that are spread in a centrifugal serpiginous pattern sparing the peripapillary region and often accompanied by a vitritis.^{14,18}

Toxoplasmosis, unlike syphilis and TB, is caused by a parasite, *Toxoplasma gondii*. It is the most common cause of infectious posterior uveitis in the world and classically presents as

a unilateral focal necrotizing chorioretinitis with overlying vitritis.^{14,19} This presentation is often taught as having a “headlights-in-the-fog” appearance due to the hazy bright whitish yellow lesion in the retina clouded by the overlying vitritis.^{19,20} It is common for an active lesion to be adjacent or close to an existing chorioretinal scar, suggesting reactivation of a previous infection. Infections often remains active for up to 16 weeks, leaving behind a hyperpigmented scar.¹⁴ Lesions are often found in the posterior pole and may even be accompanied by optic nerve edema. Macular scarring is one of the most common causes of vision loss secondary to toxoplasmosis posterior uveitis. A new infection without a pre-existing scar is relatively uncommon and typically only present in patients who are immunocompromised.²⁰

Endogenous endophthalmitis is another potential infectious cause of posterior uveitis and panuveitis. The most common fungal culprits are *Candida*, *Aspergillus* and *Coccidiomycosis*, and present as creamy, white, discrete chorioretinal lesions of the posterior pole with overlying vitritis (fluffy cotton ball or string of pearls appearance).¹⁴ Endogenous bacterial endophthalmitis can be caused by a wide variety of bacteria.

Viral infections can lead to both posterior and panuveitis; however, anterior and intermediate uveitis are more common presentations. The most likely viral candidates for uveitis include herpes viruses: herpes simplex, varicella zoster and cytomegalovirus.¹⁴ The two most common manifestations of viral posterior uveitis are acute retinal necrosis (ARN) and progressive outer retinal



Bilateral posterior uveitis with accompanying optic nerve head edema in both eyes.

necrosis (PORN). ARN is typically found in immunocompetent patients while PORN is more common in those who are immunocompromised.^{14,21,22}

ARN begins with painful iritis and vitritis that eventually develops areas of hemorrhagic necrotizing retinitis, which presents with retinal whitening adjacent to retinal arteritis and retinal hemorrhages. Patients may also develop occlusive retinal vasculitis, optic neuritis or preretinal neovascularization.^{21,23} Necrosis is typically circumferential and progression is often rapid if left untreated.¹⁴

Unlike ARN, PORN does not typically present with a vitritis or occlusive vasculitis.²⁴ There are three main stages of PORN retinitis. The early stage involves multifocal yellow-white infiltrates often involving the macula. The middle, or established phase, presents as disseminated and extensive full-thickness retinal necrosis with minimal vasculitis or hemorrhages. The late stage presents as optic atrophy and often involves rhegmatogenous retinal detachment. Both ARN and PORN can be unilateral or bilateral and lead to severe vision loss even with treatment.²²

CMV retinitis is also found mainly in patients who are immunocompromised and is a common opportunistic infection in patients with acquired immunodeficiency syndrome.²⁵ Patients are often asymptomatic but can present with photopsia, vision loss or floaters, and are rarely ever in pain. Key characteristics include retinal necrosis and vasculitis which are often accompanied by a mild vitritis. Vasculitis and hemorrhaging are the classic presentation often called “pizza-pie” or “ketchup and cottage cheese” due to the mixed white and red areas seen in the retina. Rarely, optic neuritis can also occur.^{14,25}

Toxocariasis and *Bartonella* are two additional infections that can cause posterior uveitis, although it is relatively rare. Toxocariasis is caused by the parasitic roundworms *Toxocara canis* or *Toxocara cati*, found in dog or cat feces.²⁶ It typically presents as posterior pole or peripheral granulomas which histopathologically contain roundworm

fragments.²⁶ Additional complications include chronic endophthalmitis and retinal detachment.²⁶ *Bartonella henselae* or cat scratch disease, is often caused by a cat scratch or bite.²⁷ Ocular manifestations include uveitis, vitritis, retinitis, choroiditis and optic neuritis.²⁷

Inflammatory

Systemic inflammatory conditions can also lead to posterior or panuveitis, although anterior uveitis is significantly more common. While any inflammatory condition can potentially cause posterior findings, we will focus on the three most likely candidates: sarcoidosis, Vogt-Koyanagi-Harada syndrome (VKH) and Beçhet’s disease.

Sarcoidosis is a multi-systemic inflammatory condition that results in granulomas developing throughout the body, most often in the lungs and lymph nodes. Ocular involvement is fairly common, with sarcoidosis being one of the most common systemic causes of uveitis. About 28% of patients with ocular sarcoidosis will develop posterior uveitis, and 9% to 30% will have panuveitis.²⁸ Retinal periphlebitis is the most common manifestation of sarcoidosis posterior uveitis, with characteristic “candle-wax drippings” that appear as yellow or white segmented perivenous sheathing, often accompanied by vitritis.²⁸ It is also possible to develop peripheral retinal neovascularization secondary to vascular occlusion

or chronic retinal ischemia, which can present in a “sea-fan” pattern and be mistaken for sickle cell anemia, especially in African American patients.³ Multifocal choroiditis may also occur, and presents as creamy white or yellow lesions most likely in the inferior periphery.²⁸

VKH is an idiopathic inflammatory condition that attacks melanocyte-containing tissues (including the uvea, ear and meninges) whose primary manifestation is often ocular. It is commonly associated with neurological, auditory and integumentary manifestations.²⁹ Neurologic symptoms can include headaches and nuchal rigidity (neck stiffness); auditory symptoms may include tinnitus and/or hearing loss, and cutaneous manifestations can include vitiligo, alopecia and poliosis.

VKH usually presents as a chronic bilateral granulomatous panuveitis with exudative retinal detachments. Therefore, one of the most common complaints in patients with VKH is sudden vision loss with or without eye pain, accompanied by hearing complaints.²⁹

There are typically three main stages of disease:

- First is the prodromal stage, occurring about one to two weeks before onset of uveitis (headache, nausea, vomiting).
- Next is the acute uveitic phase, often characterized by diffuse choro-

TABLE 1. LAB TESTS TO CONSIDER FOR COMMON ETIOLOGIES OF POSTERIOR/PANUVEITIS

Etiology	Lab Test(s)
Toxoplasmosis	Toxoplasma IgG/IgM
Syphilis	FTA-ABS, RPR
Tuberculosis	PPD, Quantiferon Gold, IGRAS
Sarcoidosis	ACE, CBC, lysozyme
Beçhet’s	HLA-B51
Viral (HSV, VZV, CMV)	PCR
Birdshot chorioretinopathy	HLA-A29
Vogt-Koyanagi-Harada	CSF pleocytosis

ditis, optic nerve swelling, vitritis and exudative retinal detachment.²⁹

• Lastly, the chronic or recurrent phase involves depigmentation of the retinal pigment epithelium resulting in a “sunset glow” fundus.²⁹ Anterior uveitis is more common in recurrent cases as well as choroidal neovascularization.

Beçhet’s disease is another chronic autoimmune disorder that can affect many different parts of the body, including the eyes, mouth, skin and genitals. It is primarily an occlusive vasculitis involving small, medium and large veins and arteries.³⁰ Primary manifestations include uveitis (most common), oral ulcers and genital ulcers.³⁰ Uveitis is not only the most common ocular presentation but also the most common general presentation of the disease and is often a relapsing and remitting panuveitis with retinal vasculitis.³⁰ Initial findings may be unilateral but often progress to become bilateral. A mobile hypopyon is also observed in many cases.³ Posterior findings can be diverse, although scattered yellow or white infiltrates with surrounding hemorrhages is common and may be accompanied by vascular engorgement and/or optic disc hyperemia.³⁰

Other Etiologies

There are a few other potential etiologies for posterior and panuveitis that should be kept in mind as differentials. Primary idiopathic chorioretinopathies, or “white dot syndromes,” should be on the differential list, although they are uncommon compared to other forms of posterior uveitis.³¹ Multiple evanescent white dot syndrome (MEWDS) and acute posterior multifocal placoid pigment epitheliopathy (APMPPE) are two of the most common white dot syndromes.³²

MEWDS usually presents in a younger population, predominantly affecting females between the age of 20 to 50 years old. Typically, MEWDS presents unilaterally with small white granular dots in the outer retina and patients often will have a viral “flu-like” prodrome of symptoms in cases of MEWDS.³³ Similarly, APMPPE

affects younger patients in age range of 20 to 30 years old. APMPPE does not show any gender predilection and in contrast to MEWDS, presents bilaterally with larger gray or white placoid shaped lesions within the layers of the RPE and inner choroid. Fortunately, both MEWDS and APMPPE have a good visual prognosis and are self-limiting conditions that usually only require observation.^{31,32}

Takeaways

Posterior uveitis and panuveitis are common causes of inflammation in the eye that can cause significant and irreversible vision loss. Early recognition and detection is important to recognize the symptoms and signs early to help minimize vision loss. Because of the many different etiologies (infectious, inflammatory and ocular syndromes) that can be causing the uveitis, developing good strategies and approaches to aid in prompt diagnosis are essential to good patient outcomes. A good history and examination will help guide your differential diagnosis and medical decision-making. Ancillary testing like fundus photos, FAF, OCT and FA can help identify areas of the eye that are affected by the inflammation. Laboratory tests are also a useful tool in identifying the underlying systemic cause of the uveitis. ■

1. Papaliadis G. Uveitis: etiology, manifestations and diagnosis. www.uptodate.com/contents/uveitis-etiology-clinical-manifestations-and-diagnosis?search=posterior%20uveitis&source=search_result&selectedTitle=1%7E150&usage_type=default&display_rank=1. Accessed March 29, 2024.
2. Wakefield D, Chang JH. Epidemiology of uveitis. *Int Ophthalmol Clin*. 2005;45(2):1-13.
3. Rathinam SR, Babu M. Algorithmic approach in the diagnosis of uveitis. *Indian J Ophthalmol*. 2013;61(6):255-62.
4. Lukic M. Posterior Uveitis and Panuveitis. viewpoint.online/handbook/ocular-pathology-atlas/posterior-uveitis-and-panuveitis/
5. Duplechain A, Conrady CD, Patel BC, et al. Uveitis. [Updated 2023 Aug 8]. In: StatPearls [Internet]. Treasure Island (FL): StatPearls Publishing; Jan 2024. Available from: <https://www.ncbi.nlm.nih.gov/books/NBK540993/>
6. Sudharshan S, Ganesh SK, Jyotrimay B. Current approach in the diagnosis and management of posterior uveitis. *Indian J Ophthalmol*. 2010;58(1):29-43.
7. Meleth AD, Sen HN. Use of fundus autofluorescence in the diagnosis and management of uveitis. *Int Ophthalmol Clin*. 2012;52(4):45-54.
8. Agarwal A, Pichi F, Invernizzi A, et al. Stepwise approach for fundus imaging in the diagnosis and management of posterior uveitis. *Surv Ophthalmol*. 2023;68(3):446-80.
9. Tranos P, Karasavidou EM, Gkorou O, Pavesio C.

Optical Coherence Tomography Angiography in Uveitis. *J Ophthalmic Inflamm Infect*. 2019;9:21.

10. Criado E, Sanchez M, Ramirez J, et al. Pulmonary sarcoidosis: typical and atypical manifestations at high-resolution CT with pathologic correlation. *Radiographics*. 2010;30(6):1567-86.

11. Andreu J, Cáceres J, Pallisa E, Martínez-Rodríguez M. Radiological manifestations of pulmonary tuberculosis. *Eur J Radiol*. 2004;51(2):139-49.

12. Czarnowska-Cubała M, Wiglusz MS, Cubała WJ, et al. MR findings in neurosyphilis - a literature review with a focus on a practical approach to neuroimaging. *Psychiatr Danub*. 2013;25 Suppl 2:S153-7.

13. Barisani-Asenbauer T, Maca SM, Mejdoubi L, et al. Uveitis - a rare disease often associated with systemic diseases and infections- a systematic review of 2619 patients. *Orphanet J Rare Dis*. 2012;29(7):57.

14. Mandelcorn ED. Infectious causes of posterior uveitis. *Can J Ophthalmol*. 2013;48(1):31-9.

15. Hughes EH, Guzowski M, Simunovic MP, et al. Syphilitic retinitis and uveitis in HIV-positive adults. *Clin Exp Ophthalmol*. 2010;38(9):851-6.

16. Artaechevarria Artieda J, Estébanez-Corrales N, Muñoz N, et al. Spectrum of syphilitic chorioretinitis and its evolution based on multimodal imaging. *Ocul Immunol Inflamm*. 2022;30(7-8):1639-50.

17. Ormaechea MS, Hassan M, Nguyen QD, Schlaen A. Acute syphilitic posterior placoid chorioretinopathy: an infectious or autoimmune disease? *Am J Ophthalmol Case Rep*. 2019;14:70-3.

18. Gupta A, Gupta V. Tubercular posterior uveitis. *Int Ophthalmol Clin*. 2005;45(2):71-88.

19. Goh EJH, Putera I, La Distia Nora R, et al. Ocular toxoplasmosis. *Ocul Immunol Inflamm*. 2023;31(7):1342-61.

20. Bonfili AA, Orefice F. Toxoplasmosis. *Semin Ophthalmol*. 2005;20(3):129-41.

21. Bonfili AA, Eller AW. Acute retinal necrosis. *Semin Ophthalmol*. 2005;20(3):155-60.

22. Lo PF, Lim R, Antonakis SN, Almeida GC. Progressive outer retinal necrosis: manifestation of human immunodeficiency virus infection. *BMJ Case Rep*. 2015;2015:bcr2014207344.

23. Lightman S. Acute retinal necrosis. *Br J Ophthalmol*. 1991;75(8):449.

24. Tseng CC, Chen SN, Hwang JF, et al. Progressive outer retinal necrosis associated with occlusive vasculitis in acquired immunodeficiency syndrome. *J Formos Med Assoc*. 2015;114(5):469-72.

25. Taylor GH. Cytomegalovirus. *Am Fam Physician*. 2003;67(3):519-24.

26. Lin P. Infectious Uveitis. *Curr Ophthalmol Rep*. 2015;3(3):170-83.

27. Hong H, Li T, Ying Y, et al. Cat-scratch disease manifesting as uveitis and binocular fundus nodular lesions: a case report. *BMC Ophthalmol*. 2023;23(1):345.

28. Jamilloux Y, Kodjikian L, Broussolle C, Sève P. Sarcoidosis and uveitis. *Autoimmun Rev*. 2014;13(8):840-9.

29. Fang W, Yang P. Vogt-koyanagi-harada syndrome. *Curr Eye Res*. 2008;33(7):517-23.

30. Ksaa I, Abroug N, Kechida M, et al. Eye and Behçet’s disease. *J Fr Ophthalmol*. 2019;42(4):e133-46.

31. Cozubas R, Ungureanu E, Luminita Instrate S, et al. Similarities and differences between three different types of white dot syndrome and the therapeutic possibilities. *Rom J Ophthalmol*. 2018;62(3):183-7.

32. Mount GR, Kaufman EJ. White Dot Syndromes. *PubMed*. StatPearls Publishing, 2022. March 13, 2023. Accessed May 8, 2024.

33. Tavallali A, Yannuzzi LA. MEWDS, common cold of the retina. *J Ophthalmic Vis Res*. 2017;12(2):132-4.

ARE YOU UP TO SPEED ON INHERITED RETINAL DYSTROPHIES?

Enhance your patient care with an improved understanding of these genetic disorders and how they present in clinical practice.



BY ROYA ATTAR, OD,¹ RACHEL STEELE, OD,² AND JIM WILLIAMSON, OD²

¹JACKSON, MS; ²MEMPHIS

Inherited retinal dystrophies (IRDs) encompass a group of genetic disorders affecting the retina, often leading to progressive vision loss. Their prevalence hovers around one in 1,400 individuals, which means most practitioners will see at least several per year. Some IRDs masquerade as other disorders, while others are clinically obvious. Genetic testing doesn't always offer confirmation, but when it does, it provides insight into the prognosis, inheritance pattern, current or future trials and possible syndromic features. Optometrists should recognize these entities and their nuanced characteristics to guide their testing strategy and arrive at the correct diagnosis.¹

This article aims to provide a comprehensive overview of key IRDs, such

as Stargardt's disease, pattern dystrophies and retinitis pigmentosa (RP). We will delve into the causes and clinical presentations while also discussing the clinical value of genetic testing.

Stargardt's Disease (STGD1)

This condition is the most commonly inherited juvenile retinal dystrophy, with an estimated incidence of one in 8,000 or one in 10,000.² The inheritance pattern is autosomal recessive, requiring biallelic variations in the *ABCA4* gene, which has also been implicated in childhood-onset cone-rod dystrophy, bull's eye maculopathy and RP.²

The *ABCA4* gene codes for an ATP-binding cassette transporter that plays a role in the visual cycle in recycling all-trans-retinal.³ When dysfunctional, this protein leads to accumulation of N-retinylidene-N-retinylethanolamine (A2E) within the retinal pigment epithelium (RPE), resulting in eventual photoreceptor cell death.^{3,4} Currently, there have been over 2,200 *ABCA4* variations reported.⁴

While *ABCA4* disease can manifest in a range of phenotypes, STGD1 classically produces a beaten-bronze fundus appearance with whitish, yellow subretinal pisciform flecks scattered throughout the posterior pole with varying degrees of photoreceptor atrophy (*Figure 1*). The age of onset may vary from early-onset to early-adult onset to late-onset; however, the average age is about 15 years.⁵

Early-onset *ABCA4* disease is associated with inheritance of two severe variants of the gene and may progress to severe vision loss early in life due to extensive outer retinal atrophy.⁵ Late-onset disease is thought to be caused by one severe variant and one mild variant of the *ABCA4* gene and generally results in less severe disease. However, it can result in extrafoveal outer retinal atrophy, which may be misdiagnosed as geographic atrophy from AMD.⁴

In up to a quarter of cases, patients with early-onset disease may have reduced vision with no abnormalities detectable on clinical examination.⁶

About the authors

Dr. Attar is an assistant professor in the department of ophthalmology and director of optometric services at the University of Mississippi Medical Center. She is a fellow of the American Academy of Optometry (AAO), chair of the AAO Retina Special Interest Group and vice chair of the American Optometric Society Leadership Development Committee. She is on advisory boards for Heidelberg Engineering, Apellis and OcuTerra Therapeutics. **Dr. Steele** completed her ocular disease residency at the Memphis VA. She is currently completing her fellowship at the Charles Retina Institute and is a consulting faculty member at Southern College of Optometry. She has no financial disclosures. **Dr. Williamson** is the residency supervisor at the Memphis VA Medical Center. He holds faculty positions at multiple optometry schools and allied health programs and is a fellow of the American Academy of Optometry and the Optometric Retina Society. Dr. Williamson also serves as the secretary for the Optometric Retina Society. He has no financial disclosures.

Multimodal imaging can reveal early, subtle findings, including thickening of the foveal or parafoveal external limiting membrane on OCT. Fundus autofluorescence (FAF) may show hyper-autofluorescent flecks or general hyper-autofluorescence that might not be apparent on clinical examination.

OCT findings of more advanced disease include thinning of the ONL, loss of the ellipsoid zone (EZ) and RPE atrophy. Pisciform flecks appear on OCT as hyperreflective sub-retinal deposits and hyper-reflective foci, which may disrupt the EZ and extend into the inner retinal layers. Early-phase intravenous fluorescein angiography (IVFA) classically reveals a “silent choroid,” where the expected choroidal flush is masked by abnormal accumulation of lipofuscin within RPE cells.

Differentiating STGD1 from masqueraders, such as AMD, is increasingly important with emerging invasive therapies for geographic atrophy (*i.e.*, pegcetacoplan and avacincaptad pegol).⁴ A distinguishing factor includes the presence of drusen. Drusen are clinically well-defined, round, yellow lesions visible on clinical exami-

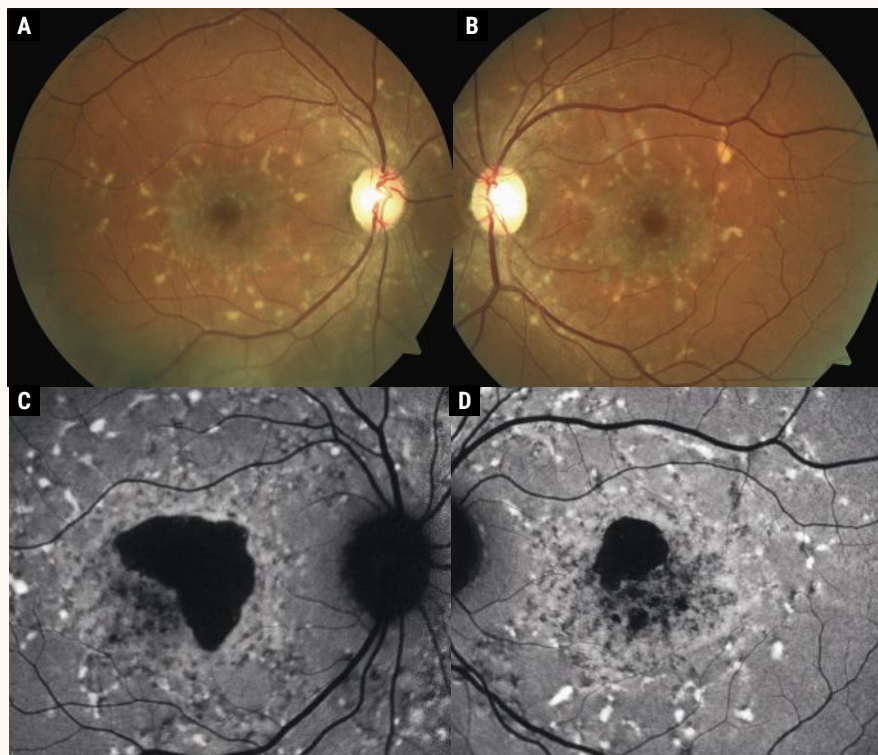


Fig. 1. Color fundus photographs (A, B) of Stargardt’s disease. These photos demonstrate the classic STGD1 phenotype of white, pisciform flecks scattered throughout the posterior pole with the presence of atrophic macular lesions. Fundus autofluorescence (C, D) demonstrates the hyper-autofluorescent nature of the pisciform flecks, in contrast to drusen, which are often iso-autofluorescent.

nation, while the flecks in Stargardt’s are often whitish yellow, with an

ill-defined pisciform shape, and may be difficult to discern clinically.

Are You Up to Speed on Inherited Retinal Dystrophies?

Jointly provided by Postgraduate Institute for Medicine (PIM) and Review Education Group

Release Date: June 15, 2024

Expiration Date: June 15, 2027

Estimated Time to Complete Activity: two hours

Target Audience: This activity is intended for optometrists who are interested in a comprehensive overview of key inherited retinal dystrophies, along with appropriate clinical examination and ancillary testing.

Educational Objectives: After completing this activity, participants should be better able to:

- Recognize the presentations of various inherited retinal dystrophies.
- Effectively diagnosis inherited retinal dystrophies in clinical practice.
- Recognize the value and limitations of genetic testing for these patients.
- Determine which IRD patients could benefit from genetic testing.

Faculty: Roya Attar, OD, Rachel Steele, OD, and Jim Williamson, OD

Disclosure of Conflicts of Interest: PIM requires faculty, planners and others in control of educational content to disclose all their financial relationships with ineligible companies. All identified conflicts of interest are thoroughly vetted and mitigated according to PIM policy. PIM is committed to providing its learners with high-quality, accredited CE activities and related materials that promote improvements or quality in health care and not a specific proprietary business interest of an ineligible company.

Those involved reported the following relevant financial relationships with ineligible entities related to the educational content of this CE activity: *Faculty* – Drs. Steele and

Williamson have nothing to disclose. Dr. Attar is on advisory boards for Heidelberg Engineering, Apellis and OcuTerra Therapeutics. *Planners and Editorial Staff* – PIM has nothing to disclose. The Review Education Group has nothing to disclose.

Accreditation Statement: In support of improving patient care, this activity has been planned and implemented by PIM and the Review Education Group. PIM is jointly accredited by the Accreditation Council for Continuing Medical Education, the Accreditation Council for Pharmacy Education and the American Nurses Credentialing Center to provide CE for the healthcare team. PIM is accredited by COPE to provide CE to optometrists.

Credit Statement: This course is COPE-approved for two hours of CE credit. Activity #128547 and course ID 91657-TD. Check with your local state licensing board to see if this counts toward your CE requirement for relicensure.

Disclosure of Unlabeled Use: This educational activity may contain discussion of published and/or investigational uses of agents that are not indicated by the FDA. The planners of this activity do not recommend the use of any agent outside of the labeled indications. The opinions expressed in the educational activity are those of the faculty and do not necessarily represent the views of the planners. Refer to the official prescribing information for each product for discussion of approved indications, contraindications and warnings.

Disclaimer: Participants have an implied responsibility to use the newly acquired information to enhance patient outcomes and their own professional development. The information presented in this activity is not meant to serve as a guideline for patient management. Any procedures, medications or other courses of diagnosis or treatment discussed or suggested in this activity should not be used by clinicians without evaluation of their patient’s condition(s) and possible contraindications and/or dangers in use, review of any applicable manufacturer’s product information and comparison with recommendations of other authorities.



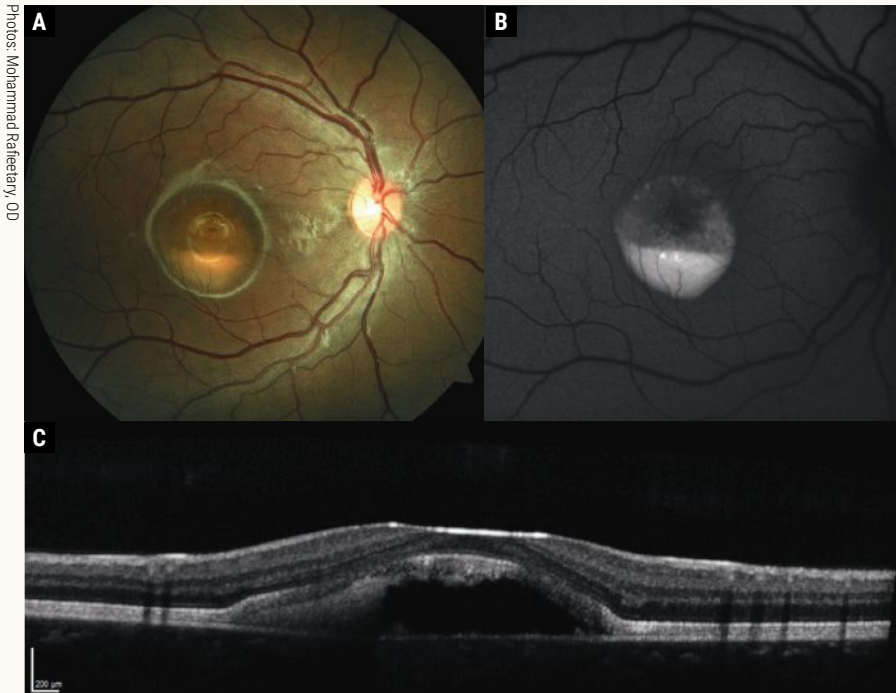


Fig. 2. Multimodal imaging of Best's disease with subfoveal vitelliform lesion in the "pseudohypopyon" stage. Color fundus photography (A) shows yellow subretinal material gravitating inferiorly, resembling a hypopyon. Fundus autofluorescence (B) reveals hyperautofluorescence of the vitelliform material. OCT (C) demonstrates hyperreflective subretinal material with optically empty space superiorly. Note the overlying photoreceptor outer segments are elongated, similar in appearance to chronic central serous chorioretinopathy.

Additionally, drusen are located below the RPE (with the exception of subretinal drusenoid deposits), while flecks are located above the RPE and may disrupt the EZ. Lastly, on FAF drusen are most commonly iso-autofluorescent due to their location below the RPE, while the flecks in STGD1 are strongly hyper-autofluorescent and located above the RPE.

Genetic testing is critical for these patients from the standpoints of patient counseling, predicting disease severity, genetic counseling and identifying eligibility for future gene therapies or clinical trials.

Best's Disease

This autosomal dominantly inherited macular disorder is caused by a mutation in the *BEST1* gene (chromosome 11). *BEST1* codes for the bestrophin protein, a calcium-gated chloride cotransporter located at the basolateral membrane of RPE cells.⁷ Currently, there have been over 100 disease caus-

ing variants reported in the *BEST1* gene. The condition has an estimated prevalence of one in 5,500 in the US, with a bimodal distribution of onset first before puberty and then after puberty.^{8,9}

Five stages of the disease have been defined.^{7,8,10} In stage 1, the pre-vitelliform phase, the macula has an unremarkable appearance with a reduced Arden ratio (<1.55) on an electrooculogram (EOG). Stage 2 is termed the vitelliform stage, in which there is a one- to two-disc diameter accumulation of yellow subretinal material, resembling an egg yolk.

Stage 3 is the pseudohypopyon stage, where the subretinal material gravitates inferiorly, creating the appearance of a hypopyon in the macula (Figure 2). Stage 4 is the vitelliruptive stage, with variable reabsorption of the vitelliform material creating a "scrambled egg" appearance. Stage 5 represents advanced disease with macular atrophy, subretinal fibrosis or choroidal neovascularization.

The prevalence of macular neovascularization (MNV) is estimated to be about 5.7%.¹⁰

On clinical examination, fundus findings vary depending on the disease stage. Multimodal imaging is useful in describing the clinical course of Best's disease. OCT findings vary depending on the stage of disease. In the vitelliform phase, the vitelliform lesion appears on OCT as the accumulation of hyper-reflective material on the apical surface of the RPE in the subretinal space. As the vitelliform lesion gravitates inferiorly, there may be an optically empty, hyporeflective space superiorly with hyperreflective material inferiorly. As the vitelliform lesion is absorbed, OCT shows heterogenous hyper-reflective subretinal material with hyper-reflective clumps that may migrate into the inner retinal layers.

After absorption of the vitelliform material, OCT shows thinning of the ONL and atrophy of EZ and RPE that appear on OCT as hyperreflective columns of light that penetrate to the choroid. In some cases, after the vitelliform material has been reabsorbed, a localized serous detachment remains with an appearance similar to chronic central serous chorioretinopathy (CSCR), with heterogenous yellow subretinal clumps at the border of the serous detachment.⁷

FAF findings include variable hyperautofluorescence which correlates with the presence of subretinal vitelliform material and the abnormal accumulation of lipofuscin within RPE cells. In advanced disease, RPE atrophy appears on FAF as hypo-autofluorescent macular lesions. IVFA demonstrates variable early and late hyperfluorescence, which may confound its use in diagnosing leakage due to choroidal neovascularization. OCT-A may be helpful to visualize new vessel growth.

Genetic testing can be a valuable tool for the identification of patients with Best's disease, especially in the early stages. Although there are no currently available therapies for this condition—aside from treatment with anti-VEGF in cases with choroidal

neovascularization—genetic testing allows for the identification of patients for gene therapies or clinical trials.

Pattern Dystrophy

The term “pattern dystrophy” is used to describe a non-specific group of degenerative disorders of the RPE characterized by the deposition of white-yellow material and grayish pigmentary changes at the level of the RPE and photoreceptor outer segments.¹⁰

Five distinct phenotypes have been grouped into the category of “pattern dystrophies,” including butterfly pattern dystrophy, adult-onset vitelliform dystrophy (AOFVD), multifocal pattern dystrophy simulating Stargardt’s disease, fundus pulverulentus and reticular dystrophy of the pigment epithelium.^{10,11} AOFVD is the most common pattern dystrophy.

These disorders have historically been considered autosomal dominantly inherited conditions associated with variations in the PRPH2/RDS gene (chromosome 6) which codes for the peripherin protein expressed in photoreceptor outer segments.¹² Variations in PRPH2 are thought to result in aberrant metabolism of photoreceptor debris and RPE dysfunction.^{10,13} Variations in the BEST1 gene (chromosome 1) have also been implicated in pattern dystrophy. BEST1 codes for a calcium chloride transporter found

on the basolateral membrane of RPE cells and is linked to other macular dystrophies, including Best’s disease. Additionally linked genes include *ABCA4*, *IMPG1* and *CTNNA1*.¹⁰ Although pattern dystrophies are autosomal dominantly inherited, there is low penetrance, meaning many with these genetic variations do not develop disease.

Individuals with pattern dystrophies may remain asymptomatic until the fifth decade, after which the most common symptoms include mild loss of visual acuity and metamorphopsia.¹³ Although many individuals retain good vision, as many as 50% of individuals may experience significant loss of central vision due to outer retinal atrophy or choroidal neovascularization around the seventh decade of life.¹³

Using a combination of imaging modalities, such as OCT, FAF and IVFA, highlights features that help distinguish these conditions from other phenocopies and masqueraders, like AMD, which may become more difficult in advanced disease. Clinically, butterfly pattern dystrophy appears as white-yellow or grayish pigmentary variations with branching arms, resembling a butterfly (*Figure 3*).^{10,14} Multifocal pattern dystrophy simulating Stargardt’s presents as scattered pisciform flecks throughout the posterior pole with or without atrophic macular lesions,

but without the classic “dark choroid” on IVFA associated with Stargardt’s disease.^{10,15}

AOFVD resembles Best’s disease, though it may be differentiated by age of onset (30 to 50 vs. juvenile onset). Findings include bilateral subfoveal vitelliform lesions with or without a centrally hyperpigmented spot. Vitelliform lesions in AOFVD are typically smaller than vitelliform lesions in Best’s disease (one-third disc diameter vs. one to two disc diameters). Additionally, the EOG Arden ratio in AOFVD is normal to slightly subnormal, while the Arden ratio in Best’s disease is markedly subnormal. AOFVD is associated with a better visual prognosis than Best’s disease, as reading vision is typically preserved. Vision in AOFVD may be compromised by the development of foveal atrophy or CNV.

OCT findings include thickened RPE with hyper-reflective deposits at the level of the RPE or subretinal space. Hyper-reflective foci within the outer retinal layers represent pigmentary migration, which appears clinically as focal areas of grayish hyperpigmentation. Drusen, lipofuscin-rich deposits at the level of Bruch’s membrane, are a hallmark of AMD but not a characteristic finding seen in pattern dystrophies.

Characteristic FAF findings include hyper-autofluorescence corresponding to lipofuscin-rich subretinal deposits. In advanced stages of macular atrophy, FAF demonstrates hypo-autofluorescence in the area of RPE atrophy.

Choroideremia

This disease—an X-linked entity linked to *CHM* gene variations—affects around one in 50,000 male individuals.¹⁶ Specifically, the mutation alters Rab escort protein 1

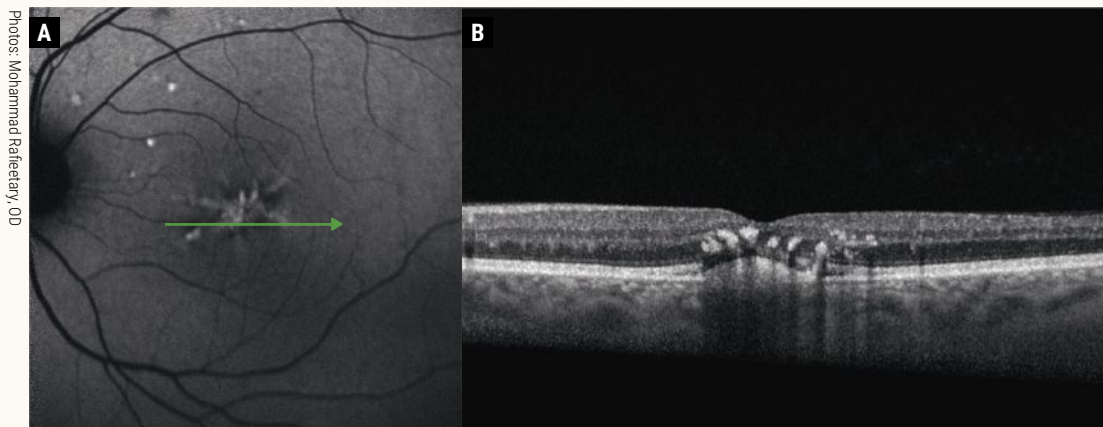


Fig. 3. FAF of butterfly pattern dystrophy (A). Note the hyper-autofluorescent signal in a branching pattern corresponding with subretinal hyper-reflective deposits and accumulation of lipofuscin within RPE cells. OCT (B) demonstrates a subfoveal hyper-reflective subretinal deposit with overlying hyper-reflective foci, representing pigmentary migration. Clinically, these hyperreflective foci create the grayish pigmentation associated with pattern dystrophies.

Photos: Mohammad Rafeeqy, OD

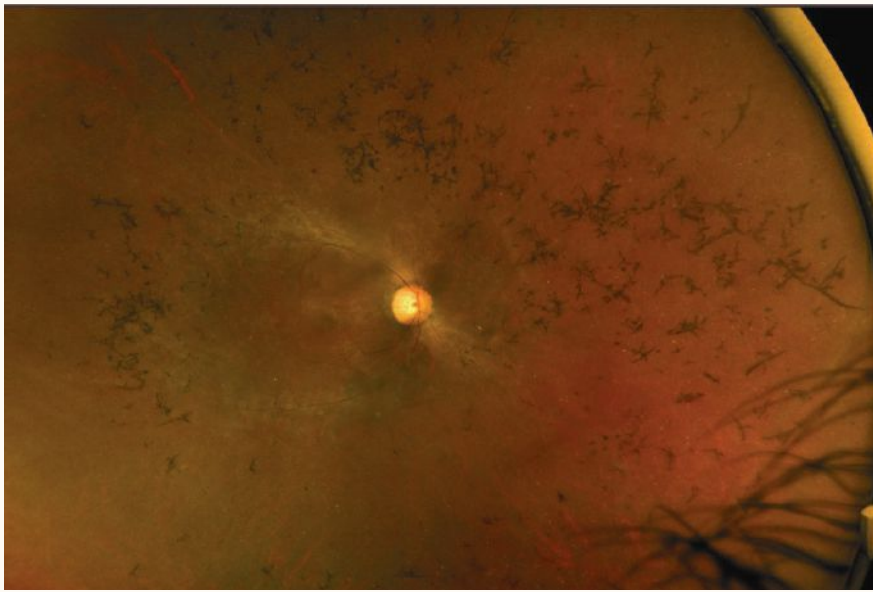


Fig. 4. Fundus photograph of an RP patient with mild disc pallor, attenuated arteries, pigmentary changes and bone spicules.

(REP1), which then manifests as retinal and choroidal atrophy.¹⁷ Starting with nyctalopia in the second decade, choroideremia progresses to visual field constriction, with central vision loss occurring decades later.¹⁸ Peripheral vision loss leads to a legal blindness diagnosis in the fourth or fifth decade, though some may retain decent central acuity.^{16,17} Female carriers, however, present differently with minimal visual symptoms and clinical findings of patchy chorioretinal degeneration.¹⁹

Early in the disease, peripheral pigmentary changes precede areas of chorioretinal atrophy. These appear as patches of hypoautofluorescence that progress in size and later invade the posterior pole.²⁰ Visual acuity decline coincides with central macular thinning. OCT characteristics include decreased RPE reflectance, ellipsoid zone and external limiting membrane alterations, and outer retinal tubules.²⁰ Inner-layer microcysts signal a negative prognosis and occur in about 20% of cases.²⁰

Choroideremia is incurable, and management options remain supportive in nature or include a referral for low vision services. The adeno-associated virus serotype 2 (AAV2) vector-based gene therapy timrepigene

emparvovec—which restores REP1 expression—failed to meet its primary endpoint, though the researchers noted some improvements.²¹ The retina is ideal for gene therapies due to its post-mitotic status, immune privilege and low dosing.²¹

Besides offering genetic testing, clinicians stumble when educating choroideremia patients since disease progression from nyctalopia and visual field constriction to eventual vision loss varies widely. The 20-month NIGHT study tackled this question and aimed to provide insight into choroideremia's natural history. Unlike previous studies that only assessed central acuity, these researchers added functional and anatomical outcomes to see which ones might highlight disease progression. In early disease, BCVA lacked the sensitivity of other measures such as retinal sensitivity, central ellipsoid zone area and total area of FAF.²²

Central Areolar Choroidal Dystrophy

This predominately autosomal dominant condition affects the macula and leads to well-demarcated outer retinal, RPE and choroidal atrophy.^{23,24} In doing so, it acts as a masquerader to geographic atrophy caused by AMD.

The difference, however, lies in the symmetrical appearance, lack of drusen and earlier onset (second to fourth decades).²³ There is a late-onset variety that appears in the sixth to eighth decades that can confound diagnosis.²³ Peripherin/RDS (*PRPH2*) gene mutation is the most common cause, but it has also been linked to *GUC1A1*, *GUCY2D*, *CDHR1*, *ABCA4* and *TTL5*.²⁵

This type of dystrophy is a progressive disorder with four recognized stages. Focal parafoveal pigment changes mark stage 1, which later develops into an oval shaped area of macular atrophy in stage 2.²³ Well-demarcated RPE atrophy with subsequent foveal atrophy represent stages 3 and 4, respectively.²⁵ Visual acuity generally declines in the later stages.

Electroretinogram (ERG) and EOG help distinguish this from other macular pathologies, as they are both normal in most cases.²⁴ FAF may reveal speckled hyper- and hypo-autofluorescence in the early stages, with atrophic areas appearing as solely hypo-autofluorescent areas in the late stages. OCT depicts EZ disruption early in the disease, with subsequent RPE and choroidal atrophy later in the process. No treatment exists for the condition.

Leber's Congenital Amaurosis (LCA)

While this condition accounts for just 5% of all IRDs, LCA is the most severe with the earliest onset, presenting in infancy.²⁶ A less devastating form—early-onset severe retinal degeneration (EOSRD)—presents after infancy and before age five.²⁶ Variants in at least 25 genes cause the vastly autosomal recessive condition, which can occur alone or as part of a syndrome (Senior-Loken or Joubert).²⁷ The most commonly identified genes are *GUCY2D*, *CEP290*, *CRB1*, *RDH12* and *RPE65*.²⁸

Besides severe visual impairment, LCA patients exhibit nystagmus, poor pupil responses and a mostly undetectable full-field ERG.²⁸ Patients are often highly hyperopic. A common occurrence is the oculodigital sign or eye rubbing, which may be an attempt to

stimulate a visual signal. Interestingly, keratoconus often accompanies LCA, though it may be due to other genetic factors vs. oculodigital interactions.²⁹

Clinically, the fundus may appear unremarkable or show signs of RPE mottling. Later presentations vary and include nummular or bone spicule pigmentation, salt and pepper retinopathy, vessel attenuation, macular atrophy and optic disc pallor.²⁷ Almost 90% of RPE65 mutations showed an absent or severely diminished FAF.³⁰

Management is targeted at symptoms. The rate of vision loss varies, with faster progression noted in some genes.³¹ Some LCA patients may exhibit speech, social skill and behavioral problems, necessitating a multidisciplinary approach in their care.³¹ A treatment option does exist, however, only for those inflicted with a biallelic RPE65 variant.

In 2017, the FDA approved Luxturna as the first, and still only, retinal gene therapy. The costly, one-time subretinal injection of voretigene neparovec-rzyl contains a healthy copy of the gene. The RPE65 mutation accounts for only 5% to 10% of LCA cases as well as 2% of RP cases, highlighting the importance of genetic testing in individuals with these conditions.²⁷

Retinitis Pigmentosa

The most common inherited retinal disease, RP is a heterogeneous group of IRDs characterized by progressive loss of rod and cone photoreceptors, leading to visual impairment. It has a variable prevalence globally, affecting around one in 4,000 in the US and one in 5,000 individuals worldwide.³²

RP is primarily caused by genetic variants affecting photoreceptors or RPE cells.³³ More than 100 genetic loci on at least 40 different genes have been identified in patterns of inheritance and expression for RP, and it is likely that more have yet to be discovered.^{34,35} The pattern of inheritance of these genes can be autosomal dominant (AD), autosomal recessive (AR), X-linked recessive or dominant

(affected X chromosome on both parents sides), as well as genetic mutation. In some cases, the mode of inheritance remains unknown.³⁶

Common symptoms include progressive vision loss, night blindness or nyctalopia, an enlarged blind spot leading to peripheral vision loss and eventual central vision loss, posing challenges for tasks like reading, driving or facial recognition.³⁷ The symptoms of RP can vary greatly in terms of onset, severity and progression, even among family members affected by the condition, due to variable genotypic penetrance. Epigenetic factors and potentially environmental influences are thought to play a role in this variability, making it difficult to establish genotype-phenotype correlations.³⁸

The classic clinical signs of RP observed during fundus examinations include a pale optic disc, retinal vessel attenuation and “bone-spicule” hyperpigmentation (*Figures 4 and 5*). These retinal changes typically occur bilaterally and exhibit a high degree of symmetry. Other fundus findings

include posterior capsular cataracts, optic nerve drusen, cystoid macular edema (CME) and inner retina cystic atrophy, epiretinal membrane formation and Coats-like disease—a mid-peripheral exudative vasculopathy characterized by telangiectatic vessels, focal serous retinal detachment and lipid exudate deposition.^{39,41} The onset and presentation of these findings vary widely among individuals and may even appear in atypical forms such as a unilateral or sectoral RP presentation.⁴⁰

Retinitis pigmentosa can be categorized into non-syndromic (70% to 80% of cases) and syndromic (20% to 30% of cases) forms based on the presence of systemic abnormalities and other associated diseases. Non-syndromic RP has no systemic abnormalities, whereas syndromic RP is accompanied by non-ocular syndromes and systemic disease.³⁷

Usher syndrome, a syndromic form of RP, encompasses a group of genetic disorders classified into three subtypes: Usher syndrome type I (USH1), type II (USH2) and type III (USH3). These

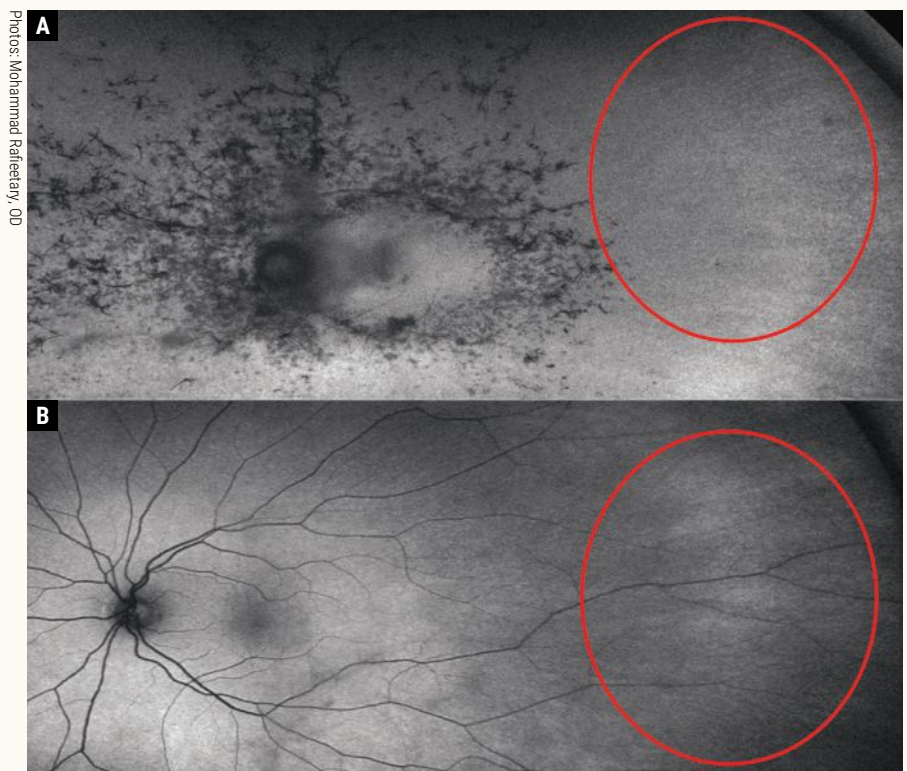


Fig. 5. Typical RP FAF presentation (A). In the red circles, note the attenuation and absence of retinal arteries vs. that of an RP carrier (B).

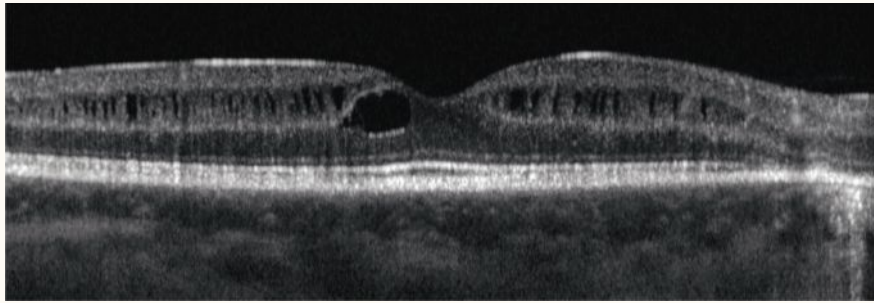


Photo: Mohammad Raftaery, OD

Fig. 6. Intraretinal cystoid spaces have been described in patients with Usher syndrome. This is more commonly seen in USH2.

are based on specific characteristics, such as the presence of vestibular involvement, the age of RP onset and the rate of disease progression. Numerous genes are implicated in this syndrome, contributing to its genetic heterogeneity.

Usher syndrome affects up to one in 6,000 individuals and is the leading cause of deafblindness in humans. Symptoms typically manifest from birth (in USH1 and USH2) or later in mid-childhood or adulthood (USH3). Common symptoms include congenital hearing loss, loss of night vision as the initial visual symptom and the development of blind spots leading to progressive peripheral vision loss.

A diagnosis of USH1 is considered when a patient presents with congenital profound bilateral sensorineural hearing loss, often accompanied by severe vestibular abnormalities that may not be clinically obvious. Early-onset RP, which progresses slowly, is another hallmark feature. Affected individuals typically exhibit abnormal speech development and vestibular areflexia, characterized by a lack of normal vestibular reflexes, a defining trait of USH1. Consequently, children with USH1 often experience delayed walking compared to their peers due to vestibular impairment. Balance issues may persist into adulthood, while the remainder of the physical examination typically appears normal.

USH2 is characterized by congenital bilateral sensorineural hearing loss that primarily affects higher frequencies, along with intact vestibular function. Unlike USH1, RP onset in USH2 typically occurs during adolescence or

adulthood. This subtype represents the most common form of Usher syndrome, accounting for 75% to 80% of diagnosed cases.

USH3 is distinguished by post-lingual progressive sensorineural hearing loss, meaning the hearing loss develops after speech has been acquired and worsens over time. RP onset in USH3 typically occurs later compared to other types of Usher syndrome. Vestibular function can vary in USH3, with affected individuals experiencing impairment in various degrees. In USH2 and USH3, the progression of RP is more noticeable, likely due to its later onset compared to USH1.

In addition to the typical features of Usher syndrome, there are some uncommon ocular manifestations associated with this condition. Intraretinal cystoid spaces have been observed, particularly in individuals with USH2 (Figure 6). Additionally, rare instances of bilateral Coats-like exudative retinopathy have been reported in Usher syndrome, indicating abnormal blood vessel growth and leakage in the retina resembling Coats disease.

ERG is considered the gold standard for diagnosing RP, establishing baseline function and monitoring disease progression. ERG can detect photoreceptor dysfunction even when changes on a clinical exam or imaging are minimal. While ERG remains the standard of care for diagnosis, FAF can be used instead of ERG to monitor disease progression, particularly in later stages when ERG may be less reliable.

Visual field testing is also valuable for establishing baseline function and monitoring disease progression. In the

early stages of RP, visual field measurements demonstrate variable peripheral vision loss, progressing to a ring scotoma consistent with the tunnel vision described in later disease stages.

OCT can be used to evaluate retinal morphological changes in RP patients. In the early stages of the disease, OCT can reveal disorganization of the outer retinal layers. As RP progresses, there is a noticeable decrease in the thickness of the outer nuclear layer. In the advanced stages of RP, complete loss of both the outer segment and the outer nuclear layer occurs, while the inner retinal layers remain relatively well preserved.⁴¹

Cone-Rod Dystrophy

This condition is another IRD that typically manifests in childhood and progresses over time, affecting approximately one in 30,000 individuals. It is frequently mistaken for RP but differs by predominantly affecting cones over rods. At least 10 genes have been found associated with cone-rod dystrophy, which is usually passed on in an AD pattern. The mutation in the *GUCY2D* and *CRX* genes account for 50% of cases.

Patients initially experience vision loss and color vision abnormalities, followed by peripheral field constriction. Fundus examination in the early stages shows macular pigmentation and atrophy, progressing to peripheral bone spicule pigmentation in advanced cases, often affecting the mid-periphery later in the disease.

Common symptoms include decreased visual acuity, light sensitivity, difficulty recognizing colors, blind spots in the visual field and a gradual loss of peripheral vision leading to blindness by mid-adulthood. Diagnosis of cone-rod dystrophy relies on ERG changes, indicating more severe cone impairment compared to rods.⁴²

Takeaways

The value of clinical examination and ancillary testing should remain paramount when evaluating IRDs. The American Academy of Ophthalmology

recommends that the clinical evaluation of suspected IRDs should involve a comprehensive examination combined with imaging, including color fundus photos, FAF, OCT, visual field testing, full-field ERG and genetic testing.¹

Diagnosing inherited retinal diseases can be challenging due to overlapping symptoms. Therefore, genetic testing is an essential tool to identify the underlying genetic cause of vision loss or impairment. In cases of suspicion for IRD, genetic testing should be pursued with the caveat that current testing platforms are only 60% to 70% successful in identifying the causative gene. Patients who undergo genetic testing should then be referred for genetic counseling.⁴¹

When considering genetic testing, note that several groups offer it at no cost. Clinicians should be familiar with the process and the paperwork. The Foundation Fighting Blindness partners with Blueprint Genetics to make available the My Retina Tracker panel, while Invitae has the sponsored Inherited Retinal Disorders Panel, although it was recently purchased by LabCorp, so stay tuned for any future changes. Most importantly, both provide genetic counseling to help interpret the results and discuss how they affect the patient now and in the future.

Patients should sign up for the My Retina Tracker Registry—a research database of the Foundation Fighting Blindness. The registry is designed to share information about rare retinal diseases, including IRDs, to identify individuals who might be interested in participating in research studies and clinical trials.

Finally, consider a low vision consult, even if the patient is asymptomatic, as these specialists would welcome the chance to introduce themselves and begin early conversations. ■

1. Duncan JL, Branham K, Birch DG, et al. Guidelines on clinical assessment of patients with inherited retinal degenerations – 2022. American Academy of Ophthalmology. www.aao.org/education/clinical-state-ment/guidelines-on-clinical-assessment-of-patients-with. October 2022. Accessed April 15, 2024.

2. Al-Khuzaei S, Broadgate S, Foster CR, et al. An overview of the genetics of ABCA4 retinopathies, an evolving story. *Genes (Basel)*. 2021;12(8):1241.
3. Tanna P, Strauss RW, Fujinami K, Michaelides M. Stargardt disease: clinical features, molecular genetics, animal models and therapeutic options. *Br J Ophthalmol*. 2017;101(1):25-30.
4. Li CHZ, Pas JAAH, Corradi Z, et al. Study of late-onset Stargardt type 1 disease: Characteristics, genetics and progression. *Ophthalmology*. 2024;131(1):87-97.
5. Lambertus S, van Huet RA, Bax NM, et al. Early-onset Stargardt disease: phenotypic and genotypic characteristics. *Ophthalmology*. 2015;122(2):335-44.
6. Heath Jeffery RC, Chen FK. Stargardt disease: Multimodal imaging: a review. *Clin Exp Ophthalmol*. 2021;49(5):498-515.
7. Spaide RF, Noble K, Morgan A, Freund KB. Vitelliform macular dystrophy. *Ophthalmology*. 2006;113(8):1392-1400.
8. Dalvin LA, Pulido JS, Marmorstein AD. Vitelliform dystrophies: prevalence in Olmsted County, Minnesota, United States. *Ophthalmic Genet*. 2017;38(2):143-7.
9. Querques G, Zerbib J, Santacroce R, et al. Functional and clinical data of Best vitelliform macular dystrophy patients with mutations in the *BEST1* gene. *Mol Vis*. 2009;15:2960-72.
10. Hanif AM, Yan J, Jain N. Pattern dystrophy: an imprecise diagnosis in the age of precision medicine. *Int Ophthalmol Clin*. 2019;59(1):173-94.
11. Gass JDM. Stereoscopic atlas of macular diseases: Diagnosis and treatment. Mosby. 1997.
12. Conley SM, Naash MI. Gene therapy for PRPH2-associated ocular disease: challenges and prospects. *Cold Spring Harb Perspect Med*. 2014;4(11):a017376.
13. Sodi A, Mucciolo DP, Giorgio D, et al. Clinical and molecular findings in patients with pattern dystrophy. *Ophthalmic Genet*. 2021;42(5):577-87.
14. Kumar V, Kumawat D. Multimodal imaging in a case of butterfly pattern dystrophy of retinal pigment epithelium. *Int Ophthalmol*. 2018;38(2):775-9.
15. Rotsos T, Gkounta A, Symeonidis C, et al. Multifocal pattern dystrophy simulating fundus flavimaculatus: Multimodal imaging for early diagnosis. *Case Rep Ophthalmol*. 2021;12(2):724-8.
16. Khan K, Islam F, Moore A, et al. Clinical and genetic features of choroideremia in childhood. *Ophthalmology*. 2016;123(10):2158-65.
17. Jauregui R, Park K, Tanaka A, et al. Spectrum of disease severity and phenotype in choroideremia carriers. *Am J Ophthalmol*. 2019;207:77-86.
18. Aleman T, Han G, Serrano L, et al. Natural history of the central structural abnormalities in choroideremia: a prospective cross-sectional study. *Ophthalmology*. 2017;124(3):359-73.
19. MacDonald IM, Russell L, Chan C. Choroideremia: new findings from ocular pathology and review of recent literature. *Surv Ophthalmol*. 2009;54(3):401-7.
20. Brambati M, Borrelli E, Sacconi R, et al. Choroideremia: update on clinical features and emerging treatments. *Clin Ophthalmol*. 2019;13:2225-31.
21. MacLaren R, Fischer M, Gow J, et al. Subretinal timrepigene eparvecic in adult men with choroideremia: a randomized Phase III trial. *Nat Med*. 2023;29(10):2464-72.
22. MacLaren R, Lam B, Fischer D, et al. A prospective, observational, non-interventional clinical study of participants with choroideremia: The NIGHT study. *Am J Ophthalmol*. 2024;263:35-49.
23. Paez-Escamilla M, Jhingan M, Gallagher D, et al. Age-related macular degeneration masqueraders: from the obvious to the obscure. *Surv Ophthalmol*. 2021;66(2):153-82.
24. Camargo J, Prezja G, Shiokawa N, et al. New insights on the regulatory gene network disturbed in central areolar choroidal dystrophy – beyond classical gene candidates. *Front Genet*. 2022;13:886461.
25. Smailhodzic D, Fleckenstein M, Theelan T, et al. Central areolar choroidal dystrophy (CACD) and age-related macular degeneration (AMD): differentiating characteristic in multimodal imaging. *Invest Ophthalmol Vis Sci*. 2011;52(12):8908-18.
26. Kondkar A, Abu-Amero K. Leber congenital amaurosis: Current genetic basis, scope for genetic testing and personalized medicine. *Exp Eye Res*. 2019;189:107834.
27. Varela M, Guimaraes T, Georgiou M, Michaelides M. Leber congenital amaurosis/early-onset severe retinal dystrophy: Current management and clinical trials. *Br J Ophthalmol*. 2022;106(4):445-51.
28. Kumaran N, Moore A, Weleber R, Michaelides M. Leber congenital amaurosis/early-onset severe retinal dystrophy: Clinical features, molecular genetics and therapeutic interventions. *Br J Ophthalmol*. 2017;101(9):1147-54.
29. Elder MJ. Leber congenital amaurosis and its association with keratoconus and keratoglobus. *J Pediatr Ophthalmol Strabismus*. 1994;31(1):38-40.
30. Chung D, Bertelsen M, Lorenz B, et al. The natural history of inherited retinal dystrophy due to biallelic mutations in the *RPE65* gene. *Am J Ophthalmol*. 2019;199:58-70.
31. Georgiou M, Fujinami K, Michaelides M. Inherited retinal diseases: Therapeutics, clinical trials and end points – a review. *Clin Experiment Ophthalmol*. 2021;49(3):270-88.
32. O'Neal TB, Luterer EE. Retinitis pigmentosa. In: StatPearls [Internet]. Treasure Island (FL): StatPearls Publishing. www.ncbi.nlm.nih.gov/books/NBK519518. Updated February 19, 2023. Accessed April 15, 2024.
33. Yang YJ, Peng J, Ying D, Peng QH. A brief review on the pathological role of decreased blood flow affected in retinitis pigmentosa. *J Ophthalmol*. 2018;2018:3249064.
34. Berson EL. Retinitis pigmentosa and allied diseases. In: Albert D, Miller J, Azar D, Blodi B, eds. *Albert and Jakobiec's Principles and Practice of Ophthalmology*, 3rd ed. Philadelphia, PA: Elsevier; 2008.
35. Ferrari S, Di Iorio E, Barbaro V, et al. Retinitis pigmentosa: genes and disease mechanisms. *Curr Genomics*. 2011;12(4):238-49.
36. Bravo-Gil N, González-Del Pozo M, Martín-Sánchez M, et al. Unravelling the genetic basis of simplex retinitis pigmentosa cases. *Sci Rep*. 2017;7:41937.
37. Cross N, van Steen C, Zegaoui Y, et al. Retinitis pigmentosa: Burden of disease and current unmet needs. *Clin Ophthalmol*. 2022;16:1993-2010.
38. Dvorianchikova G, Lypka KR, Ivanov D. The potential role of epigenetic mechanisms in the development of retinitis pigmentosa and related photoreceptor dystrophies. *Front Genet*. 2022;13:827274.
39. Ruff A, Tezel A, Tezel TH. Anatomical and functional correlates of cystic macular edema in retinitis pigmentosa. *PLoS One*. 2022;17(10):e0276629.
40. Verbakel SK, van Huet RAC, Boon CJF, et al. Non-syndromic retinitis pigmentosa. *Prog Retin Eye Res*. 2018;66:157-86.
41. Nguyen XT, Moekotte L, Plom AS, et al. Retinitis pigmentosa: Current clinical management and emerging therapies. *Int J Mol Sci*. 2023;24(8):7481.
42. Chawla H, Vohra V. Retinal dystrophies. In: StatPearls [Internet]. Treasure Island (FL): StatPearls Publishing. www.ncbi.nlm.nih.gov/books/NBK564379. Updated March 16, 2023. Accessed April 15, 2024.

OPTOMETRIC STUDY CENTER QUIZ

To obtain CE credit through the Optometric Study Center, complete the test form on the following page and return it with the \$35 fee to: Jobson Healthcare Information, Attn.: CE Processing, Jobson Healthcare Information, LLC/WebMD, 283-299 Market Street, 2 Gateway Center, 4th Floor, Newark, NJ 07102. To be eligible, please return the card within three years of publication. You can also access the test form and submit your answers and payment via credit card online at revieweducationgroup.com. You must achieve a score of 70 or higher to receive credit. Allow four weeks for processing. For each Optometric Study Center course you pass, you earn two hours of credit. Please check with your state licensing board to see if this approval counts toward your CE requirement for relicensure.

1. Classic findings in Stargardt's disease include all of the following EXCEPT:
 - a. Beaten-bronze fundus.
 - b. Pisciform whitish flecks.
 - c. Drusen.
 - d. Atrophic macular lesions.
2. Stargardt's disease has which of the following inheritance patterns?
 - a. Autosomal recessive.
 - b. Autosomal dominant.
 - c. X-linked recessive.
 - d. None of the above.
3. The most common inherited juvenile retinal dystrophy is which of the following?
 - a. Best's disease.
 - b. Stargardt's disease.
 - c. Choroideremia.
 - d. Butterfly pattern dystrophy.
4. Which of the following correctly orders the five stages of Best's disease?
 - a. Pre-vitelliform, atrophic, vitelliform, pseudohypopyon, vitelliruptive.
 - b. Pre-vitelliform, vitelliform, vitelliruptive, pseudohypopyon, atrophic.
 - c. Pre-vitelliform, pseudohypopyon, vitelliform, vitelliruptive, atrophic.
 - d. Pre-vitelliform, vitelliform, pseudohypopyon, vitelliruptive, atrophic.
5. The prevalence of MNV in Best's disease is estimated to be _____.
 - a. 35.4%.
 - b. 10.6%.
 - c. 5.7%.
 - d. 0.1%.
6. Which of the following is NOT considered a pattern dystrophy?
 - a. Butterfly dystrophy.
 - b. Adult-onset vitelliform dystrophy.
 - c. Reticular dystrophy of the retinal pigment epithelium.
 - d. Retinitis pigmentosa.
7. Pattern dystrophies are thought to have which of the following inheritance patterns?
 - a. Autosomal dominant.
 - b. Autosomal recessive.
 - c. X-linked recessive.
 - d. None of the above.
8. Choroideremia progresses from _____.
 - a. Photophobia to phonophobia to vision loss.
 - b. Nyctalopia to visual field constriction to central vision loss.
 - c. Decreased accommodation to vision loss to visual field constriction.
 - d. Decreased central vision to strabismus to nyctalopia.
9. Management of choroideremia includes all of the following EXCEPT:
 - a. Low vision referral.
 - b. Genetic testing.
 - c. Genetic counseling.
 - d. Subretinal injection of timrepigene emparvovec.
10. When compared to AMD, central areolar choroidal dystrophy has _____.
 - a. The presence of drusen.
 - b. An asymmetrical appearance.
 - c. An earlier onset.
 - d. A later onset.
11. Which of the following IRDs is the most severe and the earliest onset?
 - a. Leber congenital amaurosis.
 - b. Central areolar choroidal dystrophy.
 - c. Stargardt's disease.
 - d. Pattern dystrophy.
12. Which of the following is NOT a characteristic of Leber congenital amaurosis?
 - a. Nystagmus.
 - b. Normal pupil responses.
 - c. Oculodigital sign.
 - d. Keratoconus.
13. A Leber congenital amaurosis treatment exists for which gene mutation?
 - a. CRB1.
 - b. GUCY2D.
 - c. CEP290.
 - d. RPE65.
14. Which of the following is the most common Inherited Retinal Dystrophy?
 - a. Usher syndrome.
 - b. Retinitis pigmentosa.
 - c. Cone-rod dystrophy.
 - d. Leber's congenital amaurosis.
15. Which of the following is a classic clinical sign observed during fundus examinations in patients with retinitis pigmentosa (RP)?
 - a. Optic nerve swelling.
 - b. Macular hole.
 - c. Retinal vessel attenuation.
 - d. Corneal opacity.
16. What is the primary difference between non-syndromic RP and syndromic RP?
 - a. Non-syndromic RP is associated with systemic abnormalities.
 - b. Syndromic RP has a lower prevalence than non-syndromic RP.
 - c. Syndromic RP is accompanied by non-ocular syndromes and systemic disease.
 - d. Non-syndromic RP affects primarily the cones rather than rods.
17. What is the most common cause of deaf-blindness?
 - a. Usher syndrome.
 - b. Retinitis pigmentosa.
 - c. Cone-rod dystrophy.
 - d. Leber's congenital amaurosis.
18. Which diagnostic test is considered the gold standard for diagnosing retinitis pigmentosa, establishing baseline function, and monitoring disease progression?
 - a. Fundus autofluorescence (FAF).
 - b. Visual field testing.
 - c. Optical coherence tomography (OCT).
 - d. Full-field electroretinography (ERG).
19. What distinguishes cone-rod dystrophy (CRD) from retinitis pigmentosa (RP)?
 - a. CRD predominantly affects rods over cones.
 - b. CRD primarily presents with night blindness and peripheral vision loss.
 - c. CRD exhibits more severe cone impairment compared to rods.
 - d. CRD is characterized by optic nerve pallor on fundus examination.
20. What is the primary role of genetic testing in the diagnosis of inherited retinal disorders?
 - a. To establish baseline visual acuity.
 - b. To confirm the presence of optic nerve abnormalities.
 - c. To identify the underlying genetic cause.
 - d. To assess vestibular function.

Examination Answer Sheet

Are You Up to Speed on Inherited Retinal Dystrophies?

Valid for credit through June 15, 2027

Online: This exam can be taken online at revieweducationgroup.com. Upon passing the exam, you can view your results immediately and download a real-time CE certificate. You can also view your test history at any time from the website.

Directions: Select one answer for each question in the exam and completely darken the appropriate circle. A minimum score of 70% is required to earn credit.

Mail to: Jobson Healthcare Information, LLC/WebMD, 283-299 Market Street, 2 Gateway Center, 4th Floor, Newark, NJ 07102.

Payment: Remit \$35 with this exam. Make check payable to Jobson Healthcare Information, LLC.

Credit: This course is COPE-approved for two hours of CE credit. Course ID 91657-TD.

Processing: There is a four-week processing time for this exam.

Jointly provided by PIM and the Review Education Group.

Answers to CE exam:

- 1. A B C D
- 2. A B C D
- 3. A B C D
- 4. A B C D
- 5. A B C D
- 6. A B C D
- 7. A B C D
- 8. A B C D
- 9. A B C D
- 10. A B C D
- 11. A B C D
- 12. A B C D
- 13. A B C D
- 14. A B C D
- 15. A B C D
- 16. A B C D
- 17. A B C D
- 18. A B C D
- 19. A B C D
- 20. A B C D

Post-activity evaluation questions:

Rate how well the activity supported your achievement of these learning objectives. 1=Poor, 2=Fair, 3=Neutral, 4=Good, 5=Excellent

- 21. Recognize the presentations of various inherited retinal dystrophies. ① ② ③ ④ ⑤
- 22. Effectively diagnose inherited retinal dystrophies in clinical practice. ① ② ③ ④ ⑤
- 23. Recognize the value and limitations of genetic testing for these patients. ① ② ③ ④ ⑤
- 24. Determine which IRD patients could benefit from genetic testing. ① ② ③ ④ ⑤
- 25. Based upon your participation in this activity, do you intend to change your practice behavior? (Choose only one of the following options.)
 - A I do plan to implement changes in my practice based on the information presented.
 - B My current practice has been reinforced by the information presented.
 - C I need more information before I will change my practice.
- 26. Thinking about how your participation in this activity will influence your patient care, how many of your patients are likely to benefit? (please use a number):
- 27. If you plan to change your practice behavior, what type of changes do you plan to implement? (Check all that apply.)
 - A Apply latest guidelines
 - B Change in diagnostic methods
 - C Choice of management approach
 - D Change in current practice for referral
 - E Change in vision correction offerings
 - F Change in differential diagnosis
 - G More active monitoring and counseling
 - H Other, please specify: _____
- 28. How confident are you that you will be able to make your intended changes?
 - A Very confident
 - B Somewhat confident
 - C Unsure
 - D Not confident
- 29. Which of the following do you anticipate will be the primary barrier to implementing these changes?
 - A Formulary restrictions
 - B Time constraints
 - C System constraints
 - D Insurance/financial issues
 - E Lack of interprofessional team support
 - F Treatment related adverse events
 - G Patient adherence/compliance
 - H Other, please specify: _____
- 30. Additional comments on this course: _____

Please retain a copy for your records. Please print clearly.

First Name

Last Name

E-Mail

The following is your: Home Address Business Address

Business Name

Address

City State

ZIP

Telephone # - -

Fax # - -

OE Tracker Number

Rate the quality of the material provided:

1=Strongly disagree, 2=Somewhat disagree, 3=Neutral, 4=Somewhat agree, 5=Strongly agree

31. The content was evidence-based.

① ② ③ ④ ⑤

32. The content was balanced and free of bias.

① ② ③ ④ ⑤

33. The presentation was clear and effective.

① ② ③ ④ ⑤

By submitting this answer sheet, I certify that I have read the lesson in its entirety and completed the self-assessment exam personally based on the material presented. I have not obtained the answers to this exam by any fraudulent or improper means.

Signature

Date

Lesson 124999 RO-OSC-0624



BY JEROME SHERMAN, OD, AND SHERRY BASS, OD

YOU BE THE JUDGE

Vicarious Liability Leads to Blindness

Yes, you may be responsible for the actions of your employees.

A 20-year-old Caucasian male college freshman presented for his first eye exam complaining of blurred vision in his right eye, most noticeable after an hour or so of near work. The patient mentioned to the technician that the blurred vision was a new symptom, but this comment was not entered into the record. The technician recorded the eye health history and general health history as negative. The tech measured unaided visual acuity as 20/25- OD and 20/20 OS. Pinhole VA was not recorded. The refraction performed by the tech was +0.50D sphere OD and plano OS. Near testing revealed an add of +1.00D OU. VA did not improve, and again pinhole VA was not recorded. The tech performed a visual field screener with a Harrington-Flocks Multiple Pattern Screener, which revealed a mild defect in the right eye only.

The ophthalmic clinician later performed an external exam, a biomicroscopy and an undilated fundus exam, all of which were recorded as normal in each eye. The clinician prescribed reading glasses incorporating a +1.50D sphere OD and a +1.00D sphere OS to be worn for extended near work. The clinician arrived at the diagnosis of mild amblyopia OD and recommended a re-evaluation in two months.

About 10 days after wearing the reading glasses for all near work, the

patient returned without an appointment and complained to the receptionist that the reading glasses were not helping at all. It was a busy day in the office, and the receptionist told the college student to wear the glasses for at least two weeks and then call for an appointment if there was still a problem. The patient later reported that the receptionist said, "It's your first pair of glasses; you just have to get used to them."

Frustrated by the blurred vision that the patient thought might be worsening in his right eye, the college student decided to see another eye doctor who was recommended by his girlfriend, who was concerned about his vision. Best-corrected VA was now measured at 20/100 in the right eye and 20/20 in the left.

A dilated fundus exam (DFE) revealed a lesion surrounding the optic disc in the right eye, extending to the macula with possible macula hemorrhaging. The peripheral retina revealed numerous small, punched-out circular scars in both eyes. This clinician arrived at a tentative diagnosis of presumed ocular histoplasmosis syndrome (POHS) and arranged for a retina consult two days later.

You Be the Judge

Considering the facts presented thus far, opine the following questions:

- Was the diagnosis of amblyopia supported on the first visit?
- Without a constant unilateral strabismus and/or significant anisometropia, was amblyopia a plausible diagnosis?
- Was the receptionist justified in her recommendations to the patient?
- Do the doctors in the practice have responsibility for their ancillary personnel in a case such as this?
- Should ancillary personnel be making "professional" decisions?
- Did the doctor really conclude amblyopia was the diagnosis, or was this just for billing purposes?
- Could a dilated exam on the first visit or ultra-widefield imaging have alerted the clinician to the probable diagnosis at an early stage prior to vision loss?

Outcome

The retina specialist confirmed the triad of findings typical of POHS: peripapillary abnormalities, choroidal neovascularization (CNV) in the macula and punched-out circular lesions in the periphery. These histo spots are quite helpful in arriving at a diagnosis and support the need for a DFE and/or ultra-widefield images. This inflammatory condition occurs when the *Histoplasma capsulatum* fungus invades the eye.¹ Unlike toxoplasmosis, vitritis and iritis virtually never occur in histo.

CNV was confirmed with fundus fluorescein angiography, and the patient was treated with an argon laser. One of us (JS) reviewed the case and evaluated the patient after the completion of the argon laser intervention. Best-correctable VA dropped to below 20/400 OS, and ophthalmoscopy and fundus photography revealed a one disc

About Drs.
Sherman
and Bass

Dr. Sherman is a Distinguished Teaching Professor at the SUNY State College of Optometry and editor-in-chief of *Retina Revealed* at www.retinarevealed.com. During his 53 years at SUNY, Dr. Sherman has published about 750 various manuscripts. He has also served as an expert witness in 400 malpractice cases, approximately equally split between plaintiff and defendant. Dr. Sherman has received support for *Retina Revealed* from Carl Zeiss Meditec, MacuHealth and Konan. **Dr. Bass** is a Distinguished Teaching Professor at the SUNY College of Optometry and is an attending in the Retina Clinic of the University Eye Center. She has served as an expert witness in a significant number of malpractice cases, the majority in support of the defendant. She serves as a consultant for ProQR Therapeutics.

diameter pigment lesion, visible sclera, and an irregular ring around the disc. Disc drusen may have been present in the right eye but the VA reduction is due to the macula lesion secondary to the CNV and the laser intervention. Note that this case occurred prior to the widespread availability of spectral-domain OCT, so OCT sections through the macula were unavailable.

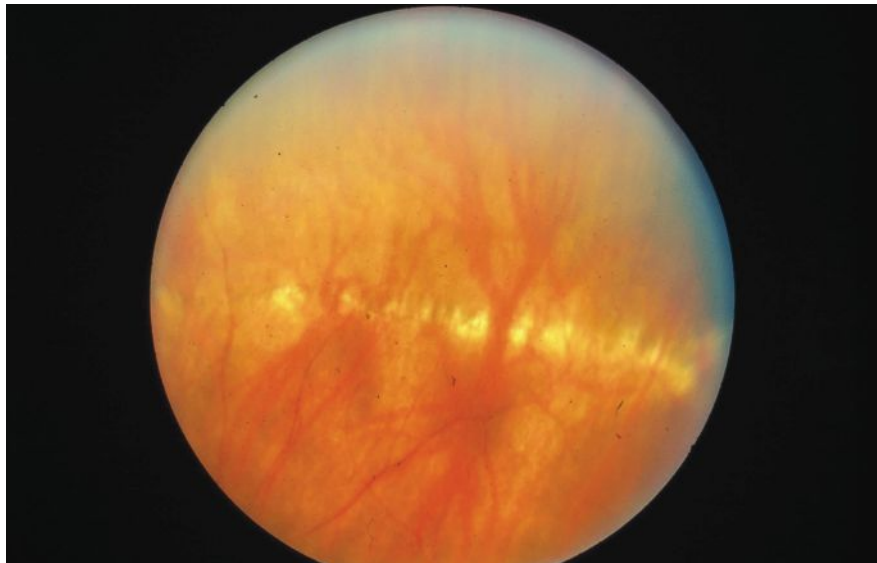
Some patients with POHS have the histo spots but never develop the maculopathy, so the triad of findings is often not complete. If you encounter a patient without symptoms but with histo spots and a ring around the disc but no maculopathy, the patient should be warned about the possible development of vision loss due to an active macular lesion. Such a patient should be followed more carefully and taught how to use an Amsler grid. Clinicians who monitor their age-related macular degeneration AMD patients with the ForeseeHome device (Notal Vision) for the early detection of the conversion of dry to wet AMD may consider this home device, which has proven to be more sensitive to early detection of CNV than the Amsler grid.

The case settled against the first clinician and the practice prior to a jury trial for a reported quarter of a million dollars.

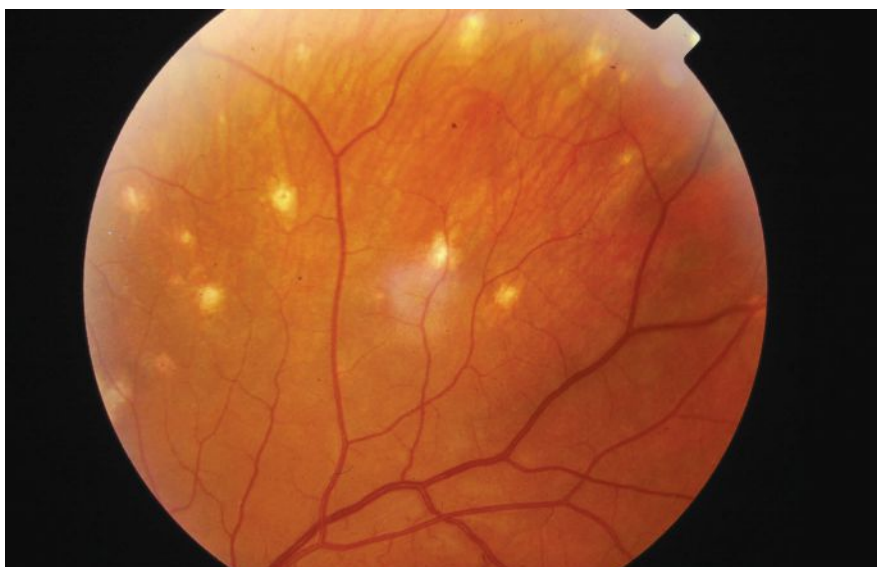Liability Considerations

Vicarious liability, or imputed liability, is a legal rule that holds a person or company responsible for actions committed by others or their employees. Such liability can apply to any business enterprise, including healthcare facilities and hospitals. Rarely does a receptionist or technician get sued, but their supervisors do. In this case, the technician failed to record that the blurred vision was a new symptom. This grave error could be just sloppiness or improper training.

In a previous *You Be the Judge* article (Diagnose Amblyopia with Caution, November 2023), the monocular vision loss in a 13-year-old was rather recent but this information was never recorded.



Linear array of histo spots in the peripheral retina in a different patient.



Scattered histo spots in the mid-periphery of another patient.

The clinician in that case (as in this case) appeared to assume that the vision loss or blurred vision was long-standing. Hence, both clinicians arrived at the erroneous diagnosis of amblyopia. In the case of the 13-year-old patient, blindness OU was the outcome due to a one-year delay of diagnosis and treatment for a chiasmal mass. The jury in that case found the eye clinician culpable and awarded the patient and family over nine million dollars. In addition, make sure your receptionists and technicians are well trained and are not making professional decisions, such as in this

case, “It’s your first pair of glasses, you just have to get used to them.”

A re-evaluation of the college student the day he returned and complained “the glasses are not helping at all” would have, more likely than not, resulted in an earlier diagnosis of POHS, earlier intervention and a better outcome. ■

1. Roth AM. Histoplasma capsulation in the presumed ocular histoplasmosis syndrome. *Am J Ophthalmol.* 1977;83(3):293-8.

2. Macular Photocoagulation Study Group. Argon laser photocoagulation for ocular histoplasmosis. *Arch Ophthalmol.* 1983;101(7):1347-57.

3. Gabel W. Vicarious liability. *J Am Optom Assoc.* 1987;58(7):599-601.



BY JESSICA STEEN, OD

THERAPEUTIC REVIEW

Heartfelt Insight

Be aware of the cardiopulmonary effects of beta blockers.

Topical ophthalmic beta blockers may no longer be first-line agents to lower intraocular pressure (IOP) in individuals with open-angle glaucoma or ocular hypertension, but they still represent a frequently used class of treatment and are often difficult to avoid in fixed-combination therapy, where they play an important role in generic options. Many of the long-held beliefs regarding the safety of topical ophthalmic beta blockers have been developed from case reports, case series or editorial opinion; however, the mechanism of action of beta blockers can infer significant cardiopulmonary effects that have important implications for the management of individuals with ocular hypertension and glaucoma.¹

An individualized evaluation of overall benefit vs. risk prior to their prescription begins with a complete medical history, medication history and clinical assessment, including pulse rate,

to differentiate patients in whom beta blockers may be safely used from those where their use should be avoided.

An 80-year-old male with primary open-angle glaucoma presented for scheduled follow-up without new visual concerns. He was taking latanoprost 0.005% QHS OU and timolol 0.5% BID OU with excellent reported tolerability and adherence. His IOP was within target range with clinical stability since the addition of timolol in 2021. He had a history of atrial fibrillation and hypertension, for which he was under the care of a cardiologist and was medically managed with apixaban and irbesartan long-term, as well as bisoprolol, which had been added since his previous visit. Considering this new addition to his systemic therapy, blood pressure and pulse rate were taken in-office and were measured to be 124/78mm Hg and 48 beats per minute, respectively.

Pulmonary Effects

Perhaps the clearest systemic contraindication of topical ophthalmic beta blockers is in individuals with asthma, COPD and those who exhibit airway hyperreactivity or hyperresponsiveness.¹⁻³ In the emergent treatment of airway hyperreactivity and respiratory distress, short-acting beta receptor agonists are often used in combination with other classes of treatment, including corticosteroids; conversely, a blockade of beta receptors, specifically the beta 2 receptor, may precipitate bronchospasm.^{1,2}

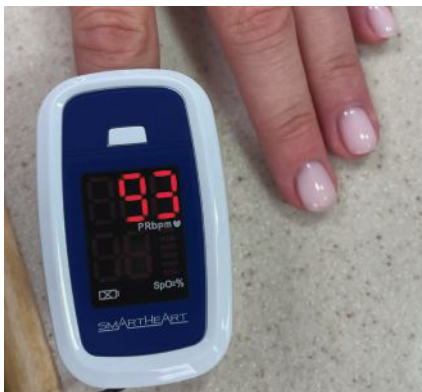A comparison of the effect on one-second forced expiratory volume (FEV1) of topical ophthalmic timolol and placebo demonstrated a drop in FEV1 in 13 out of 15 asthmatics, with more than 25% demonstrating a clinically significant (>20%) reduction in FEV1, while FEV1 has been described to not be impacted in healthy individuals who receive topical ophthalmic timolol.^{4,5}

Despite the unpredictability of the pulmonary response to beta-1 selective agents, considering their incomplete antagonistic effect on beta-2 receptors, they may still lead to bronchospasm and therefore should be avoided in patients with airway hyperreactivity.^{1,2} Importantly, infectious bronchitis and viral upper respiratory infections do not exhibit airway hyperreactivity; therefore, topical ophthalmic beta blockers are appropriate to continue during active events.¹

Cardiac Impact

Beta blockers slow conduction through the atrioventricular (AV) node and can slow sinus nodal discharge, which provides systemic therapeutic utility but can also lead to bradycardia: a pulse rate of less than 60bpm.^{1,5,6} In patients who develop symptomatic bradycardia or syncope following initiation of systemic or topical ophthalmic beta blocker, it is generally thought that the beta blocker unmasks or exacerbates an underlying cardiac rhythm anomaly or electrical disturbance rather than it being solely responsible for the condition.¹ For patients with a history of syncope, pre-syncope, asymptomatic bradycardia or second or higher degree AV block, topical ophthalmic beta blockers are contraindicated.^{1,2}

A recent retrospective analysis of 138 patients with glaucoma was determined



Pulse rate can be measured using a pulse oximeter, smartwatch, smartphone app or manually in-office.

About
Dr. Steen


Dr. Steen is an associate professor at Nova Southeastern University College of Optometry, where she serves as director of the Glaucoma Service, coordinator of the Primary Care with Emphasis in Ocular Disease Residency and teaches courses in glaucoma and ocular pharmacology. Her financial disclosures include Bausch + Lomb, Santen, Ocuphire, Carl Zeiss Meditec, Oyster Point Pharma, Ocuterra, Peripherex, Clearside Biomedical, Allergan, Iveric Bio, Alcon and Thea Pharma.

to demonstrate an average 7.61bpm reduction in pulse rate following initiation of topical ophthalmic beta blocker in at least one eye. Those with the greatest reduction in pulse rate had a higher baseline pulse rate (86.1bpm) and were more likely to be female.⁷

The safety and efficacy of adding a topical ophthalmic beta blocker to an individual already taking a systemic beta blocker is also pertinent to highlight. Systemic beta blockers—specifically those agents that are highly lipophilic such as propranolol or timolol—have the greatest propensity of penetrating the blood-brain and blood-ocular barrier and therefore the greatest potential for IOP lowering effect in comparison with those that are moderately lipophilic or those with low lipophilicity such as atenolol.⁸ Detectable systemic plasma levels occur quickly following ophthalmic instillation of timolol, occurring in 10 to 15 minutes vs. one to two hours following oral ingestion, with similar systemic bioavailability to intravenously administered timolol.^{5,9}

Keep in mind that, in older individuals, plasma concentrations of topically applied timolol are higher than for younger individuals due to a reduced rate of drug elimination and potential differences in conjunctival and eyelid anatomy, which may also impact systemic absorption.^{5,9} To reduce systemic absorption, nasolacrimal occlusion and eyelid closure for five minutes following instillation of a topical ophthalmic agent have been demonstrated to be effective while also increasing topical bioavailability.¹⁰

In a group of glaucoma patients, the pulse rate was determined to be statistically lower in those taking an oral beta blocker (64.7bpm) or topical ophthalmic beta blocker (70.3bpm) in comparison to those who were not using a beta blocker (76bpm).⁶ Individuals who were taking both a topical ophthalmic and oral beta blocker had the lowest mean resting pulse rate (58bpm) of all groups, and individuals in the study who were found to have a pulse rate of less than 50bpm were more likely to be



Smartphone apps, including Instant Heart Rate (Bodymatter), detect and measure heart rate when the index finger is placed over the smartphone camera.

taking both a topical ophthalmic and systemic beta blocker.⁶

Bottom Line

While topical ophthalmic beta blockers are generally safe and efficacious therapies, a complete medical history should be gathered prior to their prescription. It is pertinent that this history highlight the pulmonary and cardiovascular systems to rule out underlying asthma, COPD or other airway hyperreactivity, as well as highlight history of fainting or dizziness without defined cause, unstable congestive heart failure, symptomatic heart block or symptomatic bradycardia.

Heart rate measured in-office also provides valuable information to detect asymptomatic, undiagnosed bradycardia (<60bpm), which may become symptomatic if a topical ophthalmic beta blocker is added. If asymptomatic bradycardia is determined, refer to the patient's managing provider and, ideally, to a cardiologist for evaluation. In these cases, avoid prescribing a topical ophthalmic beta blocker.

In patients whose topical ophthalmic beta blocker efficacy profile is determined to outweigh potential risk and

therefore prescribed, due to the potential reduction in pulse rate, conduct an additional assessment of pulse rate at the first follow-up visit after beginning treatment to evaluate the potential systemic response and safety of continued treatment.

The 80-year-old patient with a pulse rate of 48bpm reported no weakness, dizziness, fatigue, shortness of breath or lightheadedness. A review of his medical record identified that previous blood pressure and pulse measurement taken one year prior while taking latanoprost 0.005% QHS and timolol 0.5% BID OU were 134/80mm Hg and 66bpm and at the time of initiation of timolol 0.5%. In 2021, his pulse rate was 70bpm.

Considering the determined asymptomatic bradycardia, his cardiologist was contacted, who arranged for an evaluation and electrocardiography. While the topical ophthalmic beta blocker did not appear to be related to his bradycardia, it was discontinued and replaced with brimonidine 0.2% to minimize the potential impact on pulse rate pending cardiology evaluation. ■

1. Lama PJ. Systemic adverse effects of beta-adrenergic blockers: an evidence-based assessment. *Am J Ophthalmol.* 2002;13(5):4749-60.
2. Vander Zanden JA, Valuck RJ, Bunce CL, et al. Systemic adverse effects of ophthalmic beta-blockers. *Ann Pharmacother.* 2001;35(12):1633-7.
3. Fahy JV, O'Byrne PM. "Reactive airways disease". A lazy term of uncertain meaning that should be abandoned. *Am J Respir Crit Care Med.* 2001;163(4):822-3.
4. Hugues FC, Le Jeunne C, Munera Y, et al. Evaluation of systemic effects of timolol maleate in eye drops. *J Francais d'Ophthalmologie.* 1985;8(5):389-94.
5. Korte JM, Kaila T, Saari KM. Systemic bioavailability and cardiopulmonary effects of 0.5% timolol eyedrops. *Graefes Arch Clin Exp Ophthalmol.* 2002;240(6):430-5.
6. Tattersall C, Vernon C, Singh R. Resting pulse rates in a glaucoma clinic: the effect of topical and systemic beta-blocker usage. *Eye (Lond).* 2006;20(2):221-5.
7. Kiyota N, Shiga Y, Ninomiya T, et al. The effect of β -blocker eye drops on pulse rate, ocular blood flow and glaucoma progression: a retrospective longitudinal study. *Adv Ther.* 2024;41(2):730-43.
8. Poirier L, Tobe SW. Contemporary use of β -blockers: clinical relevance of subclassification. *Can J Cardiol.* 2014;30(5 Suppl):S9-15.
9. Vuori ML, Kaila T. Plasma kinetics and antagonist activity of topical ocular timolol in elderly patients. *Arch Clin Exp Ophthalmol.* 1995;233(3):131-4.
10. Zimmerman TJ, Koerner KS, Kandarakis AS, et al. Improving the therapeutic index of topically applied ocular drugs. *Arch Ophthalmol.* 1984;102(4):551-3.



A Close-up on Corneal Transplant Surgeries

In this first installment of a series, we look carefully at the original procedure—PK—with a focus on post-op management.

BY JOSHUA BLACK, OD
VIRGINIA BEACH, VA

Historically, a dysfunctional cornea had been surgically managed with a single approach: full-thickness penetrating keratoplasty (PK). First performed in 1905, this corneal transplantation procedure is still frequently used today. It is the most successful solid organ transplantation in the body due to corneal avascularity and immune privilege.¹ The 2023 Eye Bank Association of American report distributed tissue for 50,925 keratoplasties, 14,486 of which were used for PK.²

The goal of the procedure is to replace opacified or distorted tissue with clear donor tissue. This can be helpful to establish a clear visual axis, alleviate painful conditions and sometimes help treat infections. The procedure is indicated for corneal conditions that affect multiple layers of the cornea and is relatively contraindicated in patients with ocular surface disease, as this is a leading cause of transplant failure.¹

Candidate selection, preoperative preparation and postoperative management are important considerations to maximize chances of success. Preoperative patient education should mention that it often takes 12 months to achieve maximal visual rehabilitation; however,

For a video of the procedure, read this article online at www.reviewofoptometry.com.

there will likely be refractive error remaining. Postoperative patient education is just as important, which we will discuss in extensive detail below.

Performing the Procedure

A circular cutting device known as a trephine is used to precisely cut a round corneal button of donor tissue. A similar size cut is made to the host cornea. After the host corneal button is removed, the donor button is placed and sutured into place. The nylon sutures are tied and buried on the donor side, as far from the limbus as possible. The surgeon will take care to evenly distribute suture tension, as tight sutures can lead to a flat corneal surface and resultant severe astigmatism. There are several suturing techniques used, including interrupted sutures only, running suture only, combined interrupted and running, and double running. However, there is no proven superior technique.

Post-op

Close observation is a necessity. At post-op day one, the patch and eye shield are to be removed so that topical medications can be applied. Prophylactic topical antibiotics and steroids are prescribed four times daily with a slow taper on steroids over the next few months. Topical nonsteroidal anti-inflammatories may be used in combined cataract and PK surgeries. At this initial visit, the physician must check carefully

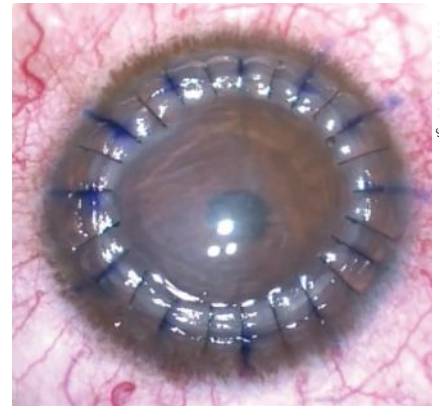


Photo: Albert Cheung, MD

Post-op following PK is crucial, especially the first three months, to monitor for possible complications such as broken sutures or signs of graft rejections.

for wound leakage, treat ocular surface disease and/or epithelial defects, manage intraocular pressure complications and address pain symptoms.

Postoperative patient education is key. Light activity, avoidance of eye rubbing and wearing nighttime shield for the first week is imperative. Protective eyewear should always be worn during sporting or other activities that risk ocular trauma, and religious use of anti-rejection drops is mandatory. Patients must know the signs and symptoms of loose sutures, infection and graft rejection, which require prompt intervention to have a chance at preserving the graft.

While long-term management is extremely important, close observation over the first three months is required to monitor for any of a host of complications that can arise, especially signs of graft rejection. An episode of decreased vision, redness and light sensitivity lasting more than a few hours should raise suspicion for graft rejection. Corneal edema within the graft, anterior chamber cells/flare and circumferential injection may be the earliest presenting signs of rejection. Epithelial rejection lines, subepithelial infiltrates, stromal

About Drs. Cunningham and Whitley

Dr. Cunningham is the director of optometry at Dell Laser Consultants in Austin. He has no financial interests to disclose. **Dr. Whitley** is the director of professional relations and residency program supervisor at Virginia Eye Consultants in Norfolk, VA. He is a consultant for Alcon.

haze, keratic precipitates and endothelial rejection lines may also occur.

Risk factors for rejection include previous graft failure, large grafts, young age, preoperative glaucoma, corneal neovascularization, anterior synechiae, ocular surface disease and previous herpetic infection.³ Signs of rejection are treated aggressively with topical steroids and cyclosporines; however, exercise caution in patients with a history of herpes simplex keratouveitis. Prompt referral back to the surgeon should be made as subconjunctival injections or oral steroids may be used and graft rejection can be reversed with prompt and aggressive therapy. Thankfully, PK is largely successful with approximately 95% of grafts clear at five years for low-risk eyes.⁴ Even without signs of rejection, patients are usually kept on one drop of topical steroids daily for life.

Many of these patients will achieve maximum visual rehabilitation only with the use of specialty contact lenses. The fitting process can start as soon as three to four months postoperatively, as long as the graft is healthy and the surgeon agrees. However, it can take much longer to fully stabilize, and suture adjustments can complicate the fitting process.

As comanaging optometrists, we are the providers concerned with long-term postoperative management. Thus, we must always remain vigilant for complications such as broken sutures or signs of graft rejection which often occurs years after the procedure. ■

1. Mannis MJ, Holland EJ. Cornea. 5th ed. Elsevier; 2021.
2. Eye Bank Association of America. Statistical Report. restoresight.org/members/publications/statistical-report. Accessed May 22, 2024.
3. Panda A, Vanathi M, Kumar A, et al. Corneal graft rejection. *Surv Ophthalmol*. 2006;52(4):375-96.
4. Thompson RW, Price MO, Bowers PJ, et al. Long-term graft survival after penetrating keratoplasty. *Ophthalmology*. 2003;110(7):1396-402.

ABOUT THE AUTHOR



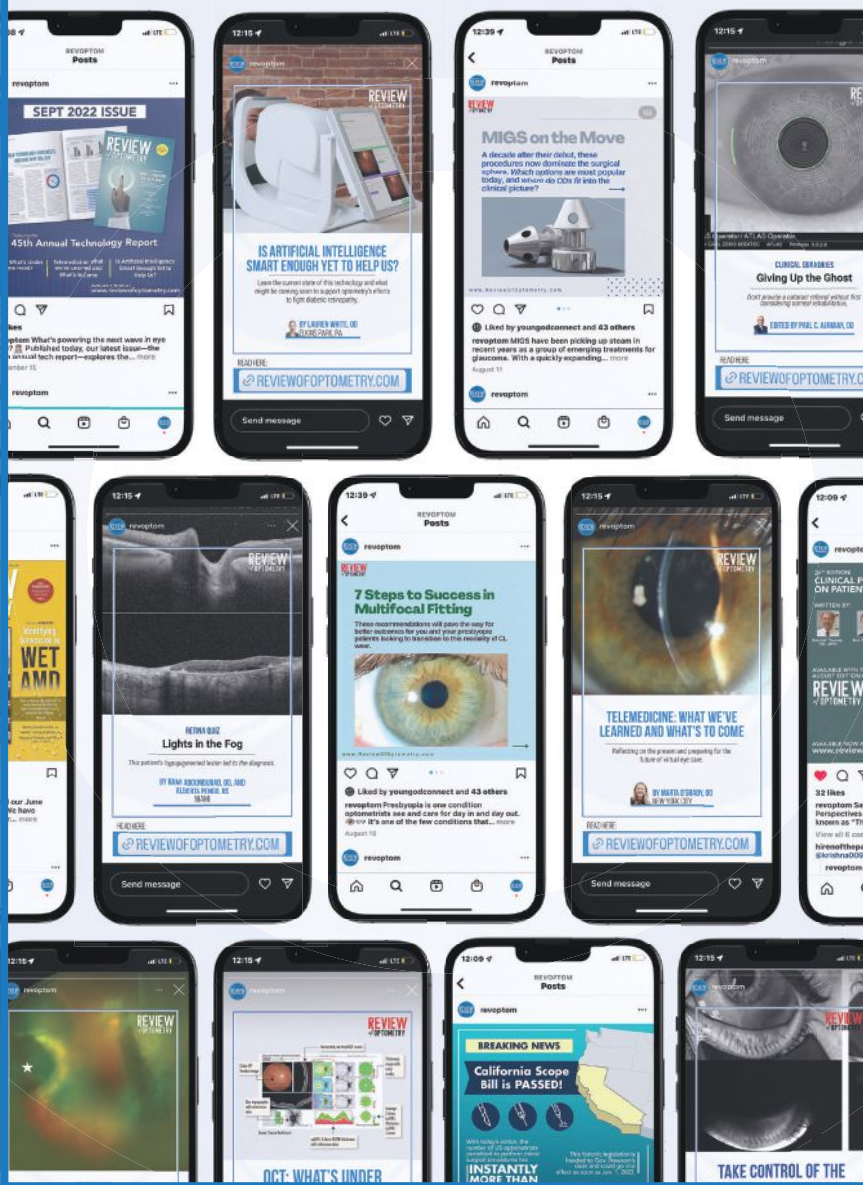
Dr. Black graduated from Nova Southeastern College of Optometry and completed residency in ocular disease at Bascom Palmer Eye Institute. He practices at Virginia Eye Consultants in Virginia Beach. He has no financial disclosures.

A NEW WAY TO EXPERIENCE

REVIEW OF OPTOMETRY

Follow us on Instagram for striking clinical images, news headlines, issue previews and great content from the magazine—all formatted for mobile.

 @REVOPTOM



PRODUCT REVIEW



ONLINE FIRST:
GET THE LATEST
PRODUCT NEWS AT
www.reviewofoptometry.com

New items to improve clinical care and strengthen your practice.

► DIAGNOSTIC EQUIPMENT

Handheld AI Fundus Camera Detects DR in 60 Seconds

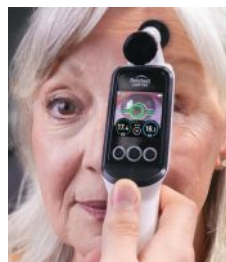Artificial intelligence has emerged as a promising solution to increase the accessibility of diabetic retinopathy (DR) screening. Though a few AI-powered products are already on the market, a new one has just emerged: last month, the FDA approved the first handheld AI fundus camera, called Aurora AEye. The device can provide instant DR detection with a single image of each eye and, thanks to its automation and portability, enables screening in primary care settings, notes the product's developer, Optomed.



In clinical trials, the non-mydratric handheld camera exhibited diagnostic sensitivity between 92% and 93% and specificity between 89% and 94%. The system is designed to detect small, early-phase retinal changes with a 50° field of view, Optomed says. The camera also uses autofocus and auto-exposure functions and allows digital images to be sent to eyecare providers.

The screening results displayed on the system are colored either red or green, with red indicating the need to refer the patient to an eyecare specialist and green suggesting the patient can be seen again in 12 months.

Handheld Device Keeps IOP Measurement on Target



More ODs are switching from applanation to rebound tonometry to measure patients' intraocular pressure due to its advantages of portability, ease of use and the eliminated need for topical anesthesia. Reichert recently added one such device to its product offerings in the US. The Tono-Vera, as it's called, is an automated tonometer using rebound

technology and several design features to optimize patient comfort and reading accuracy, the company says.

A screen on the back of the device, visible to the doctor or tech during the test, provides a view of the eye plus an overlay of target markings to guide the operator to the needed centration, angle and distance. An onscreen ring should be maneuvered to the center of the target; when the ring is aligned and turns green, you've located the corneal apex and proper distance. Canthus markings help determine the correct tilt. The device will then automatically measure the IOP and produce a result in as few as three readings, which takes less than a second, the company says.

The tonometer weighs in at 4.2oz and features a soft forehead rest for stabilization and distance control. Clinicians can choose

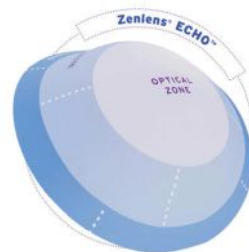
between two device models—rechargeable and AA battery—both of which offer Bluetooth connectivity.

► SCLERAL LENSES

B+L Launches New Scleral Lens for Advanced Corneal Conditions

While scleral lenses are highly customizable, patients with advanced corneal conditions may require more intricate specifications. For cases like these, Bausch + Lomb recently introduced a non-prosthetic custom scleral lens, called the Zenlens Echo, that offers additional parameter customization compared with the company's existing Zenlens.

Along with the lens fitting set, Zenlens Echo lenses require OCT scanning, a slit lamp and profilometry, B+L points out in its press release. For each lens, clinicians can specify the base curve, sagittal height, limbal clearances and landing zone, as well as spherical and front toric optics and mid-peripheral and limbal clearance zones.



In the press release from B+L, the company wrote that the Zenlens Echo is designed to fit patients with the following advanced conditions: corneal degeneration, including Terrien's marginal degeneration, advanced pellucid marginal degeneration, Salzmann's nodules and keratoconus; postoperative conditions, such as tilted graft (penetrating keratoplasty), post-refractive ectasia and radial keratotomy; and trauma, including chemical burns or conjunctival abnormalities.

► BLEPHARITIS

Three-ingredient Eyelid Wipe for Blepharitis Debuts

Often the first recommendation given to patients with blepharitis is regular eyelid cleansing to help remove debris, bacteria and oils that can worsen symptoms. For those with more sensitive lids, or patients looking for a solution derived from natural sources, there's a new lid wipe on the market called NeutraWipe Eco, made with Manuka honey, which is said to have antibacterial and anti-inflammatory properties. The only other active ingredient is hydrolyzed soy protein, which is used in some cosmetic products for its purported antimicrobial and moisturizing effects on skin. These ingredients plus purified water are infused into a biodegradable wipe made from bamboo.

The developer, TearRestore, says the product is intended to help soothe and moisturize eyelids, which in turn may help reduce redness and inflammation, according to a press release. Its website notes that the wipes can be used one to two times per day for blepharitis (including *Demodex*), as well as for makeup removal and false eyelid cleansing. ■

Use discount
code **SUMMER**
for **20% OFF**
registration!

OCULAR SURFACE SYMPOSIUM

SEPTEMBER 8, 2024

RENAISSANCE CHICAGO DOWNTOWN HOTEL | CHICAGO, ILLINOIS

IN-PERSON 

OVERVIEW

This comprehensive one-day event is designed to provide optometrists with a deep dive into ocular surface disease with an emphasis on dry eye, MGD, and blepharitis.

Experts will share the latest data, research, and current treatment strategies. Numerous clinical cases will be shown to demonstrate critical advances in diagnostic and therapeutic options for ocular surface disease, MGD, and blepharitis.

CONFERENCE CHAIR




Paul Karpecki, OD, FAAO

Director of Cornea and External Disease
Kentucky Eye Institute
Lexington, Kentucky
Associate Professor
University of Pikeville Kentucky
College of Optometry
Pikeville, Kentucky
Director, Cornea and External Disease
Center for Sight
Carmel, Indiana

wine AND WORKSHOPS

During the Wine and Workshops session, you'll be able to enjoy a glass of your favorite wine while you check out and demo a wide array of devices and instruments that are essential to any dry eye practice.



To register, scan the QR code, or visit:

www.reviewedu.com/oss



Postgraduate Institute
for Medicine



*Accreditation pending

REVIEW
Education GROUP



A Clouded View of Post-op Recovery

A patient with a complex posterior segment history presents with new anterior segment findings. What's happening and why?

A 70-year-old African-American female presented to the office with complaints of progressively reduced vision OS>OD of six months' duration. She had an ocular history of proliferative diabetic retinopathy (PDR) with macular edema OU. She had been treated with pan-retinal photocoagulation (PRP) OU five years prior. She also underwent three intravitreal injections of bevacizumab (Avastin, Genentech) over the course of five years.

The patient explained that she had developed a vitreous hemorrhage and

tractional retinal detachment in her right eye and underwent pars plana vitrectomy with retinal detachment repair using a silicone oil tamponade one year ago. The silicone oil was removed after six months and an oil-gas exchange was performed with sulfurhexafluoride-6 (SF₆) gas. Her vision has progressively worsened since that operation.

Her systemic history was remarkable for controlled hypertension and type 2 diabetes. She had no medical or environmental allergies. Both her family and social history were noncontributory.

The patient's best-corrected entering visual acuity was hand motion OD and 20/40 OS through a mild myopic spectacle prescription. Her vision did not improve with pinhole testing OU. Her

external testing was unremarkable and there was no afferent pupillary defect. Refraction did not improve acuity.

Slit lamp biomicroscopy was remarkable for a grade 3 nuclear cataract OD and a grade 2 nuclear cataract OS. There was no iris neovascularization. Her intraocular pressures (IOP) measured 14mm Hg OD and 15mm Hg OS with Goldmann applanation.

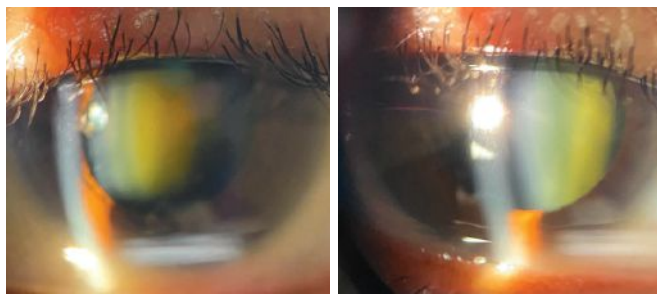Dilated fundus examination revealed very hazy views OD with old vitreoproliferative scarring OU. The OS demonstrated clear media with scattered moderate nonproliferative diabetic retinopathy (NPDR) and no new evidence of PDR. Her optic nerves were flat and perfused, with a cup-to-disc ratio of 0.4/0.4 OU. PRP scars were seen 360° OU. She was referred for cataract extraction, OD>OS.

Additional Testing

Laser interferometry was done to understand the patient's macular potential. OCT of the macula was also completed to rule out the need for intervention regarding diabetic macular edema. Color fundus photographs were taken to record the status of both posterior poles.

Your Diagnosis

What would be your diagnosis in this case based on the presentation? What is the likely prognosis? To find out, read the online version of this article at www.reviewofoptometry.com. ■



Slit lamp biomicroscopy findings of the patient's right and left eyes. Why might this presentation appear in a patient with the medical history described here?

About Dr. Gurwood

Dr. Gurwood is a professor of clinical sciences at The Eye Institute of the Pennsylvania College of Optometry at Salus University. He is a co-chief of Primary Care Suite 3. He is attending medical staff in the department of ophthalmology at Albert Einstein Medical Center, Philadelphia. He has no financial interests to disclose.

NEXT MONTH IN THE MAG

In July, we present our 30th Annual Glaucoma Report. Articles will include:

- Glaucoma: Break Down the Psychological and Logistical Barriers to Success
- Questions and Controversies in Glaucoma Care

- Get Glaucoma Therapy Off to a Good Start: Learn the Nuances of Medication Regimens
- Things to Watch Out For in the Post-MIGS Patient

Also in this issue:

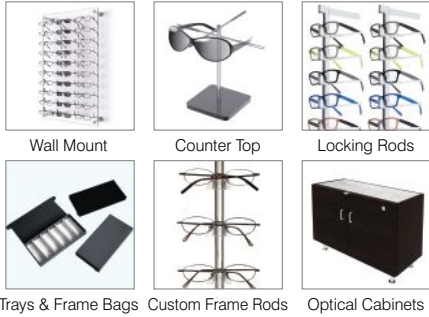
- Update Your Approach to Amblyopia Diagnosis and Management (earn 2 CE credits)

Merchandise Offered

FRAME DISPLAYS & OPTICAL INTERIORS



Optical Displays • Furniture • Design
Professional US Based Customer Service



Trays & Frame Bags Custom Frame Rods Optical Cabinets



Trusted by more than 40,000 eye care professionals worldwide.



1-877-274-9300 • www.framedisplays.com

FREE SHIPPING \$100+ Orders*

*) Excludes Freight Shipments

Code: **FREESHIPROP**



Complimentary
Zoom Design
Session



0% Financing
& Interest for
36 Months*

Practice For Sale

Optometric practice in Del Norte Ca is selling a very potentially profitable practice.

There are no other optometry, ophthalmology or optical offices in the city or county. The office is 5 blocks from an amazing coastline with beautiful forest, beaches and rivers. 1250 sf office with a wonderful staff.

Any reasonable offer will be seriously appreciated.

If interested, please contact sinouye7@gmail.com

Do you have CE Programs?

CONTACT US TODAY FOR CLASSIFIED ADVERTISING

Toll free: **888-498-1460**

E-mail: sales@kerhgroup.com

Practice Sales • Appraisals • Consulting
www.PracticeConsultants.com

PRACTICES FOR SALE NATIONWIDE

Visit us on the Web or call us to learn more about our company and the practices we have available.
info@PracticeConsultants.com
925-820-6758

www.PracticeConsultants.com

Targeting Optometrists?

CLASSIFIED ADVERTISING WORKS

- JOB OPENINGS
- CME PROGRAMS
- PRODUCTS & SERVICES
- AND MORE...

Contact us today for classified advertising:
Toll free: 888-498-1460
E-mail: sales@kerhgroup.com

Contact us today for classified advertising:
Toll free: **888-498-1460**
E-mail: sales@kerhgroup.com

REVIEW
of OPTOMETRY

ADVERTISER INDEX

This index is published as a convenience and not as part of the advertising contract. Every care will be taken to index correctly. No allowance will be made for errors due to spelling, incorrect page number, or failure to insert.

Amgen	41
www.tepezza.com	
Apellis	53
www.apellis.com	
Apellis/Zeiss	Insert
www.apellis.com	
www.zeiss.com/meditec	
Astellas	62-64
www.astellas.com	
Bausch + Lomb	Cover 2, 3
866-246-8245	
https://www.miebo-ecp.com/	
Bausch + Lomb	Cover Tip
866-246-8245	
https://www.lumifydrops.com/	
Bausch + Lomb	23
866-246-8245	
www.justblink.com	
Bausch + Lomb	Cover 3
866-246-8245	
https://infusetoric.com/	
Bausch + Lomb	Polybag Insert
866-246-8245	
CooperVision	39
800-341-2020	
https://coopervision.com/	
Dompe	7, 8
www.exervate.com/HCP	
Essilor	5
(800) 347-4500	
leonardo.essilorluxottica.com	
Icare USA	19
(888) 422-7313	
infoUSA@icare-world.com	
www.icare-world.com/USA	
LKC	57
301 840 1992	
www.lkc.com/	
NextGen Healthcare	21
www.nextgen.com/1-ophth	
Notal Vision	15
1-855-600-3112	
https://notalvision.com/	
Oyster Point	48, 49
https://oysterpointrx.com/	
Reichert Technologies	28, 29
(888) 849-8955	
www.reichert.com	
Tarsus	98, Cover 4
https://tarsusrx.com	
Thea Pharma	25, 26
781-832-3664	
https://hyzeih.com/	
Thea Pharma	31
781-832-3664	
https://www.ivizia.com/	
Topcon	55
201-599-5100	
www.topconhealthcare.com	
Viatriis	11, 12
https://www.viatriis.com/en	
X-Gel Specialty	45
800-241-9312	
www.xcelspecialtycontacts.com/	
Zeavision	17
eyepromise.com	

XDEMYV® (lotilaner ophthalmic solution) 0.25%, for topical ophthalmic use

BRIEF SUMMARY OF PRESCRIBING INFORMATION Please see the XDEMYV® package insert for full Prescribing Information.

INDICATIONS AND USAGE

XDEMYV is indicated for the treatment of *Demodex* blepharitis.

CONTRAINDICATIONS

None.

WARNINGS AND PRECAUTIONS

Risk of Contamination Do not allow the tip of the dispensing container to contact the eye, surrounding structures, fingers, or any other surface in order to minimize contamination of the solution. Serious damage to the eye and subsequent loss of vision may result from using contaminated solutions.

Use with Contact Lenses Contact lenses should be removed prior to instillation of XDEMYV and may be reinserted 15 minutes following its administration.

ADVERSE REACTIONS

Because clinical studies are conducted under widely varying conditions, adverse reaction rates observed in the clinical trials of a drug cannot be directly compared to rates in the clinical trials of another drug and may not reflect the rates observed in practice.

XDEMYV was evaluated in 833 patients with *Demodex* blepharitis in two randomized, double-masked, vehicle-controlled studies (Saturn-1 and Saturn-2) with 42 days of treatment. The most common ocular adverse reaction observed in controlled clinical studies with XDEMYV was instillation site stinging and burning which was reported in 10% of patients. Other ocular adverse reactions reported in less than 2% of patients were chalazion/hordeolum and punctate keratitis.

USE IN SPECIFIC POPULATIONS

Pregnancy: Risk Summary There are no available data on XDEMYV use in pregnant women to inform any drug associated risk; however, systemic exposure to lotilaner from ocular administration is low. In animal reproduction studies, lotilaner did not produce malformations at clinically relevant doses.

Data Animal Data In an oral embryofetal developmental study in pregnant rats dosed during organogenesis from gestation days 6-19, increased post-implantation loss, reduced fetal pup weight, and incomplete skeletal ossification were observed at 50 mg/kg/day (approximately 1390 times the recommended human ophthalmic dose (RHOD) on a body surface area basis) in the presence of maternal toxicity (i.e., decreased body weight and food consumption). A rare malformation of situs inversus of the thoracic and abdominal viscera occurred in 1 fetus from a pregnant rat receiving 50 mg/kg/day; whether this finding was treatment-related could not be excluded. No maternal or embryofetal toxicity was observed at 18 mg/kg/day (approximately 501 times the RHOD on a body surface area basis). In an oral embryofetal development study in pregnant rabbits dosed during organogenesis from gestation days 7-19, no embryofetal toxicity or teratogenic findings were observed at 20 mg/kg/day (approximately 580-times the RHOD on an AUC basis), even in the presence of maternal toxicity (i.e., decreased food consumption and body weight).

In an oral two-generation reproductive toxicity study, F0 male and female rats were administered lotilaner at doses up to 40 mg/kg/day for 10 weeks before pairing and during the 2-week pairing period (3 weeks for males). Dosing for F0 females continued through lactation day 22. F1 male and female rats were administered lotilaner at 1 and 5 mg/kg/day post-weaning from day 23 for 10 weeks before pairing and during the 2-week pairing period (3 weeks for males). Dosing for F1 parental females continued through lactation day 22.

There were no clear adverse effects on the F1 generation, and a slightly lower mean body weight during lactation was noted for F2 pups at 5 mg/kg/day. The no observed adverse effect level (NOAEL) was determined to be 5 mg/kg/day

(approximately 139 times the RHOD on a body surface area basis).

Lactation: Risk Summary There are no data on the presence of XDEMYV in human milk, the effects on the breastfed infant, or the effects on milk production. However, systemic exposure to lotilaner following 6 weeks of topical ocular administration is low and is >99% plasma protein bound, thus it is not known whether measurable levels of lotilaner would be present in maternal milk following topical ocular administration. The developmental and health benefits of breastfeeding should be considered along with the mother's clinical need for XDEMYV and any potential adverse effects on the breast-fed child from XDEMYV.

Pediatric Use: Safety and effectiveness in pediatric patients below the age of 18 years have not been established.

Geriatric Use: No overall differences in safety or effectiveness have been observed between elderly and other adult patients.

NONCLINICAL TOXICOLOGY

Carcinogenesis, Mutagenesis, Impairment of Fertility

Carcinogenesis Long-term studies in animals have not been performed to evaluate the carcinogenic potential of lotilaner.

Mutagenesis Lotilaner was not genotoxic in the following assays: Ames assay for bacterial gene mutation, *in vitro* chromosomal aberration assay in cultured human peripheral blood lymphocytes, and *in vivo* rat micronucleus test.

Impairment of fertility In a two-generation study of reproductive performance in rats, F0 male and female rats were administered lotilaner at oral doses of 40 mg/kg/day for 80 days reduced to 20 mg/kg/day for 47-50 supplementary days. Reduced pregnancy rates and decreased implantation rates were observed in F0 females at doses 20 mg/kg/day (approximately 556 times the RHOD on a body surface area basis), which were also associated with maternal toxicity (i.e., decreased body weight and food consumption). No effects on fertility were observed in F0 females at the dose of 5 mg/kg/day (approximately 139 times the MRHOD on a body surface area basis). No effects on fertility were observed in F0 males at the oral dose of 20 mg/kg/day (approximately 556 times the RHOD on a body surface area basis), and no effects on fertility were observed in F1 males and females at the oral dose of 5 mg/kg/day (approximately 139 times the RHOD on a body surface area basis).

PATIENT COUNSELING INFORMATION

Handling the Container Instruct patients to avoid allowing the tip of the dispensing container to contact the eye, surrounding structures, fingers, or any other surface in order to minimize contamination of the solution. Serious damage to the eye and subsequent loss of vision may result from using contaminated solutions.

When to Seek Physician Advice

Advise patients that if they develop an intercurrent ocular condition (e.g., trauma or infection), have ocular surgery, or develop any ocular reactions, particularly conjunctivitis and eyelid reactions, they should immediately seek their physician's advice concerning the continued use of XDEMYV.

Use with Contact Lenses Advise patients that XDEMYV contains potassium sorbate, which may discolor soft contact lenses. Contact lenses should be removed prior to instillation of XDEMYV and may be reinserted 15 minutes following its administration.

Use with Other Ophthalmic Drugs Advise patients that if more than one topical ophthalmic drug is being used, the drugs should be administered at least 5 minutes between applications.

Missed Dose Advise patients that if one dose is missed, treatment should continue with the next dose.

RX only

© 2024 Tarsus Pharmaceuticals, Inc. All rights reserved.

XDEMYV is a trademark of Tarsus Pharmaceuticals, Inc.

US--2300345 1/24

BAUSCH+LOMB

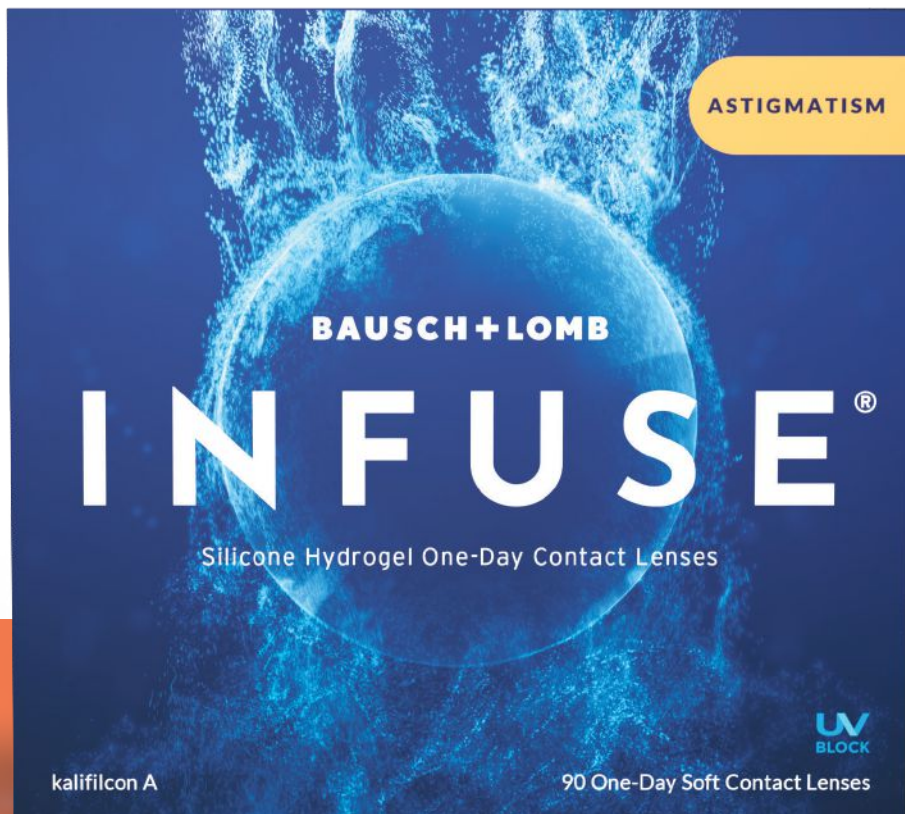
PUSH THE LIMITS OF STABILITY, CLARITY, & COMFORT

NEW toric innovation coming July 2024

SEE MORE



INFUSEtoric.com



xdemvy[®]
(lotilaner ophthalmic
solution) 0.25%



Learn more at
XDEMVIHCP.com

XDEMVI gives you
might over mites
to eradicate *Demodex* blepharitis.^{1,2}

Lotilaner, the active ingredient in XDEMVI^{1,3,4}:



Is a lipophilic agent in an aqueous drop that...



Acts specifically via mite GABA-gated
chloride channels to...



Target, paralyze, and kill *Demodex* mites

GABA=gamma-aminobutyric acid.

INDICATIONS AND USAGE

XDEMVI (lotilaner ophthalmic solution) 0.25% is indicated for the treatment of *Demodex* blepharitis.

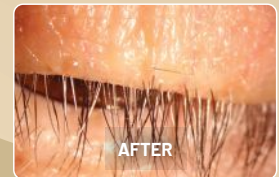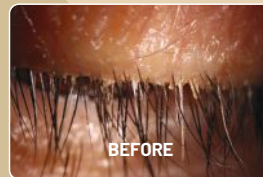IMPORTANT SAFETY INFORMATION:

WARNINGS AND PRECAUTIONS

Risk of Contamination: Do not allow the tip of the dispensing container to contact the eye, surrounding structures, fingers, or any other surface in order to minimize contamination of the solution. Serious damage to the eye and subsequent loss of vision may result from using contaminated solutions.

Use with Contact Lenses: XDEMVI contains potassium sorbate, which may discolor soft contact lenses. Contact lenses should be removed prior to instillation of XDEMVI and may be reinserted 15 minutes following its administration.

Real results



44% and 55% of patients taking XDEMVI in SATURN-1 (N=209) and SATURN-2 (N=193), respectively, achieved a significant improvement in their eyelids (reduction of collarettes to no more than 2 collarettes per upper lid) at Day 43 vs 7% (N=204) and 12% (N=200) of patients taking vehicle ($P<0.01$ in each trial).^{1*}

All images are of actual patients who participated in clinical trials for Tarsus Pharmaceuticals.

ADVERSE REACTIONS: The most common adverse reaction with XDEMVI was instillation site stinging and burning which was reported in 10% of patients. Other ocular adverse reactions reported in less than 2% of patients were chalazion/hordeolum and punctate keratitis.

Please see next page for a Brief Summary of the full Prescribing Information.

References: 1. XDEMVI [prescribing information]. Tarsus Pharmaceuticals, Inc; 2023. 2. Gao YY et al. *Invest Ophthalmol Vis Sci.* 2005;46(9):3089-3094. 3. Yeu E et al. *Cornea.* 2022;42:435-443. 4. Toutain CE et al. *Parasit Vectors.* 2017;10(1):522.

*The safety and efficacy of XDEMVI for the treatment of DB were evaluated in a total of 833 patients (415 of whom received XDEMVI) in two 6-week, randomized, multicenter, double-masked, vehicle-controlled studies (SATURN-1 and SATURN-2). Patients were randomized to either XDEMVI or vehicle at a 1:1 ratio, dosed twice daily in each eye for 6 weeks. All patients enrolled were diagnosed with DB. The primary efficacy endpoint was defined as the proportion of patients with collarette reduction to no more than 2 collarettes per upper eyelid at Day 43.

© 2024 Tarsus Pharmaceuticals, Inc. All rights reserved.
Tarsus, XDEMVI, and the associated logos are trademarks of
Tarsus Pharmaceuticals, Inc. US--2300617 1/24

